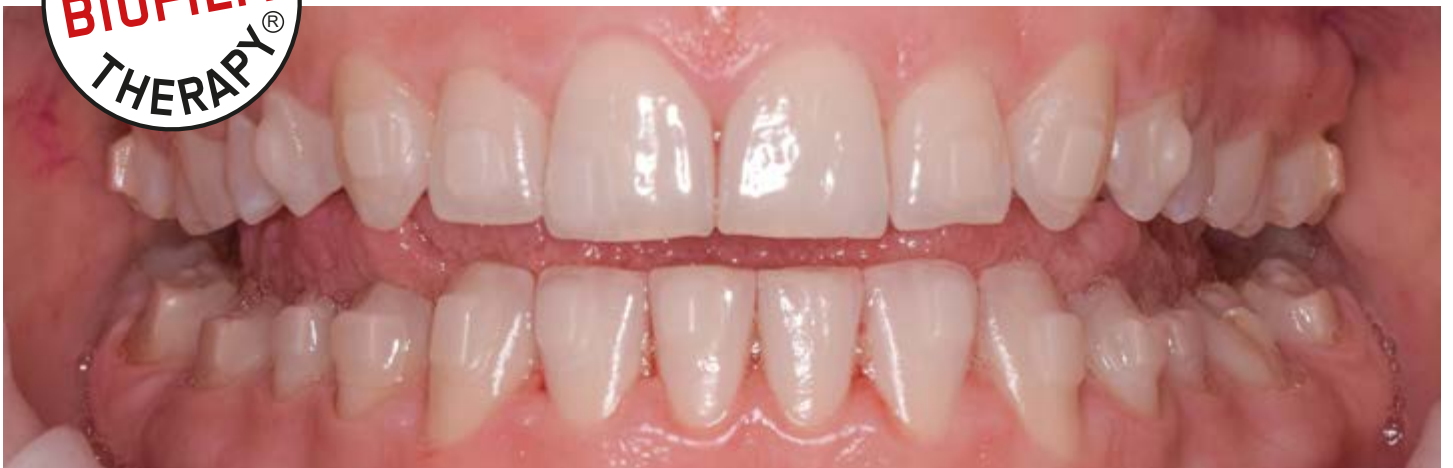
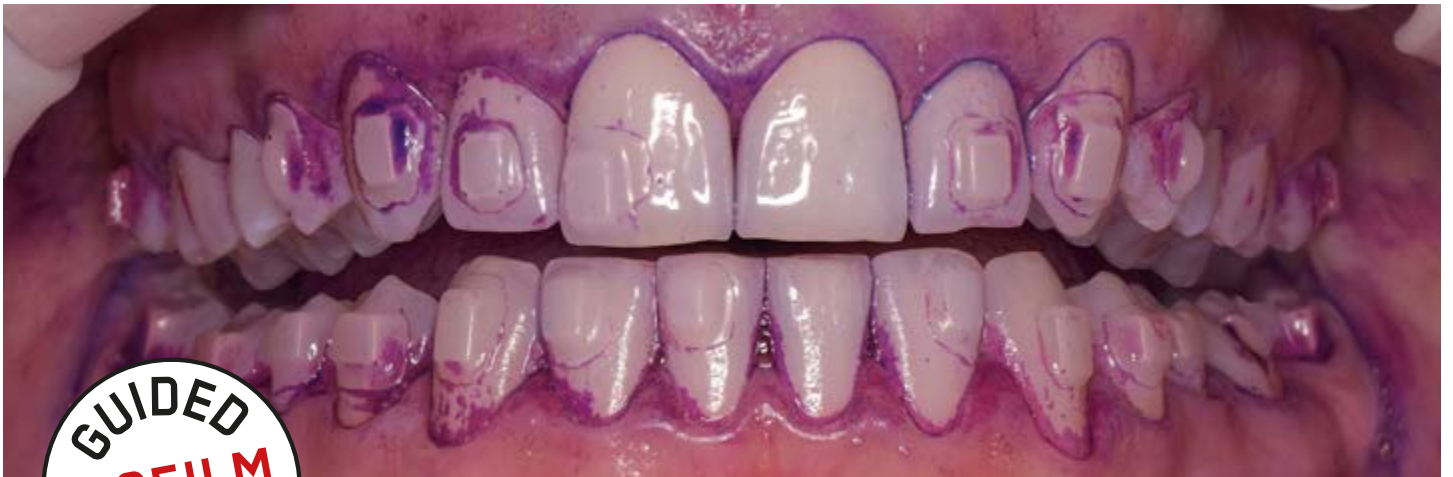
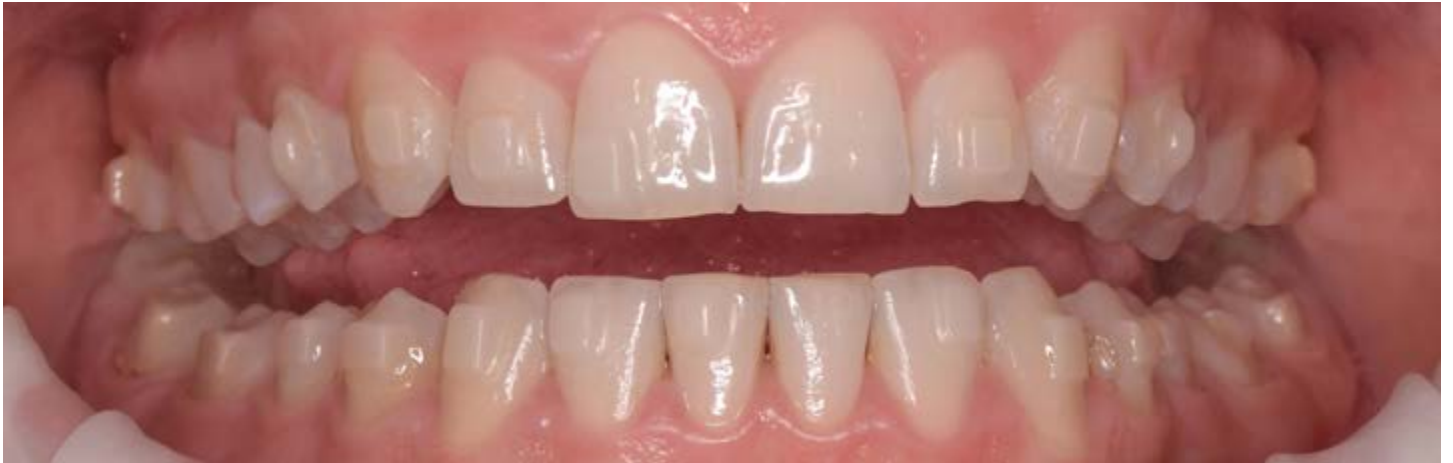100 GBT CLINICAL CASES

GBT PROTOCOL NEW WAYS IN PREVENTION AND PROPHYLAXIS



Dear Clinician,

AN OUNCE OF PREVENTION IS WORTH A POUND OF CURE.

Guided Biofilm Therapy focuses not only on prevention and maintenance of periodontal and peri-implant diseases in adults but is also the only proven protocol to manage biofilm around orthodontics and in non-surgical periodontal treatment. Through this book, we are able to show the implementation of GBT with regard to:

Children: GBT not only enhances motivation but has also proven effective to counter the fear felt by many.

Implants: GBT shows how versatile and efficient it can be.

Maintenance: GBT is the ultimate prevention tool.

Orthodontics: GBT is a complete, efficient and predictable method for biofilm removal.

Non-Surgical periodontal treatment: GBT is perfect to restore great periodontal health.

The simplicity of usage combined with the versatile clinical applications has been highlighted in this Vol.2 for you to share and enjoy.

“The doctor of the future will give no medicine but will instruct his patients in the care of the human frame, in diet, and the cause and prevention of disease” – Thomas A. Edison

Favored by patients and clinicians worldwide, state-of-the-art prophylaxis is showcased in this collection of 100 GBT clinical cases from around the globe. Join the GBT movement!

Your Swiss Dental Academy Team

Nyon/Switzerland, November 10, 2022

Celso Da Costa
Global Director
Swiss Dental Academy
(SDA)

Dr Neha Dixit
Global Lead,
Clinical Affairs and
Medical Education

**“I FEEL
GOOD”**

PS: If you want to be featured in the next GBT Clinical Cases volume, please submit your clinical case to the email address: gbtclinicalcases@ems-ch.com

CHILDREN AND GBT

01	LEYLA BAKIROVA	10
02	ADOLFOVÁ JITKA SMRŽ	12
03	BESSY GEORGARIS	14
04	ROSARIA CATANEO	16
05	PETRA JANÁKOVÁ	18
06	LI BENG WONG	20
07	CHRISSY FORD	22
08	PATRICIA SPAZIERER	24
09	ADINA MAUDER	26
10	GLEB ASEEV	28
11	GLEB ASEEV	30
12	SARA BÅGVIK BÖRJESSON	32
13	BIANCA MARIA MESSINA	34
14	KATARZYNA OSTROWSKA	36
15	SEO-YEON HAN	38
16	ANDRII VOROSHYLOV	40
17	LAUREN SMITH WOODL	42
18	NEY ACURCIO CRUZ	44
19	HENRIETTA VASS	46

IMPLANTS AND GBT

20	ANDREA SALES DO PRADO GODOY	48
21	AUGUSTO ANDRE BAPTISTA	50
22	JACQUES HASSID	52
23	LAUREN SMITH WOODL	54
24	PASCALE HEMELRIJK	56
25	ROXANNE RIGTER	58
26	SERIM CHO	60
27	SEONMI PARK	62
28	BEVERLEY WATSON	64
29	MANUELA NETTO & PEDRO DE LUCA	66
30	MARISA CATANEO	68
31	NICOLE STEVANELLO	70
32	RICCARDO DE ANGELIS	72

MAINTENANCE - RECALL

33	ADINA MAUDER	74
34	ALLISON ARENDZIAK	76
35	BIANCA MARIA MESSINA	78
36	BORIS RADENKOV	80
37	CLAUDIA ELIZALDE MOLINA	82
38	DAI JINJING	84
39	HU XIANG, LV DA, WANG XIYU & CHEN GANG	86
40	MANUELA NETTO & PEDRO DE LUCA	88
41	KIM EUNAE	90
42	FRANCESCA GAMMINO	92
43	SEO GAHYE	94
44	IVA ZEŽULOVA	96
45	JANA KRAJČÍKOVÁ	98
46	KATEŘINA JURENKOVÁ	100
47	KHALID M HANNOUNEH	102
48	LEYLA BAKIROVA	104
49	MARINA KAMEL	106

50	MARLEEN GOOSSEN	108
51	MICHAL HERZINA	110
52	MÍRIAM TORREJÓN AYALA	112
53	NEHA DIXIT	114
54	NICOLE STEVANELLO	116
55	OLGA GRABOWSKA	118
56	ROSARIO MARIA RODRIGUEZ PICHARDO	120
57	SARAH HEUVING	122
58	SIMONE SCHWENKE	124
59	STEPHANIE GÜNTHER	126
60	VANESSA BORKEN	128
61	ZENG CUIYING	130

ORTHODONTICS AND GBT

62	ADINA MAUDER	132
63	ANDRII VOROSHYLOV	134
64	BEATRICE ZVALČÁKOVÁ	136
65	BIANCA MARIA MESSINA	138
66	WU YUPING	140
67	CHIARA DEITOS	142
68	CRISTINA PAVAN	144
69	ESTHER ROVIRA	146
70	KIM EUNAE	148
71	FRANCESCA GAMMINO	150
72	KAROLINA HRUŠOVÁ	152
73	KATARZYNA OSTROWSKA	154
74	KE RONGJI	156
75	KHALID M HANNOUNEH	158
76	LEON ZHONG HONG	160
77	LIU ZHENG	162
78	MAGDALENA MICHAŁOWSKA	164
79	MARIA FERNANDA KOLBE	166
80	MARIANA FONSECA	168
81	MARINA RUSU	170
82	ZHANG LI	172

PERIODONTAL DEBRIDEMENT

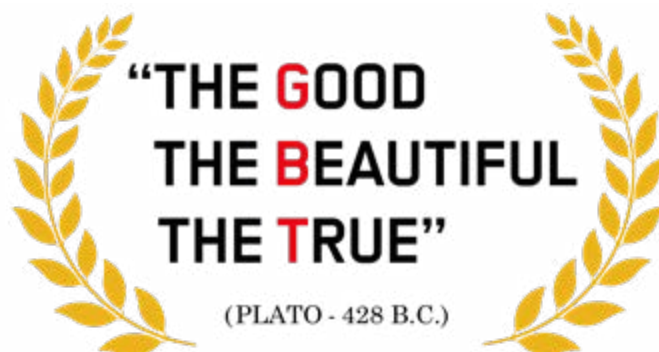83	KAREN NG	174
84	MARIJA SCHEFFLER	176
85	MEREDITH GANTOS	178
86	ADINA MAUDER	180
87	BEATRIZ ROSELL	182
88	BIBIÁNA DUGASOVÁ	184
89	BINTA VISSER	186
90	BÜLENT KURTIS	188
91	ESTHER ROVIRA	190
92	KIM EUNAE	192
93	ABDALLA HANAN	194
94	IVONA BONDOROVÁ	196
95	KHANDA YOUSEF	198
96	MINJUNG KIM	200
97	MAGDALENA GOCOŁ	202
98	ALEKSANDRA MICHALSKA	204
99	NADINE STRAFELA-BASTENDORF	206
100	MATEJ HROPKO,	208

**“I FEEL
GOOD”**



WHY GBT?

- 1 A GAME CHANGER **FOR BETTER ORAL PROPHYLAXIS**
- 2 GOOD ORAL HEALTH = **HEALTHY PATIENT**
- 3 BEST CLINICAL PROTOCOL = **BEST CLINICAL RESULTS.**
GBT REDUCES THE RISK OF CARIES, GINGIVITIS AND PERIODONTAL DISEASE.
“We can be sure only when biofilm has been completely removed.”
Nicole Einemann and Manuela Cordes, Dental Hygienists, Dr. Arendt Dental, Bremerhaven, Germany
- 4 **PATIENTS WANT GBT. NOTHING ELSE.**
NO MORE FEAR OF PAIN. NO MORE DISCOMFORT.
ONCE EXPERIENCED, PATIENTS LOVE GBT,
ESPECIALLY CHILDREN.
- 5 **SATISFIED CLINICIANS,**
RELAXED PATIENTS. EFFICIENT, SYSTEMATIC
WORKFLOW WITH ERGONOMIC INSTRUMENTS.
BYE-BYE STRESS, BYE-BYE CARPAL TUNNEL S., BYE-BYE BIOFILM.
- 6 **SUCCESSFUL DENTAL PRACTICES -**
GOOD MONEY FOR GOOD WORK. ENTHUSIASTIC PATIENTS WILL
RECOMMEND THE **GBT-CERTIFIED** PRACTICE.
- 7 ORAL MEDICINE AND PREVENTION ARE THE **FUTURE OF DENTISTRY.** GBT IS THE FUTURE OF PREVENTION.
- 8 GBT IS A SURPRISING **“I FEEL GOOD EXPERIENCE”.**
STATE-OF-THE-ART IS FAVORED BY PATIENTS.
AND BY CLINICIANS.



Reserve a free GBT Demo: gbt-dental.com/GBT-DEMO-ENG

HOW TO DO GBT?



01 ASSESSMENT AND INFECTION CONTROL

Protect your patients and your practice team from infections. Start GBT by rinsing 40 seconds with BACTERX® PRO. Diagnosis and documentation of the individual supra- and subgingival status for each patient.

02 DISCLOSE

Make the oral biofilm visible by disclosing and explain the **WHY** to the patient. Scientific evidence confirms that oral biofilm causes 95 % of all dental problems: caries, gingivitis and periodontitis.

03 MOTIVATE

Emphasize the importance of oral home care and professional prevention. Instruct your patients in oral hygiene.

04 AIRFLOW® MAX

Eliminate the disclosed biofilm supra- and subgingivally up to 4mm with AIRFLOW® MAX and AIRFLOW® PLUS Powder. The original **AIR-FLOWING®** is minimally invasive and pain-free.*

05 PERIOFLOW®

Remove oral biofilm in deep pockets up to 9mm with PERIOFLOW® NOZZLE and AIRFLOW® PLUS Powder.*

06 PIEZON® PS

Gently remove calculus with the original PIEZON® NO PAIN PS Instrument.*

07 CHECK

Check whether oral biofilm and calculus have been removed completely and whether previously hidden caries is now visible. Conventional professional teeth cleaning removes only 50 % of oral biofilm in areas that are difficult to reach. Source: Stiftung Warentest 7/2015. **NO MORE POLISHING**. Polishing and grinding with abrasive pastes is truly no longer necessary. Why produce unnecessary smear layers?

08 RECALL

Would your patient like to answer the GBT questionnaire?
This is helpful for a successful GBT treatment.
Schedule the next prophylaxis appointment.

*Learn more about how GBT works in practice, how to avoid dust when AIR-FLOWING®, how to use PERIOFLOW® correctly or how to minimize the risk of emphysema at the Swiss Dental Academy (SDA): sda.dental/Contact-GBT-Expert



**A REGULAR GBT RECALL GUARANTEES
LASTING ORAL HEALTH FOR YOUR PATIENTS.**

We recommend a free GBT Demo: gbt-dental.com/GBT-DEMO-ENG

THE GBT COMPASS AND

08 RECALL

HEALTHY PATIENT = HAPPY PATIENT

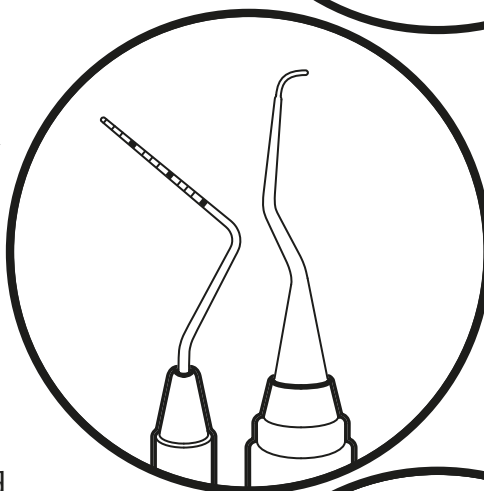
- ▶ Schedule recall frequency according to risk assessment
- ▶ Ask your patient if he or she liked the treatment



07 CHECK

MAKE YOUR PATIENT SMILE

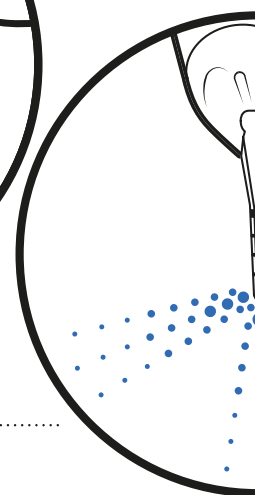
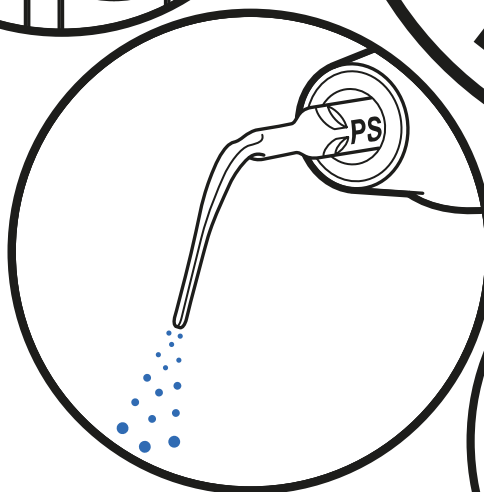
- ▶ Do a final check for remaining biofilm
- ▶ Ensure calculus is fully removed
- ▶ Accurately diagnose caries
 - ▶ Protect with fluoride
 - ▶ No polishing anymore



06 PIEZON® PS

REMOVE REMAINING CALCULUS

- ▶ Use the minimally invasive EMS PIEZON® PS Instrument supra- and subgingivally up to 10 mm
- ▶ Clean > 10 mm pockets with mini curette
 - ▶ Use EMS PIEZON® PI MAX Instrument around implants up to 3 mm subgingivally and on restorations



05 PERIOFLOW®

REMOVE BIOFILM IN >4 TO 9 MM POCKETS

- ▶ Use AIRFLOW® PLUS Powder on natural teeth in deep pockets and root furcations and on implants
- ▶ Use new and slimmer PERIOFLOW® Nozzle

ITS 8-STEP PROTOCOL

01 ASSESSMENT AND INFECTION CONTROL

ASSESS EVERY CLINICAL CASE AND IMPLEMENT HYGIENE MEASURES

- ▶ Start by rinsing with BacterX® Pro mouthwash
- ▶ Assess teeth, gingiva and periodontal tissues
- ▶ Assess implants and peri-implant tissues

02 DISCLOSE

MAKE BIOFILM VISIBLE

- ▶ Highlight to patients the disclosed biofilm and their problematic areas with EMS Biofilm Discloser
- ▶ The color will guide biofilm removal
 - ▶ Once biofilm is removed, calculus is easier to detect

03 MOTIVATE

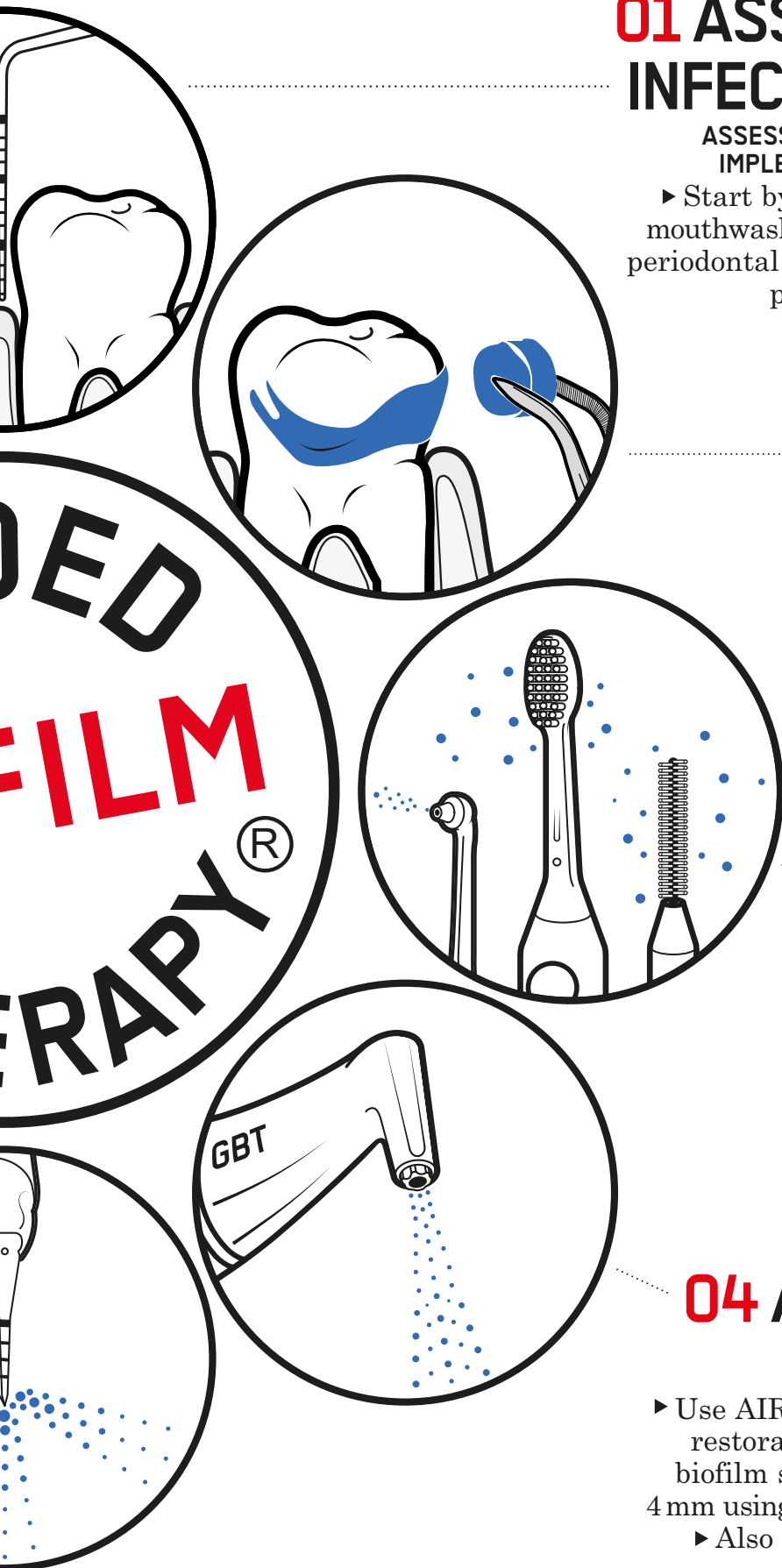
RAISE AWARENESS AND TEACH

- ▶ Emphasize the importance of prevention
- ▶ Instruct your patients in oral hygiene
- ▶ EMS recommends interdental brushes or dental floss as well as electric or manual toothbrushes and AIRFLOW® erythritol toothpaste for daily home care

04 AIRFLOW® MAX

REMOVE BIOFILM, STAINS AND EARLY CALCULUS

- ▶ Use AIRFLOW® MAX for natural teeth, restorations and implants
- ▶ Remove biofilm supra- and subgingivally up to 4 mm using AIRFLOW® PLUS 14µm Powder
 - ▶ Also remove biofilm from gingiva, tongue and palate



CHILDREN AND GBT

CASE 1



CLINICIAN

Leyla Bakirova
Dentist
Azerbaijan

PATIENT INFORMATION

- ▶ Age 18, female.

BACKGROUND INFORMATION

- ▶ First professional prophylaxis. Worried about procedure. No relevant habits.

CLINICAL FINDINGS

- ▶ Poor oral hygiene, large amounts of biofilm present.

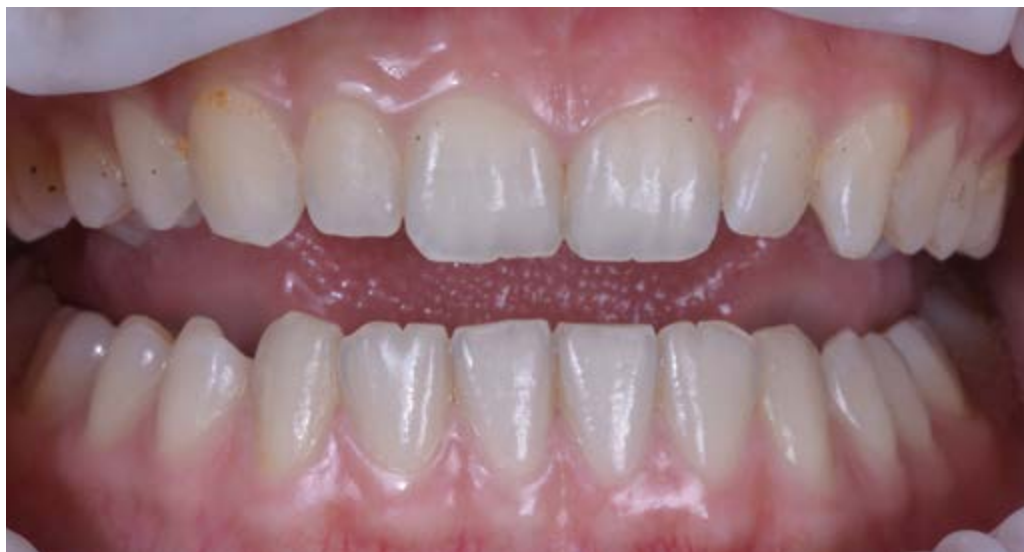TREATMENT

- ▶ GBT with AIRFLOW® PLUS Powder and PIEZON® PS Instrument + fluoride application. Instructions for proper oral hygiene.

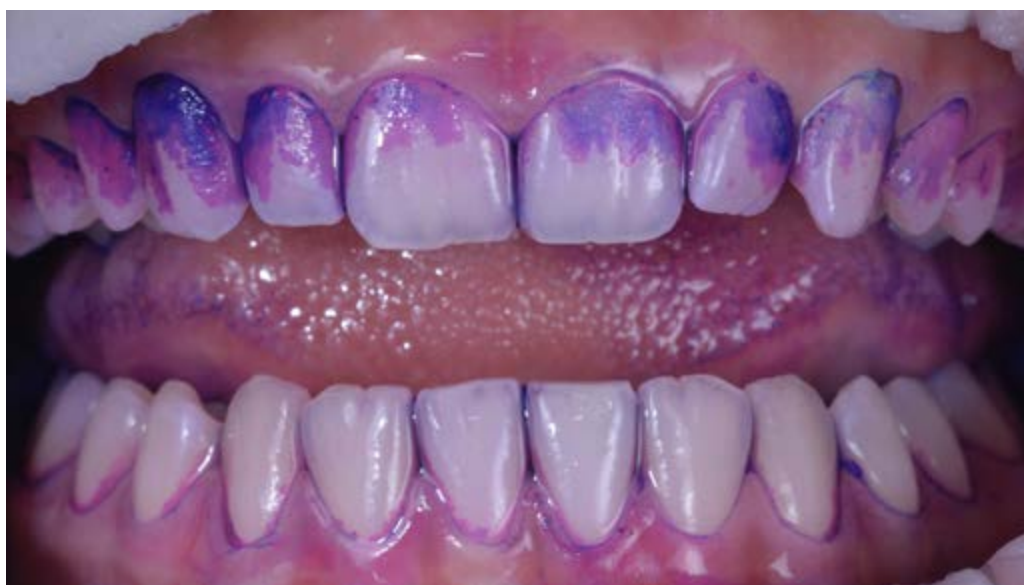PATIENT FEEDBACK

“I NEVER FELT MY TEETH SO SMOOTH, THANK YOU VERY MUCH!”

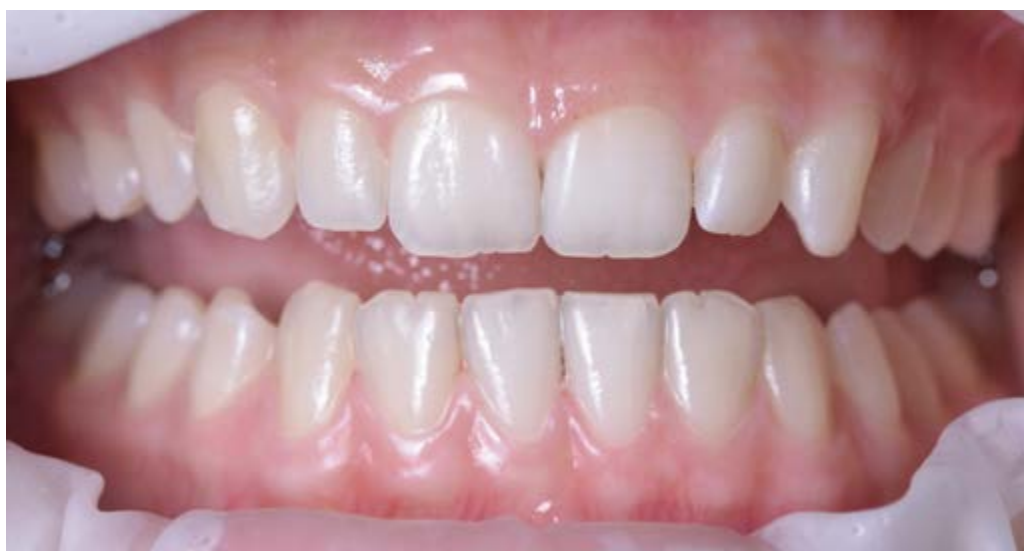BEFORE GBT



**AFTER
DISCLOSING**



AFTER GBT



CHILDREN AND GBT

CASE 2



CLINICIAN

Adolfova Jitka Smrz
Dental hygienist
Czech Republic

PATIENT INFORMATION

- ▶ Age 11, male.

BACKGROUND INFORMATION

- ▶ Patient has never been to a dental hygienist. He had bad experience with a previous treatment at the dentist. It was necessary to communicate with the patient and his older sister because parents do not speak Czech. No relevant habits.

CLINICAL FINDINGS

- ▶ Poor oral hygiene, gingivitis caused by biofilm. Generalized bleeding on probing. Presence of supragingival and subgingival calculus, periodontal pockets under 4 mm.

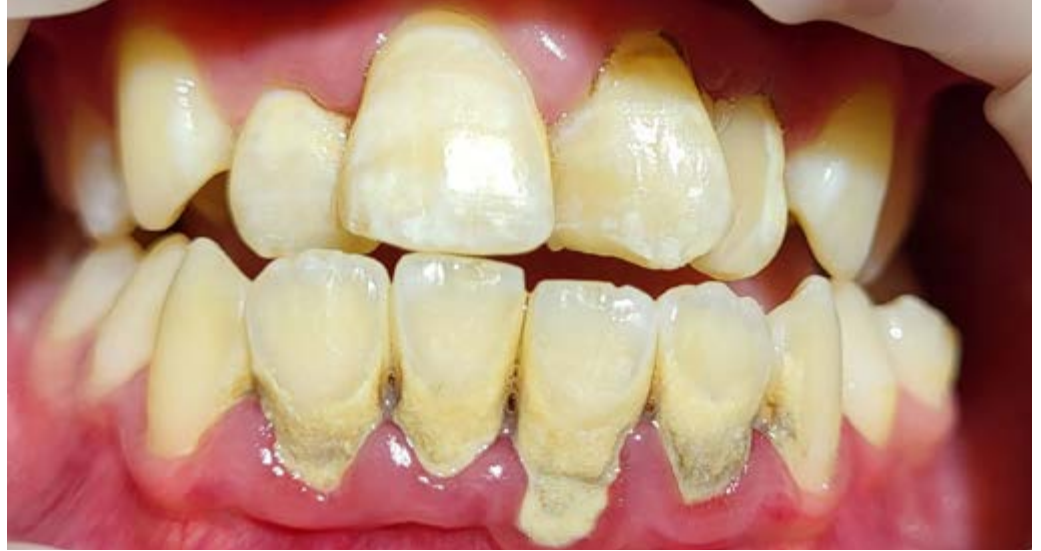TREATMENT

- ▶ GBT done with AIRFLOW® PLUS Powder and PIEZON® PS Instrument to remove all residual biofilm and calculus. Initial therapy comprised of 3 appointments every two weeks. Next recall is in 3 months.

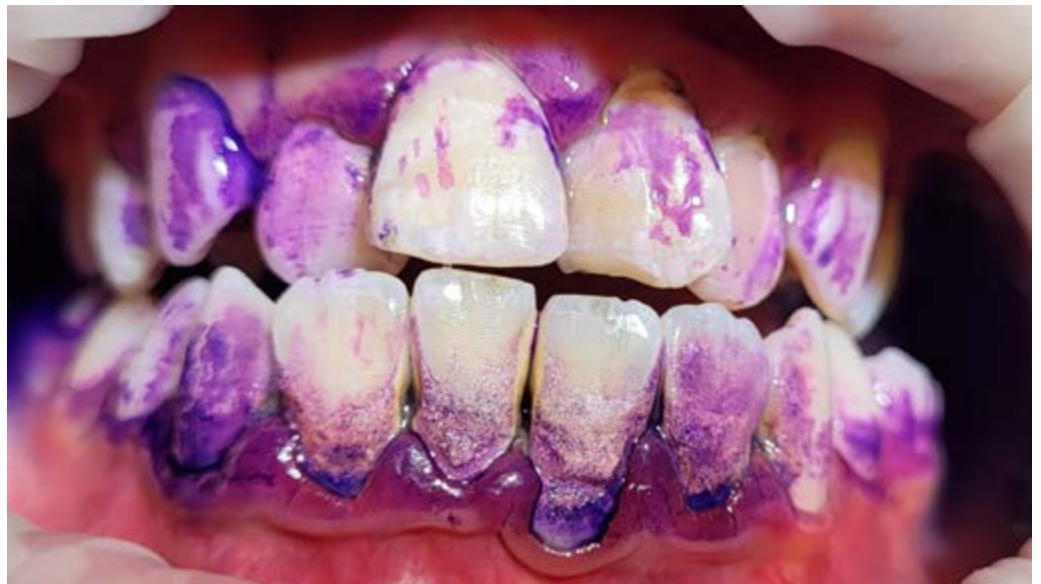PATIENT FEEDBACK

“IT’S SO COOL! IT’S THE FIRST TIME THAT I’M NOT AFRAID TO COME BACK.”

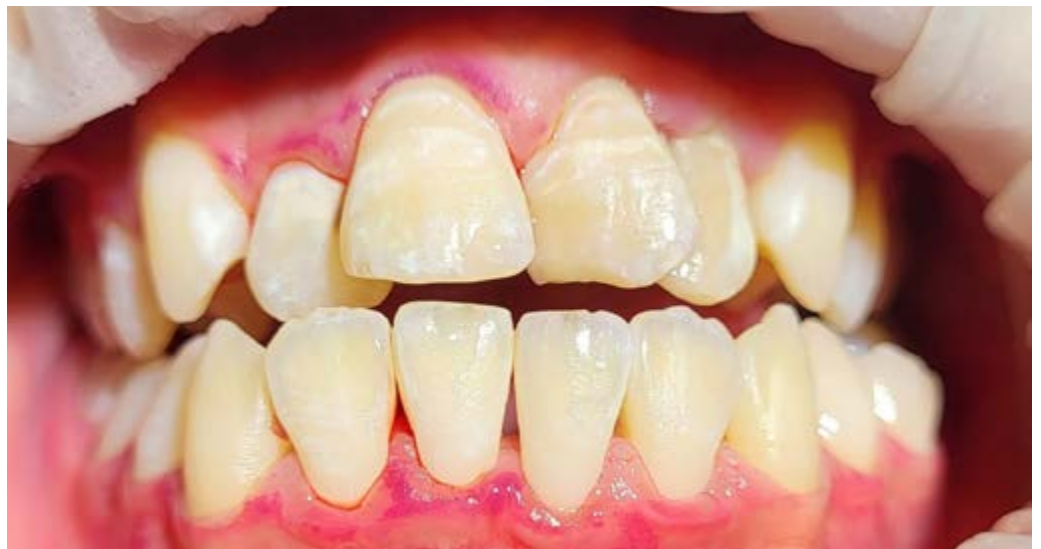BEFORE GBT



**AFTER
DISCLOSING**



AFTER GBT



CHILDREN AND GBT

CASE 03



CLINICIAN

Bessy Georgaris
Dental hygienist
United States

PATIENT INFORMATION

- ▶ Age 14, male.

BACKGROUND INFORMATION

- ▶ Patient had a bad experience in the past during prophylaxis. Very sensitive and scared when he entered. No relevant habits.

CLINICAL FINDINGS

- ▶ Bleeding on probing positive. Presence of interdental calculus.

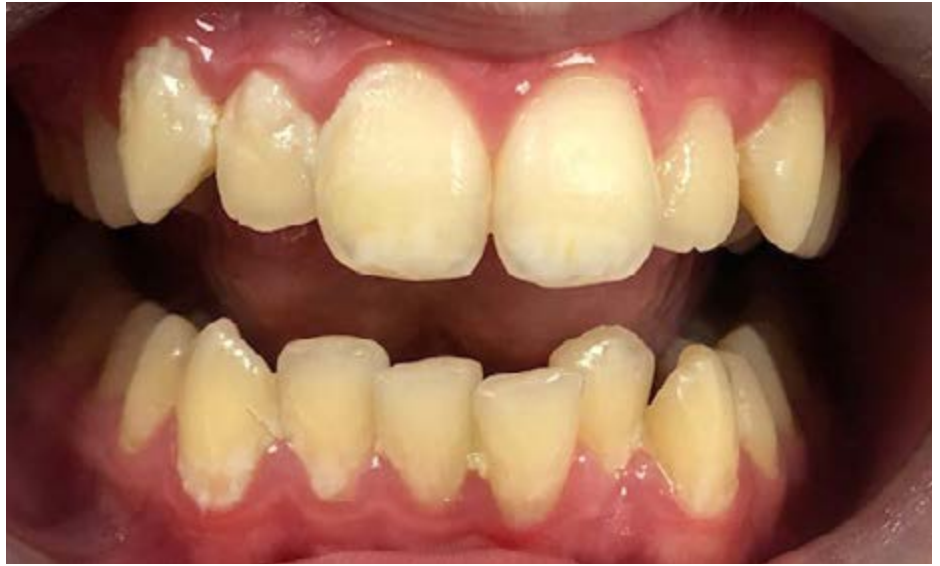TREATMENT

- ▶ Performed GBT. He was « petrified » to see all the biofilm he leaves behind and was more motivated than ever during the hygiene instructions! He thought he was going to suffer during his treatment and was positively surprised of how comfortable it was and how clean he felt after erythritol powder was used with AIRFLOW® MAX to remove all the biofilm. PIEZON® PS Instrument was also used supragingivally to remove hard calculus in a few areas.

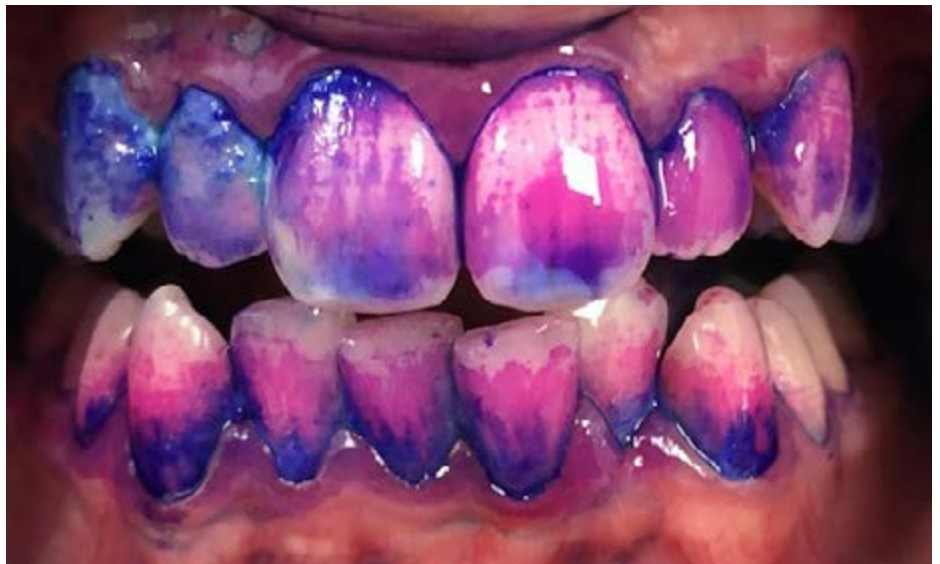PATIENT FEEDBACK

“I AM VERY SURPRISED WITH THE RESULTS OF DISCLOSING, VERY MOTIVATED FOR HYGIENE INSTRUCTIONS AND GBT IS VERY COMFORTABLE DURING CLEANING”

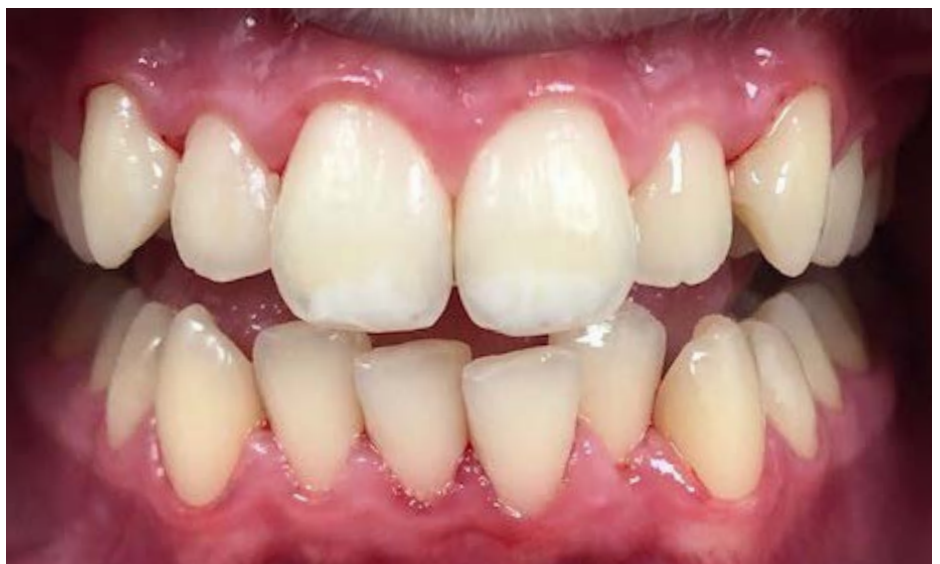BEFORE GBT



**AFTER
DISCLOSING**



AFTER GBT



CHILDREN AND GBT

CASE 04



CLINICIAN

Rosaria Cataneo
Specialist
Italy

PATIENT INFORMATION

- ▶ Age 17, male.

BACKGROUND INFORMATION

- ▶ Poor oral hygiene, no relevant medical history. Patient with no relevant habits.

CLINICAL FINDINGS

- ▶ Very poor oral hygiene, large amounts of biofilm in both jaws, calculus in frontal part in lower jaw, no interdental hygiene, formation of acidic biofilm.

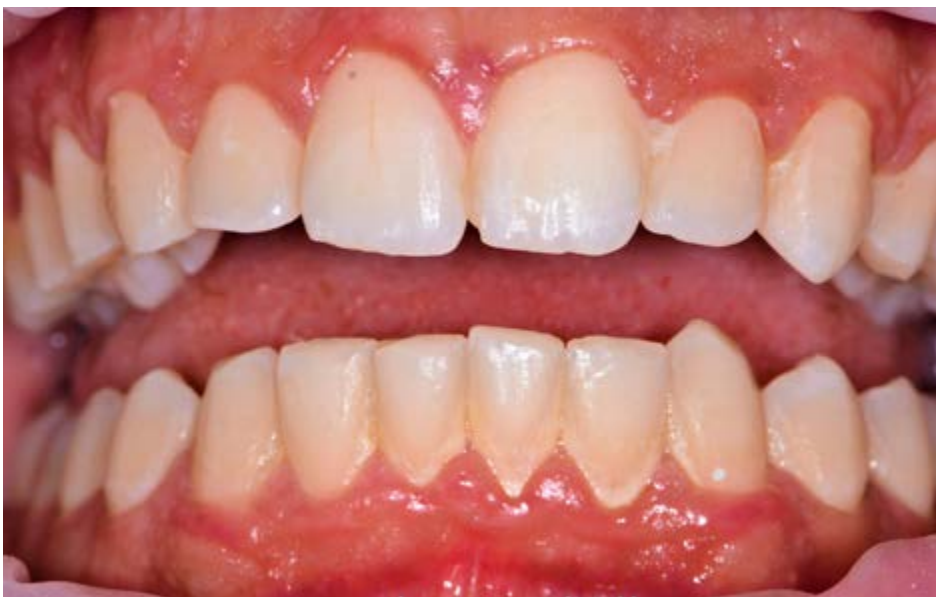TREATMENT

- ▶ GBT done with AIRFLOW® PLUS Powder, PIEZON® PS Instrument.

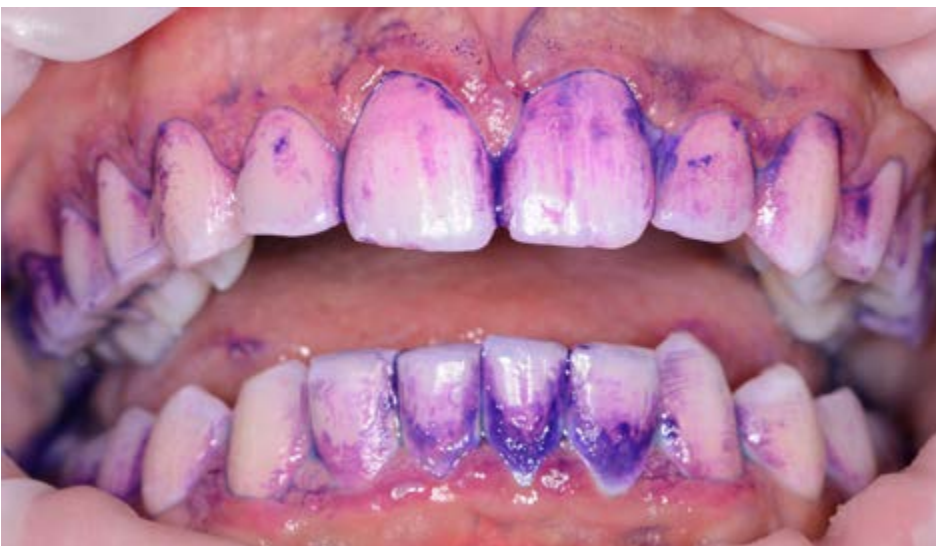PATIENT FEEDBACK

“BEFORE THE TREATMENT I WASN’T EXPECTING MUCH FROM IT BUT IT REALLY DID CHANGE MY ORAL HYGIENE AND NOW I FEEL LIKE I HAVE A NEW MOUTH.”

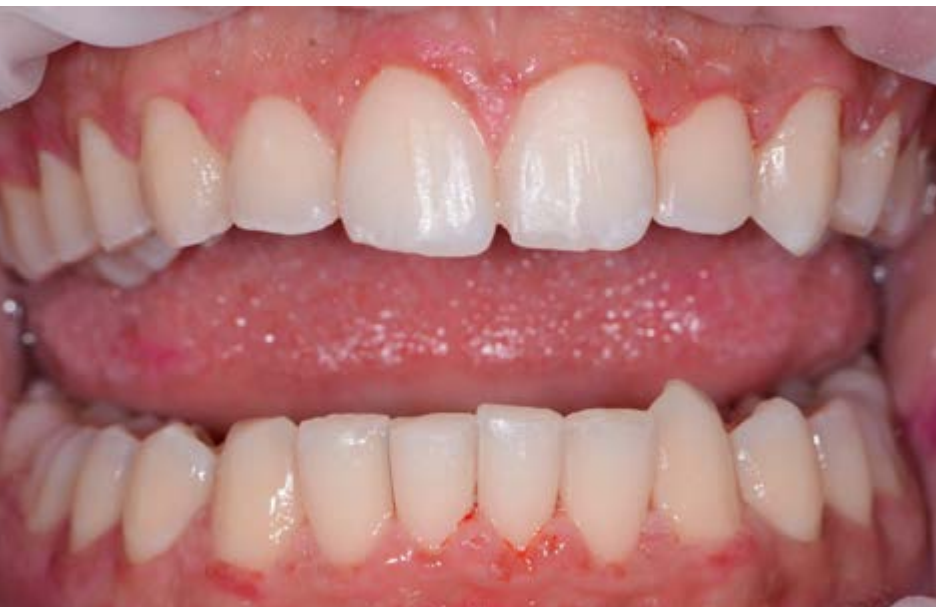BEFORE GBT



**AFTER
DISCLOSING**



AFTER GBT



CHILDREN AND GBT

CASE 05



CLINICIAN

Petra Janáková
Dental hygienist
Czech Republic

PATIENT INFORMATION

- ▶ Age 13, female.

BACKGROUND INFORMATION

- ▶ Young patient with good general health. Very diverse eating habits. Brushes teeth twice a day with manual toothbrush. Visits a dentist and orthodontist for checkups periodically once a year. Patient was advised to see a dental hygienist because of bleeding and receding gums. No relevant habits.

CLINICAL FINDINGS

- ▶ Gingivitis (inflammation of the gums). BOP +. Poor oral hygiene. Insufficient dental care in lateral part of the teeth and cervical area. Intact teeth with local demineralization. Thin vestibulum and recessions in frontal area of lower jaw.

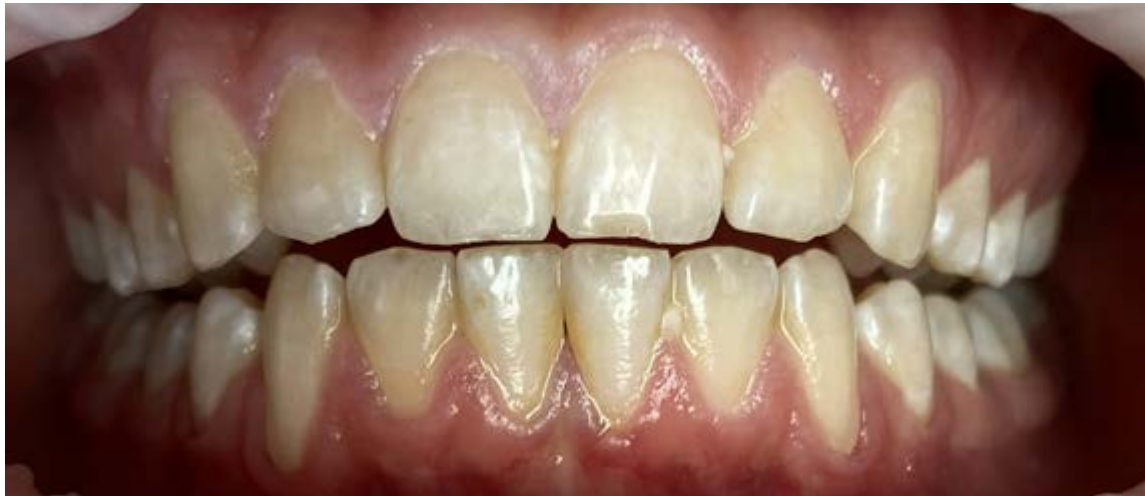TREATMENT

- ▶ GBT protocol was done using AIRFLOW® PLUS Powder. Supragingival calculus removed by using PIEZON® PS Instrument. Fluoridation with Varnish Profluorid. Motivation and education of patient about regular dental care. Patient was shown how to use interdental brushes and appropriate aids for home care. First recall after 12 weeks, then every 6 months. Recommendation to see a periodontal surgeon because of thin vestibulum.

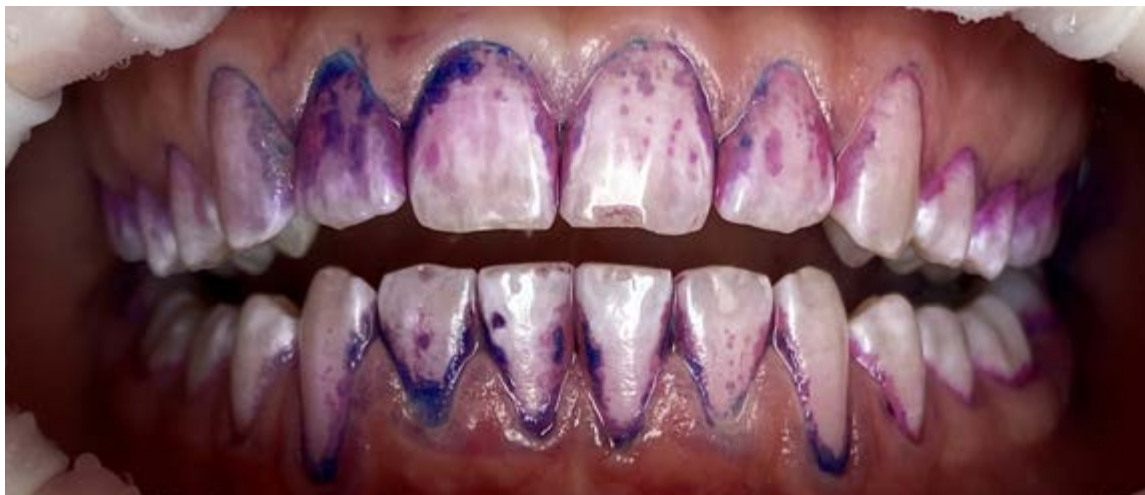PATIENT FEEDBACK

“I DID NOT WANT TO GO TO THE DENTAL HYGIENIST AT FIRST BUT AFTERWARDS I WAS QUITE IMPRESSED HOW MY TEETH WERE CLEAN AND SHINY.”

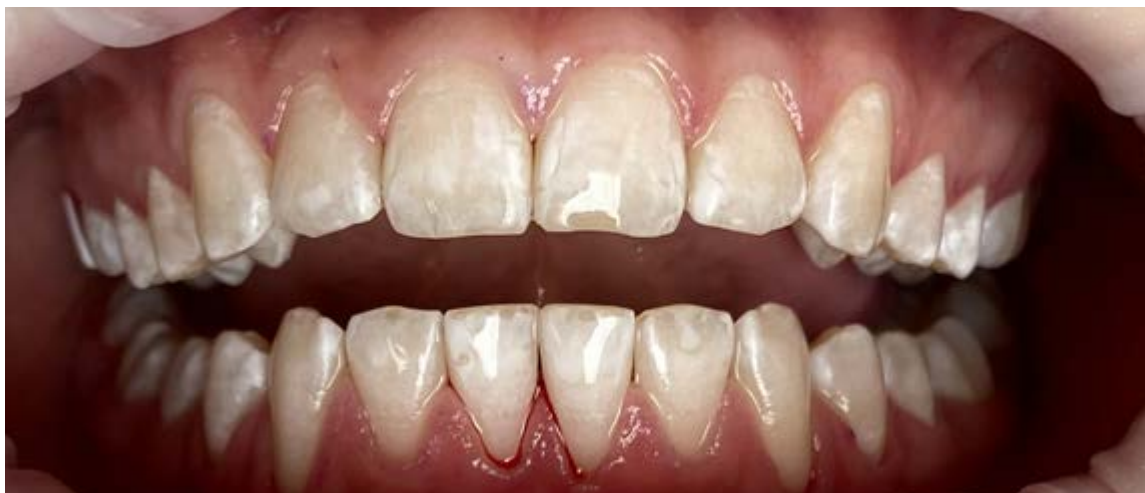BEFORE GBT



AFTER DISCLOSING



AFTER GBT



CHILDREN AND GBT

CASE 06



CLINICIAN

Li beng Wong
Periodontist
Singapore

PATIENT INFORMATION

- ▶ Age 13, male.

BACKGROUND INFORMATION

- ▶ Never visited a dentist before for prophylaxis due to dental phobia, not motivated to maintain good oral hygiene. No relevant habits.

CLINICAL FINDINGS

- ▶ Poor oral hygiene. Generalized gingival inflammation with heavy biofilm deposit.

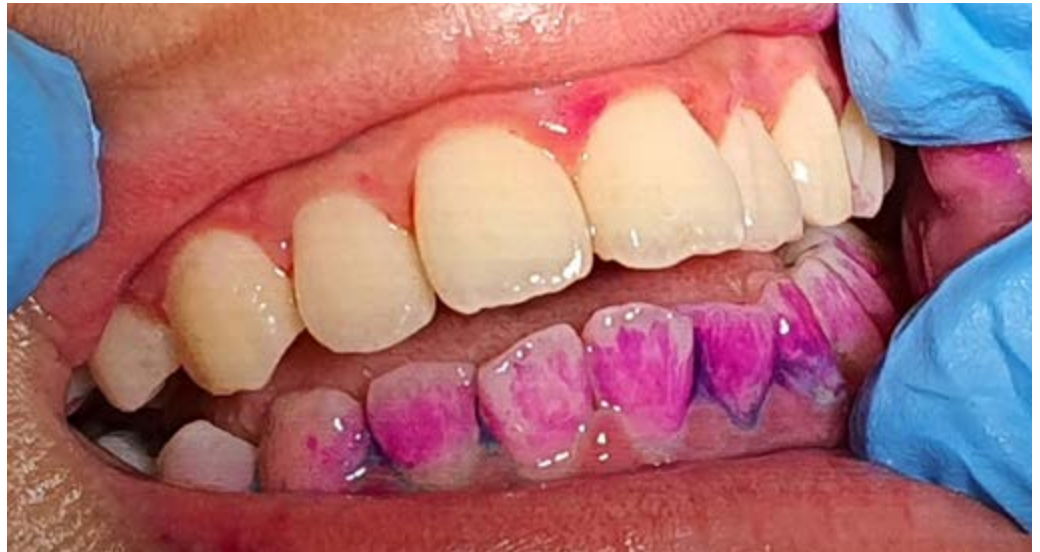TREATMENT

- ▶ Use of pre-rinse mouthwash, followed by biofilm disclosure and motivation (chairside brushing and flossing demonstration). AIRFLOW® treatment was carried out using AIRFLOW® PLUS Powder. Calculus removal at certain interproximal areas was performed using PIEZON® PS Instrument without need for local anesthesia. Final check for any residual biofilm, calculus and caries. Patient was placed on recall every 6 months.

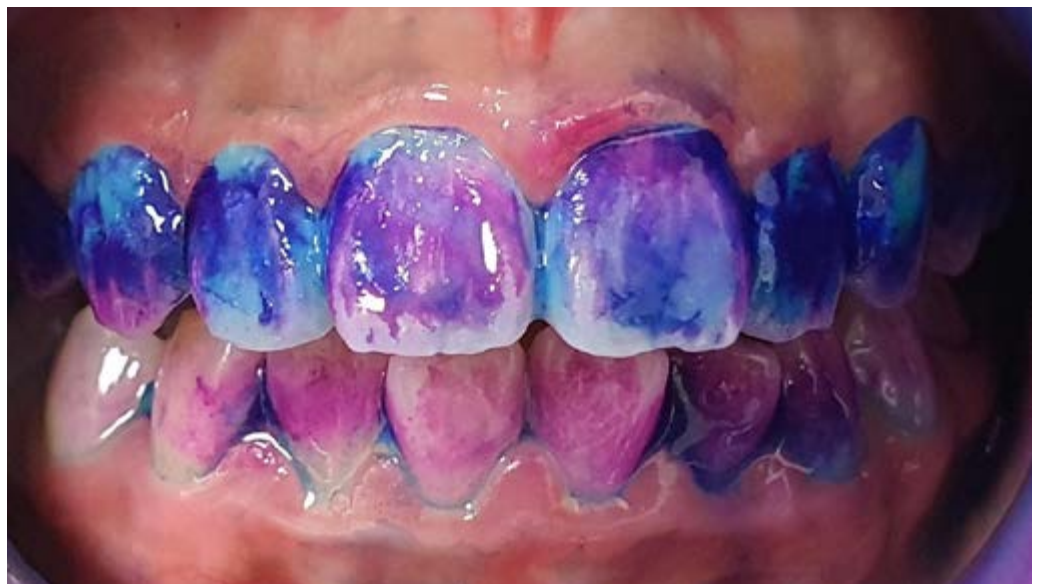PATIENT FEEDBACK

“TREATMENT IS MUCH MORE COMFORTABLE THAN WHAT I IMAGINED IT TO BE. I WILL DEFINITELY ASK MY MOTHER, WHO IS ALSO SCARED TO SEE DENTIST, TO TRY OUT GBT TREATMENT.”

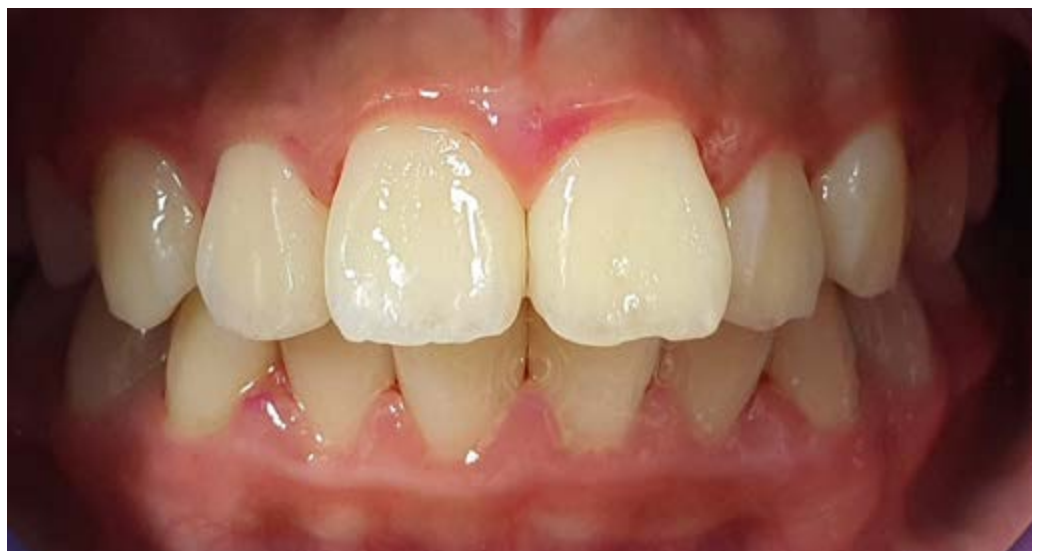BEFORE GBT



**AFTER
DISCLOSING**



AFTER GBT



CHILDREN AND GBT

CASE 07



CLINICIAN

Chrissy Ford
Dental hygienist
Canada

PATIENT INFORMATION

- ▶ Age 10, male.

BACKGROUND INFORMATION

- ▶ Bad previous dental experience due to sensory processing disorder. Anxiety over textures and taste in the dental office. Poor oral hygiene and compliance issues using toothpaste due to flavoring.

CLINICAL FINDINGS

- ▶ Generalized gingivitis with moderate biofilm and bleeding at maxillary anterior crowding.

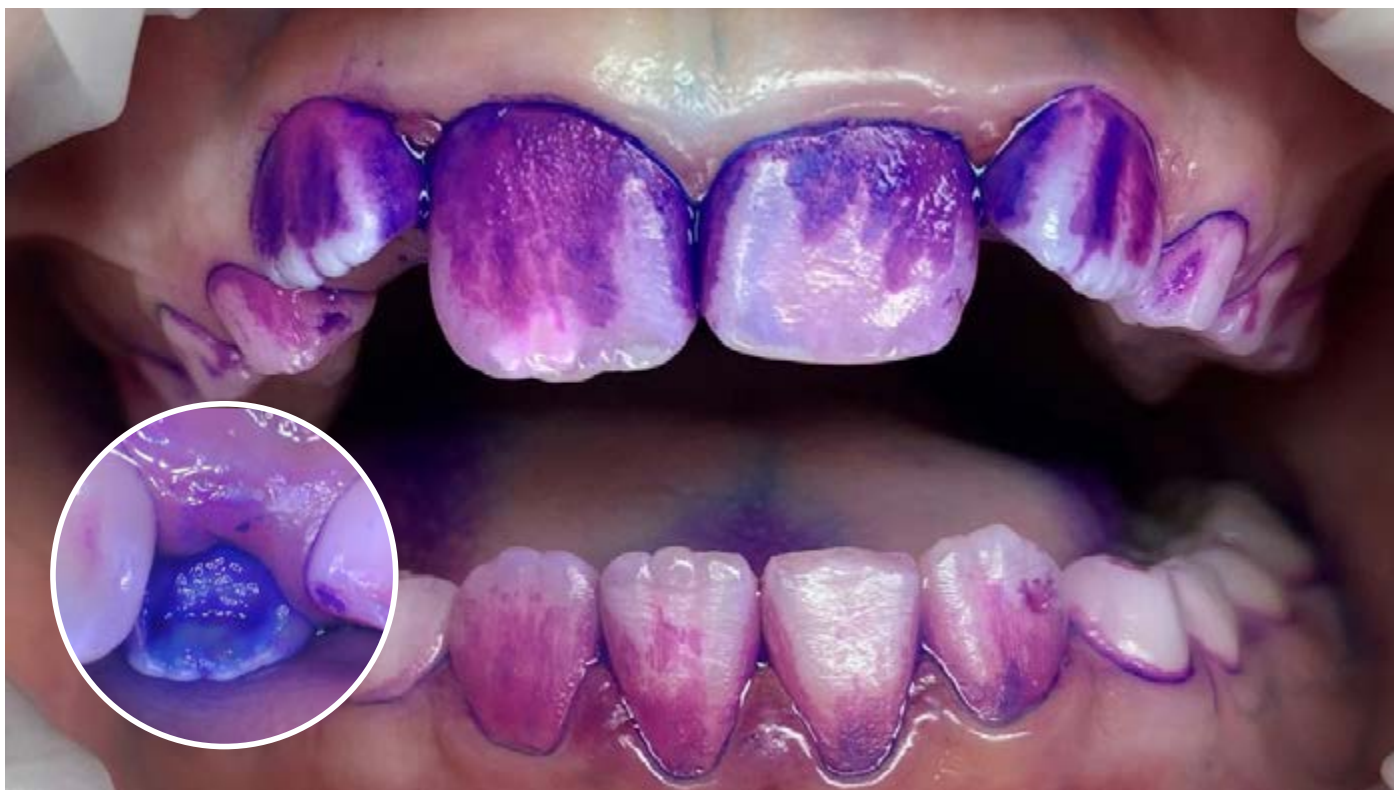TREATMENT

- ▶ Full GBT treatment was completed with AIRFLOW® PLUS Powder and localized early calculus removed with the PIEZON® PI Instrument.

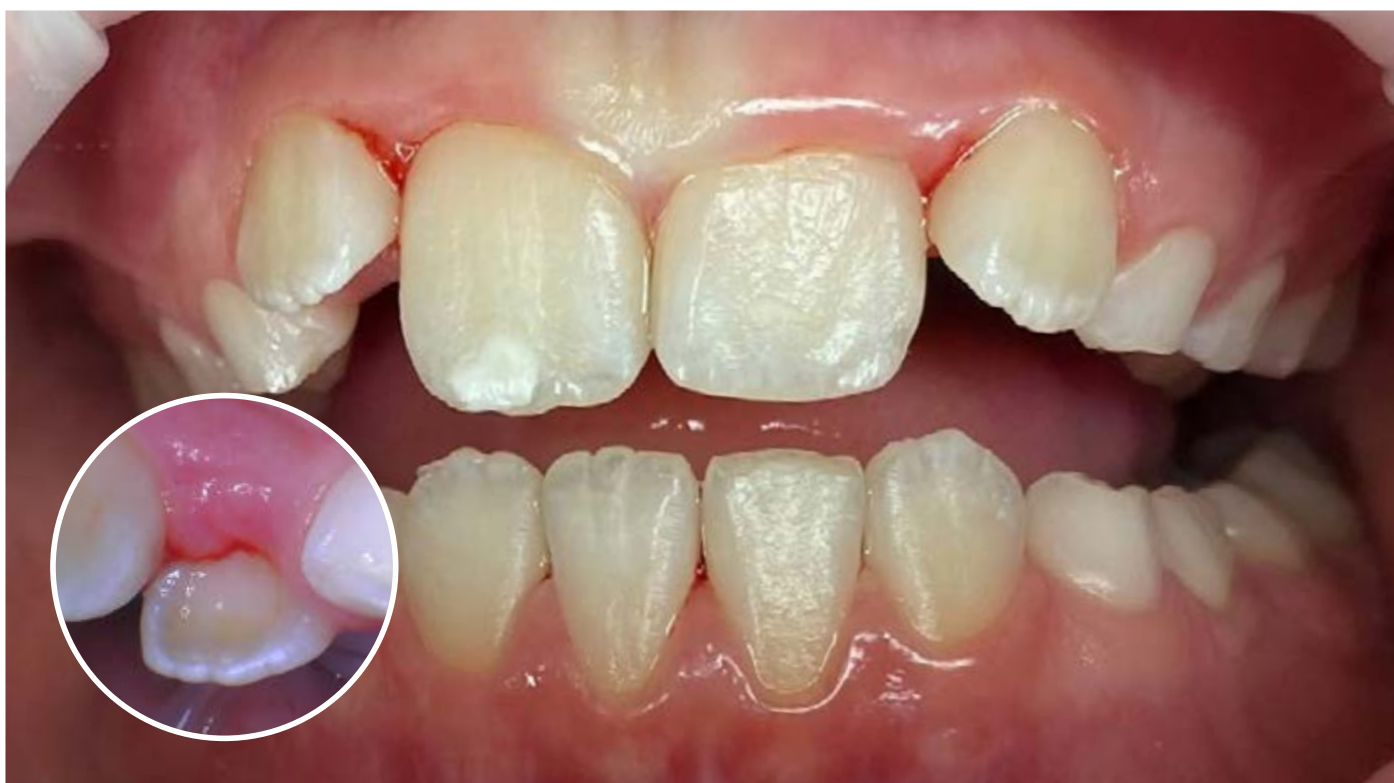PATIENT FEEDBACK

“I SURE LIKED THE TOOTH SHOWER BETTER THAN MY LAST CLEANING!”

AFTER DISCLOSING



AFTER GBT



CHILDREN AND GBT

CASE 08



CLINICIAN

Patricia Spazierer
Dental hygienist
Germany

PATIENT INFORMATION

- ▶ Age 17, male.

BACKGROUND INFORMATION

- ▶ Habits: consumes many soft drinks, Does not use interdental care, uses oscillating toothbrush. Patient is stubborn. Poor oral hygiene in general.

CLINICAL FINDINGS

- ▶ Average oral hygiene, gingivitis, BOP +, PBI 66%, API 62%.

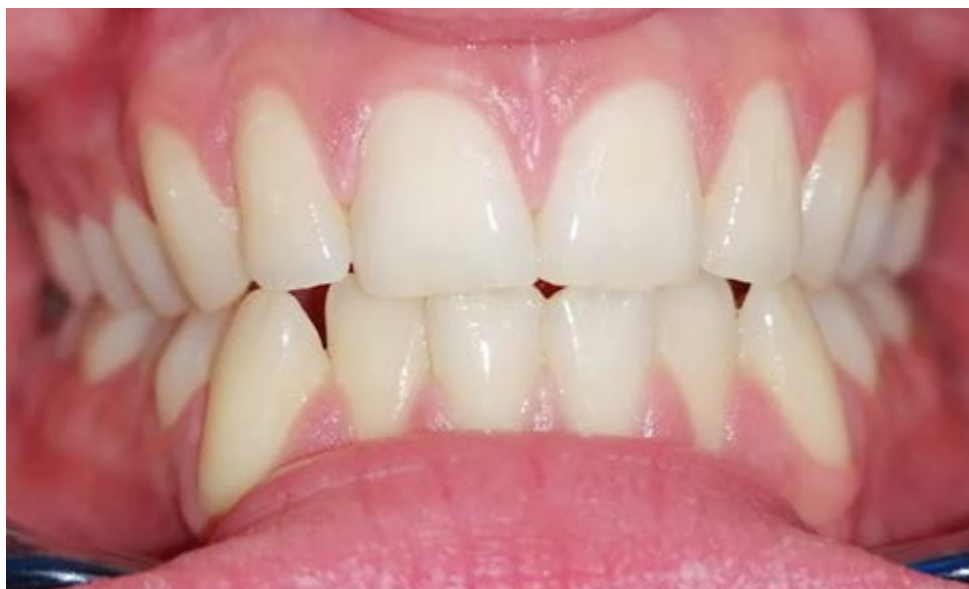TREATMENT

- ▶ The patient was treated according to the GBT protocol after detailed oral hygiene instructions, AIRFLOW® PLUS Powder, PIEZON® PS Instrument, UK Front lingual in the gaps, M23 scaler and explorer probe were used for control. The recall was set at 6 months. In-depth demonstration with TePe interdental space brushes (red and blue), demonstration handling oscillating toothbrush was given. Advised to lower soft-drink consumption in order to reduce biofilm and disease.

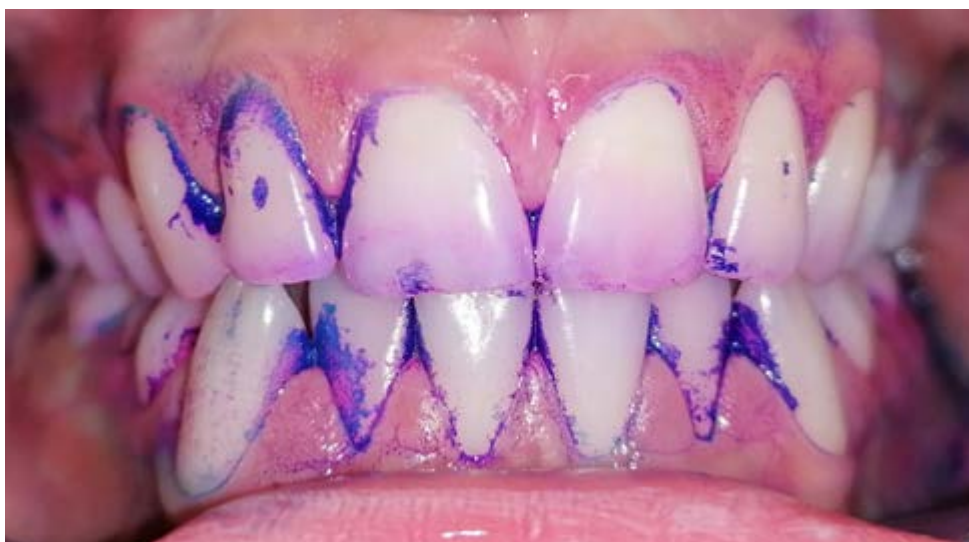PATIENT FEEDBACK

“TREATMENT WAS EXTREMELY PLEASANT. I AM HAPPY THAT I WILL BE ABLE TO FIGHT CARIES AND GUM DISEASE. BUT I WILL CONTINUE MY SOFT DRINKS.”

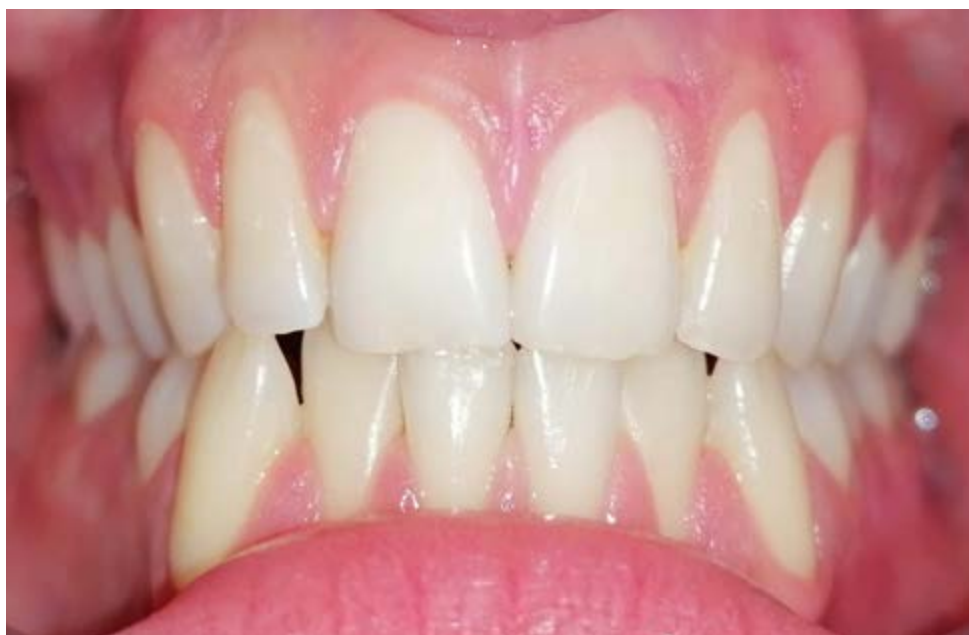BEFORE GBT



**AFTER
DISCLOSING**



AFTER GBT



CHILDREN AND GBT

CASE 09



CLINICIAN

Adina Mauder
Dental hygienist
Germany

PATIENT INFORMATION

- ▶ Age 6, female.

BACKGROUND INFORMATION

- ▶ Healthy smiling girl, visited the dental office for the 2nd time. Good eating habits. Wanted to change her hygienist as she had heard about a new modern teeth cleaning method. Biofilm was never disclosed to this patient.

CLINICAL FINDINGS

- ▶ Good oral hygiene, brushes teeth regularly twice a day. No BOP, no calculus.

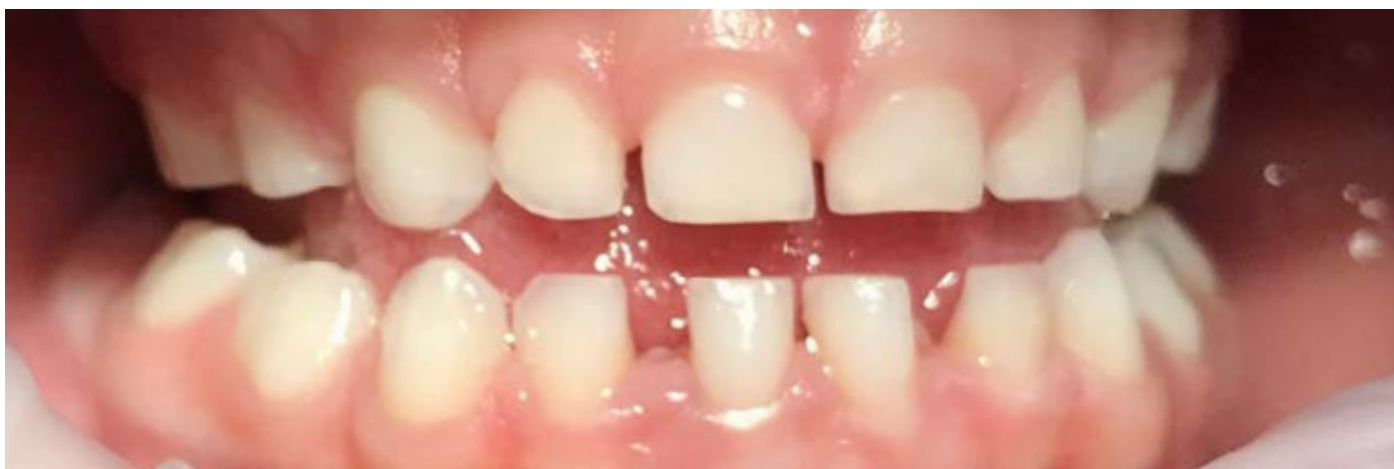TREATMENT

- ▶ Patient was shown where the biofilm is through disclosure. Tooth brushing with a manual brush was shown. GBT with AIRFLOW® MAX and erythritol PLUS Powder. Patient scheduled for regular recall.

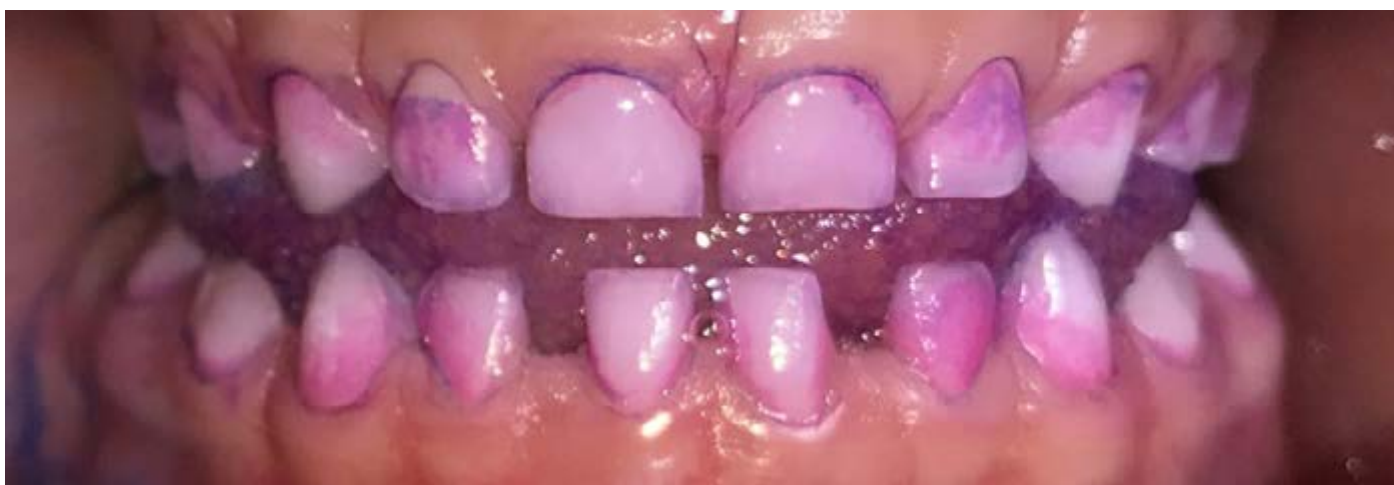PATIENT FEEDBACK

“I AM SURPRISED TO SEE BACTERIA IN MY MOUTH, GBT FELT LIKE A MOUTH SHOWER. I WILL COME BACK, GBT IS FUN.”

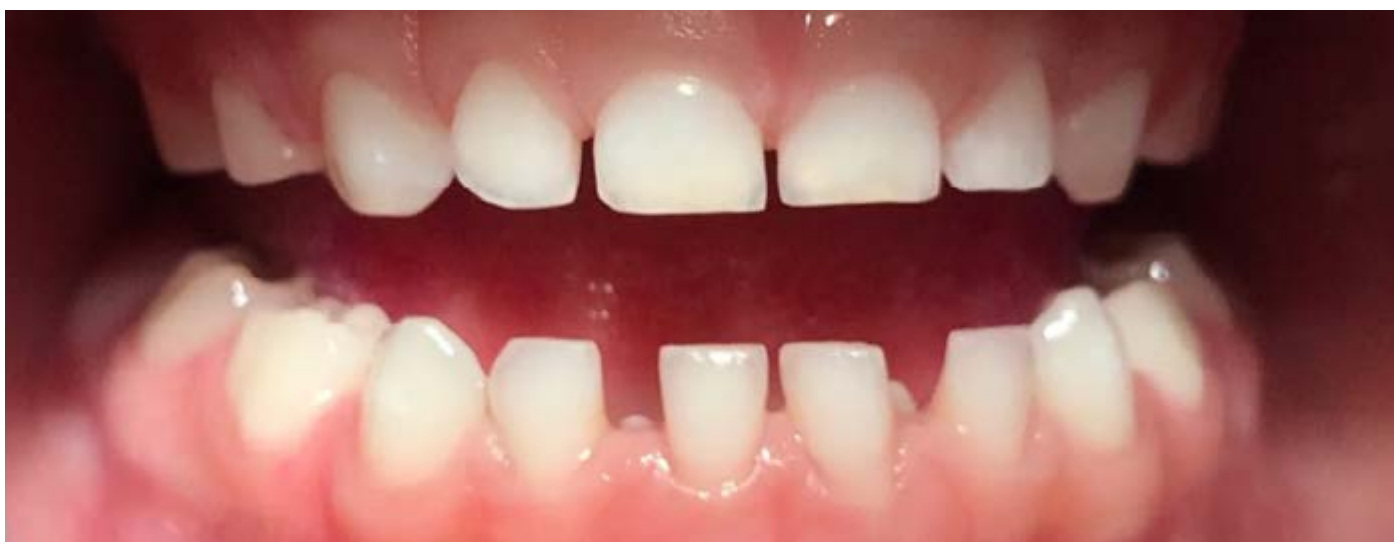BEFORE GBT



AFTER DISCLOSING



AFTER GBT



CHILDREN AND GBT

CASE 10



CLINICIAN:

Gleb Aseev
Dentist
Russia

PATIENT INFORMATION

- ▶ Age 8, male.

BACKGROUND INFORMATION

- ▶ Bilateral cleft palate and lip. Restricted opening of the mouth. Bad oral hygiene. We did GBT before the surgical treatment, then treated the teeth and completed the GBT treatment again. Previously, there were 3 operations on the palate and lips. The child is preparing for the next operations.

CLINICAL FINDINGS

- ▶ Type of condition: generalized gingivitis, very high level of bleeding on probing.

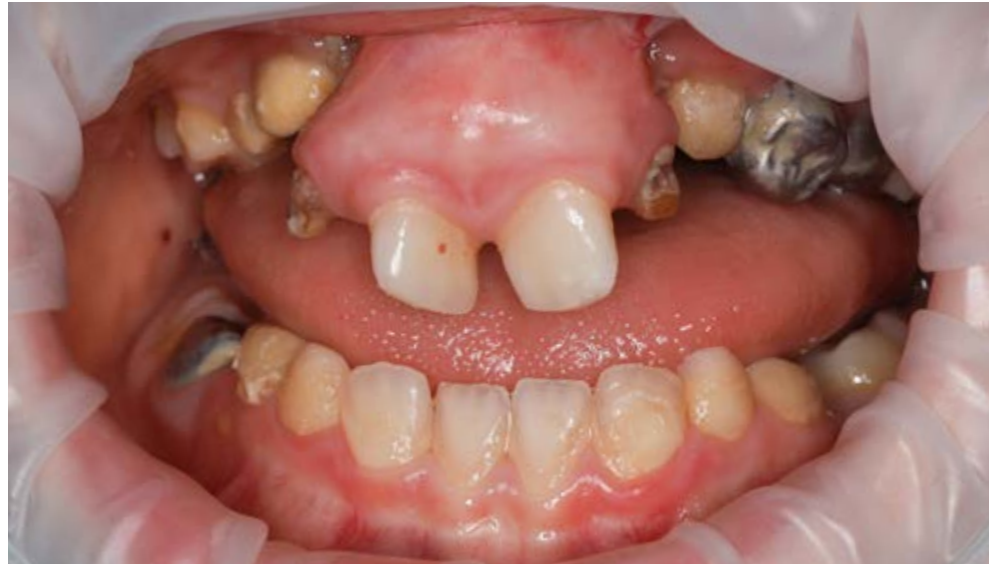TREATMENT

- ▶ Standard GBT protocol using only AIRFLOW® PLUS Powder. Emphasis on patient motivation.

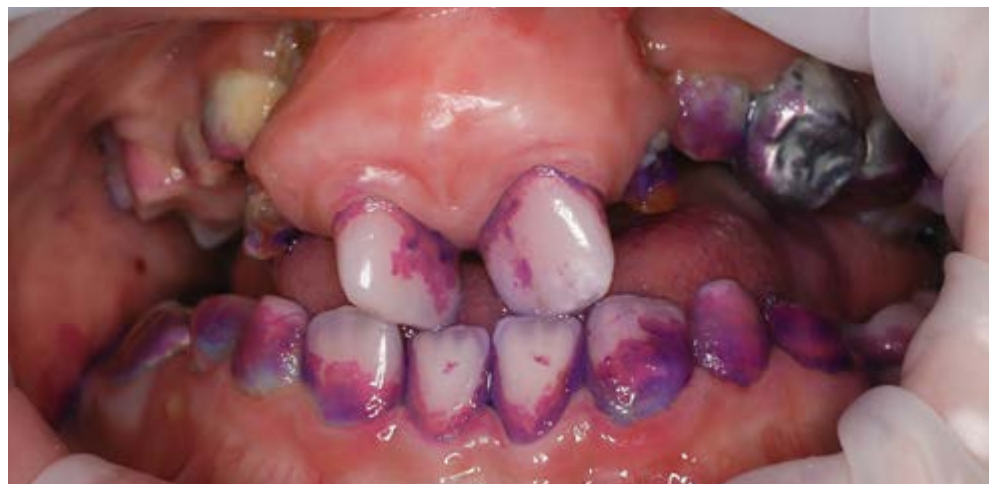PATIENT FEEDBACK

“PARENTS NOTED AN INCREASE IN THE CHILD’S INTEREST IN HOME CLEANING OF TEETH. THE CHILD NOTED A DECREASE IN THE LEVEL OF ANXIETY AND FEAR OF DENTAL TREATMENT.”

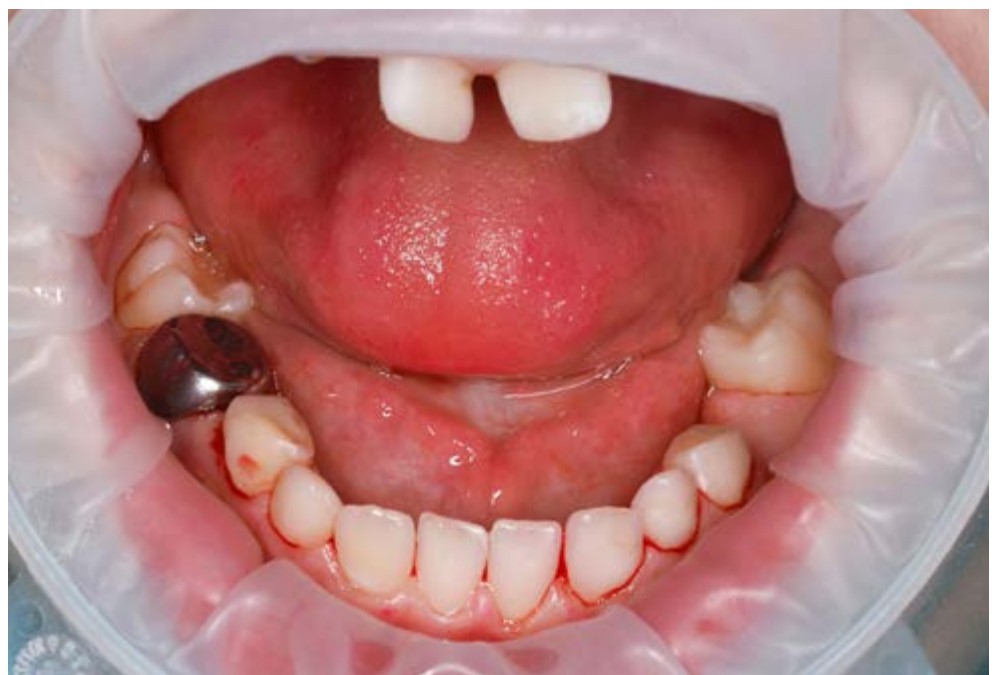BEFORE GBT



**AFTER
DISCLOSING**



AFTER GBT



CHILDREN AND GBT

CASE 11



CLINICIAN:

Gleb Aseev
Dentist
Russia

PATIENT INFORMATION

- ▶ Age 6, male.

BACKGROUND INFORMATION

- ▶ Routine visit of the patient for hygiene and preventive examination. The patient is in the mixed dentition stage. Presence of sensitivity in many areas.

CLINICAL FINDINGS

- ▶ Type of condition: gingivitis, low level of bleeding on probing.

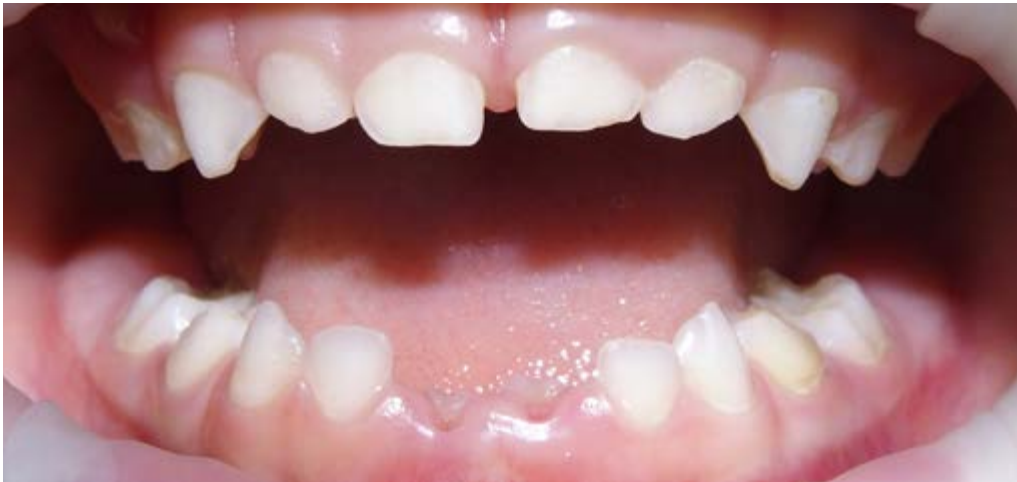TREATMENT

- ▶ We did standard GBT protocol without PERIOFLOW® technology. In the area of teeth that are just erupting, it is necessary to work very carefully. The use of erythritol powder allows us to clean the biofilm surface around the soft tissues without causing damage.

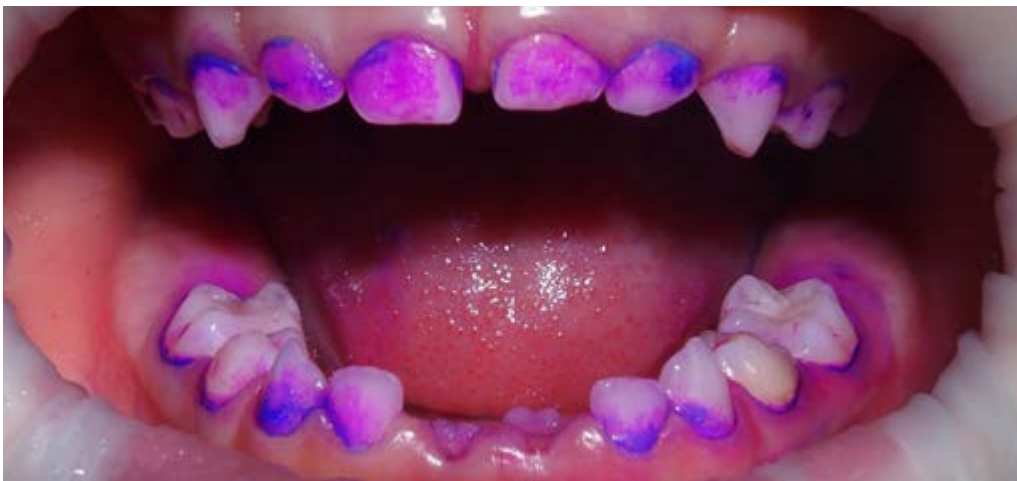PATIENT FEEDBACK

“I LOVE THE TASTE OF THE POWDER USED IN GBT!”

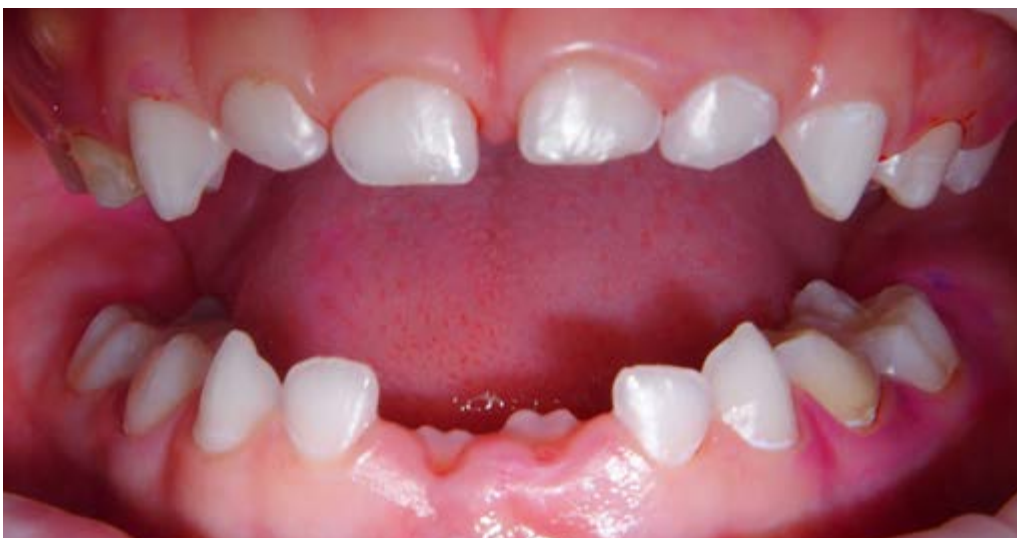BEFORE GBT



AFTER DISCLOSING



AFTER GBT



CHILDREN AND GBT

CASE 12



CLINICIAN

Sara Bågvik Börjesson
Dental hygienist
Sweden

PATIENT INFORMATION

- ▶ Age 11, female.

BACKGROUND INFORMATION

- ▶ The mother called clinic and was worried about the black stains her daughter has. She was also concerned that the stains would cause teasing in school. Patient claims she brushes twice a day. The mother was not so sure about that.

CLINICAL FINDINGS

- ▶ Black stains, mainly on the buccal and lingual surfaces. Most visible up front. The stains are thin, but firmly attached to the teeth. Mixed dentition.

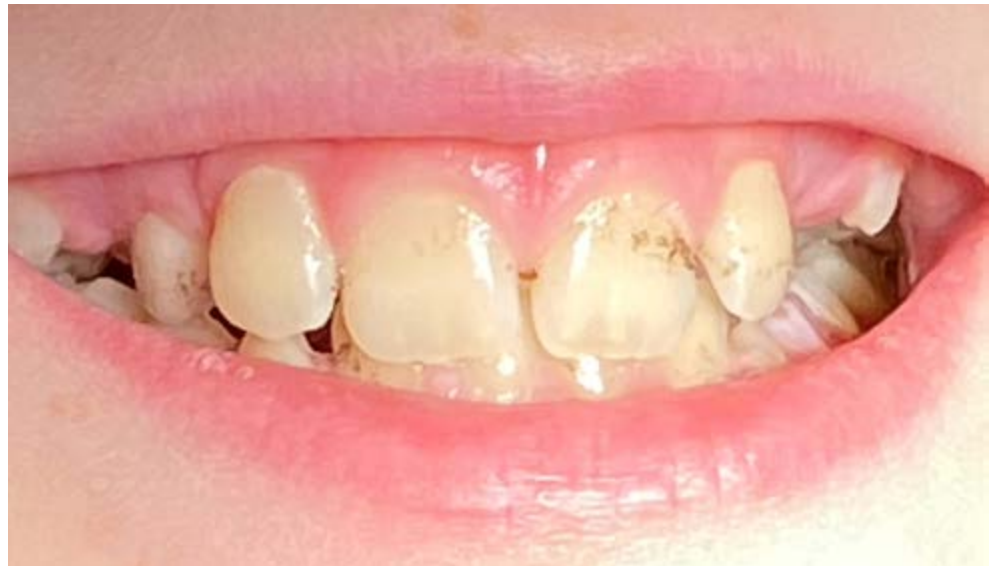TREATMENT

- ▶ GBT removed the black stains and biofilm completely. The patient could follow the process in the mirror. GBT done with AIRFLOW® PLUS Powder.

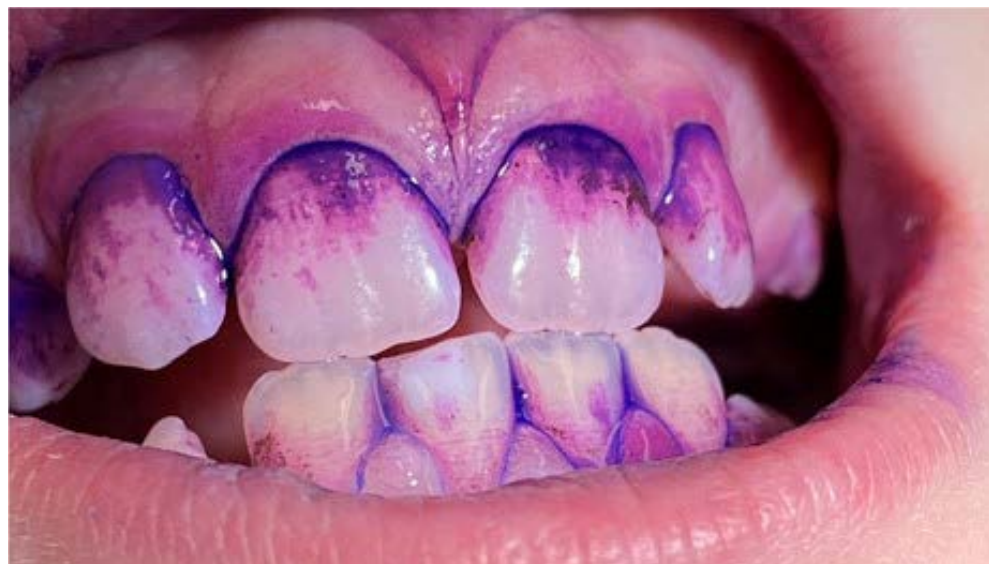PATIENT FEEDBACK

“THANK YOU FOR SHOWING MY DAUGHTER HOW TO PREVENT NEW STAINS.”

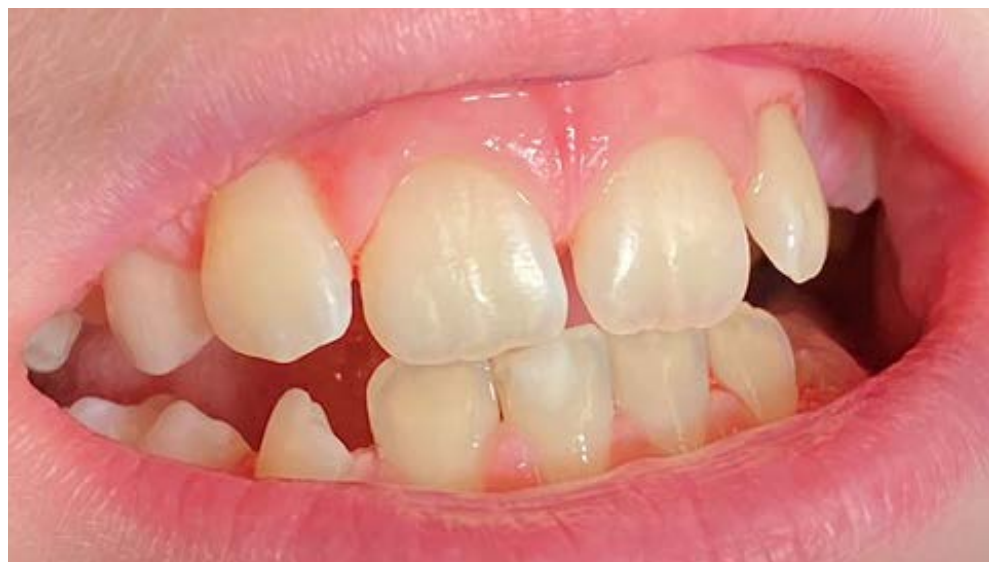BEFORE GBT



**AFTER
DISCLOSING**



AFTER GBT



CHILDREN AND GBT

CASE 13



CLINICIAN

Bianca Maria Messina
Dental hygienist
Italy

PATIENT INFORMATION

- ▶ Age 11, female.

BACKGROUND INFORMATION

- ▶ First visit to dental hygienist, before orthodontic therapy.
Uses only manual toothbrush.

CLINICAL FINDINGS

- ▶ Visible biofilm.

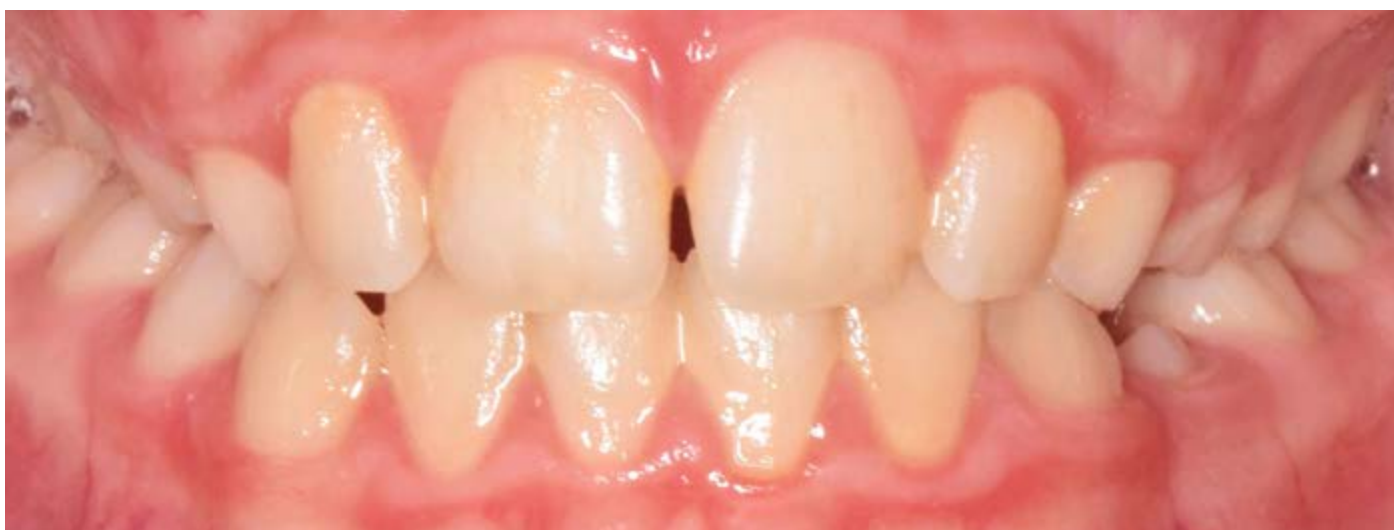TREATMENT

- ▶ Biofilm disclosed using the Biofilm Discloser from EMS. Patient motivation through the use of electric toothbrush. GBT performed with only AIRFLOW® PLUS Powder to remove biofilm.

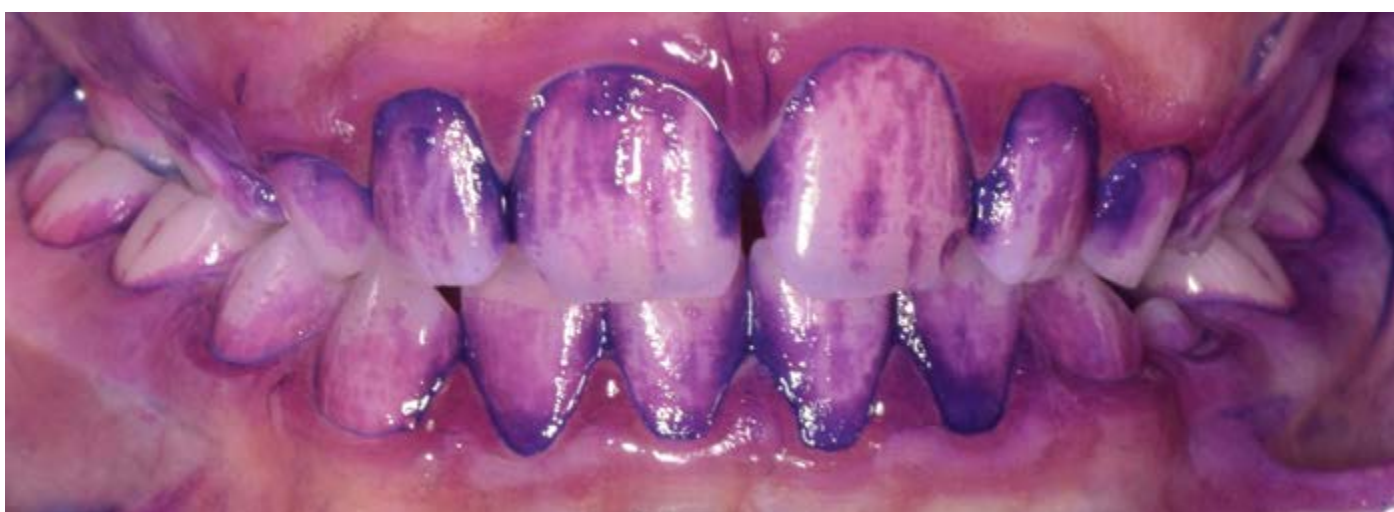PATIENT FEEDBACK

“I’M VERY HAPPY, I DON’T HAVE DIRTY TEETH.”

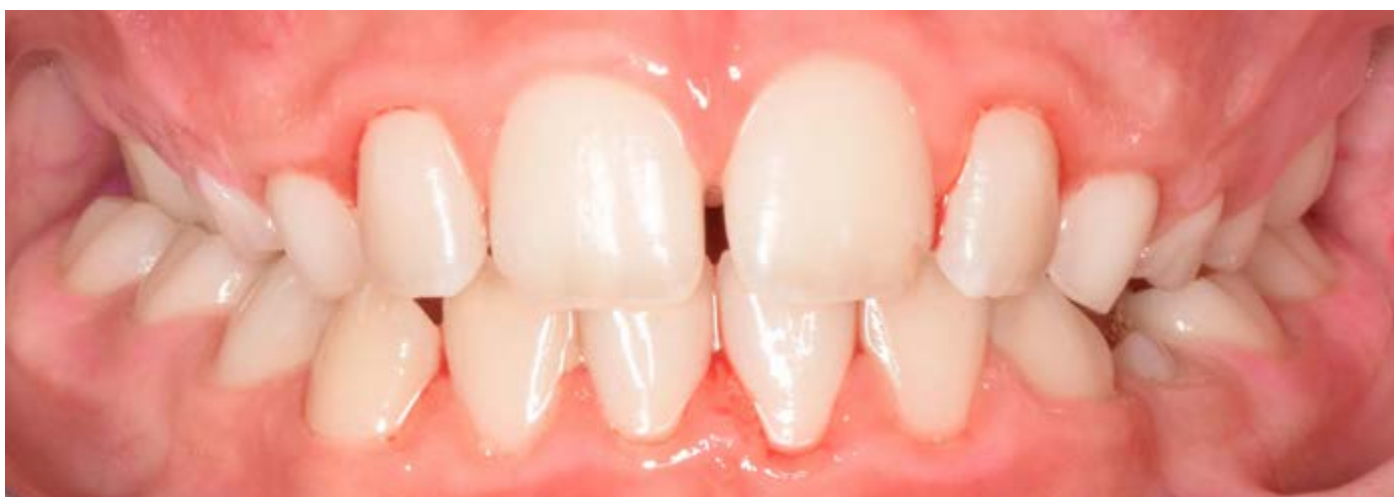BEFORE GBT



AFTER DISCLOSING



AFTER GBT



CHILDREN AND GBT

CASE 14



CLINICIAN

Katarzyna Ostrowska
Dental hygienist
Poland

PATIENT INFORMATION

- ▶ Age 12, male.

BACKGROUND INFORMATION

- ▶ Uses a manual toothbrush, 1550 ppm fluoride toothpaste.
- Neurological patient: epilepsy, treated pharmacologically with Depakine chronosphere (valproic acid).

CLINICAL FINDINGS

- ▶ Poor hygiene, no cavities, numerous mineralized deposits, abundant biofilm, occasional dry mouth (due to medications taken).

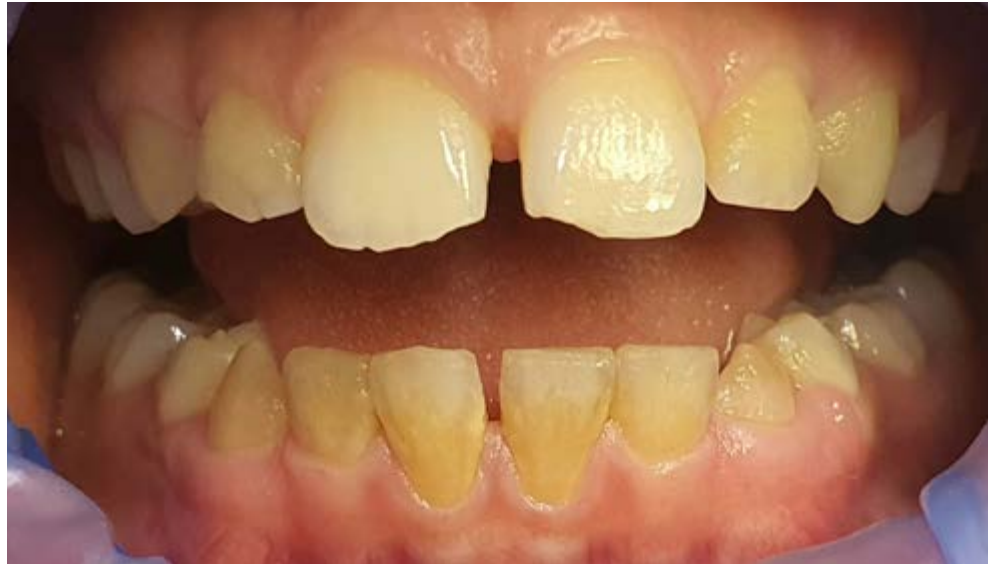TREATMENT

- ▶ Professional hygiene according to GBT protocol, fluoride varnishing with FluoroDose. Recommendation: ORP electric toothbrush, SPLAT oral foam, increased water intake. Next visit in 2 months.

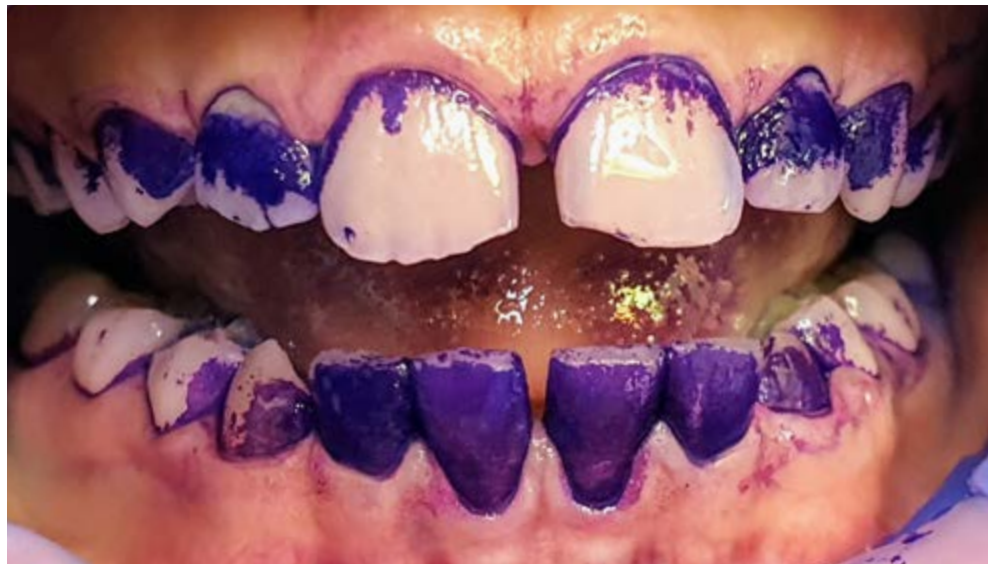PATIENT FEEDBACK

“I FEEL SUPER CLEAN. I UNDERSTAND BETTER HOW TO BRUSH.”

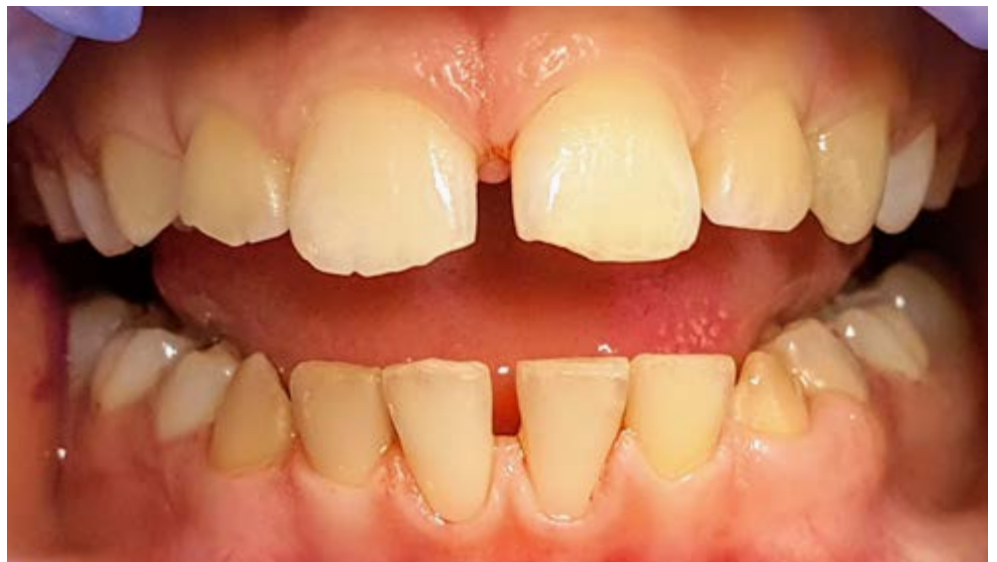BEFORE GBT



**AFTER
DISCLOSING**



AFTER GBT



CHILDREN AND GBT

CASE 15



CLINICIAN

Seo-yeon Han
Dental hygienist
South Korea

PATIENT INFORMATION

- ▶ Age 8, male.

BACKGROUND INFORMATION

- ▶ The patient has a habit of drinking cola since he was 1 year old. There was an overall black stain that appeared from infancy. Oral health had not improved even after the patient entered elementary school, so the parent decided to introduce him to an oral care program. Currently, the patient enjoys sweets.

CLINICAL FINDINGS

- ▶ General black stain. Checked the biofilm formed along the black stain around the gingival margin. In general, the anterior region was not self-managed any better than the posterior region.

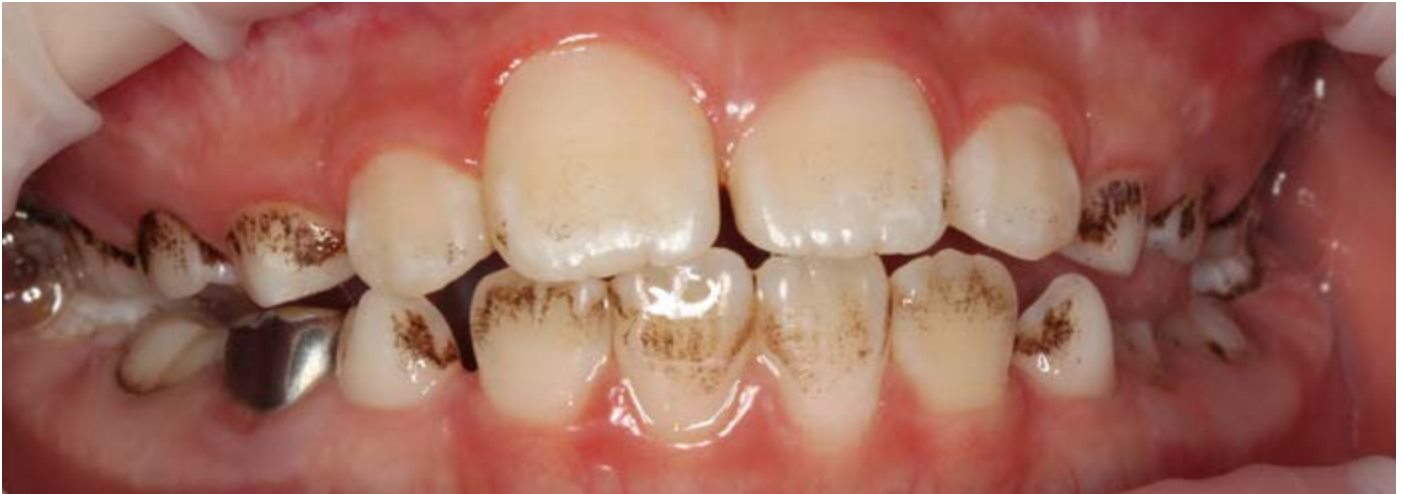TREATMENT

- ▶ The patient was usually afraid of dental treatment and was less cooperative, so checked and explained all treatment processes with a mirror and proceeded with GBT. Depending on the overall stain and the patient's level of cooperation and condition, the procedure was divided into 2 sessions with an interval of one week. GBT protocol was conducted with a focus on improving patient motivation and self-management ability.

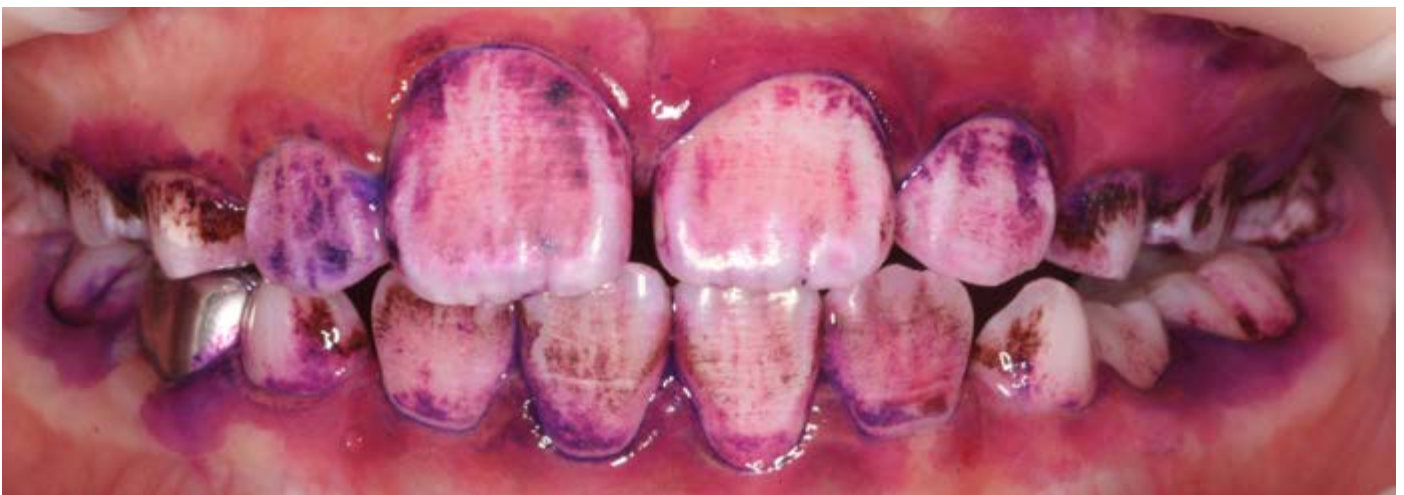PATIENT FEEDBACK

**“I THOUGHT DENTAL TREATMENT WOULD BE SCARY BUT
I WAS ABLE TO EXPERIENCE PAIN-FREE TREATMENT.”**

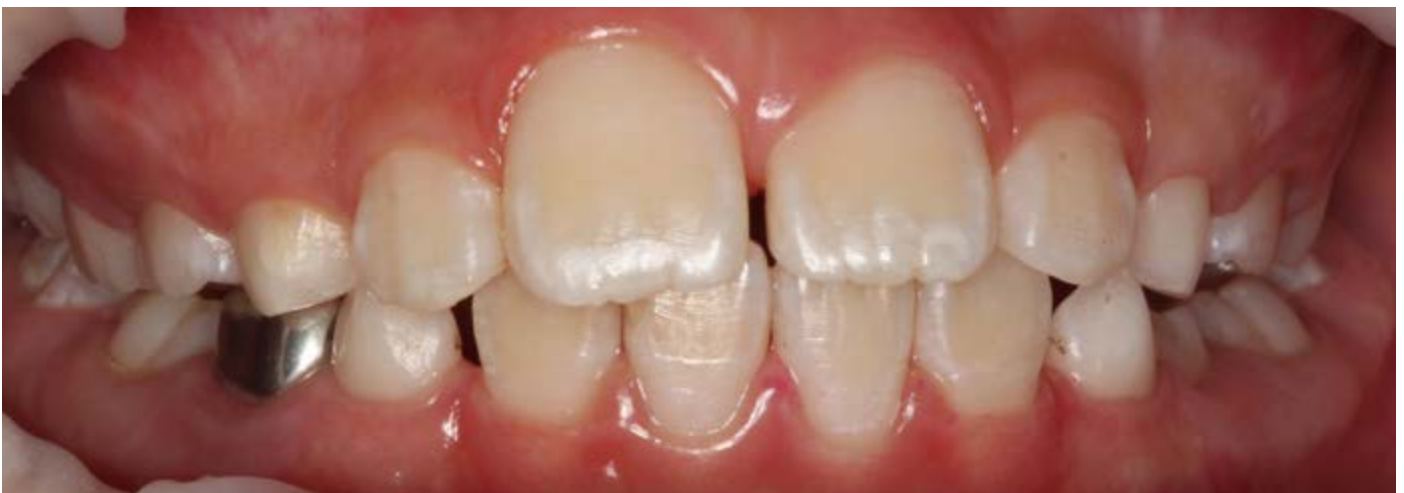BEFORE GBT



AFTER DISCLOSING



AFTER 1 WEEK



CHILDREN AND GBT

CASE 16



CLINICIAN

Andrii Voroshylov
Dental hygienist
Ukraine

PATIENT INFORMATION

- ▶ Age 15, male.

BACKGROUND INFORMATION

- ▶ First visit to dental hygienist, never been before. High-sugar diet.

CLINICAL FINDINGS

- ▶ Very poor oral hygiene, large amounts of biofilm in both jaws, calculus in frontal part in lower jaw, no interdental hygiene, formation of acidic biofilm.

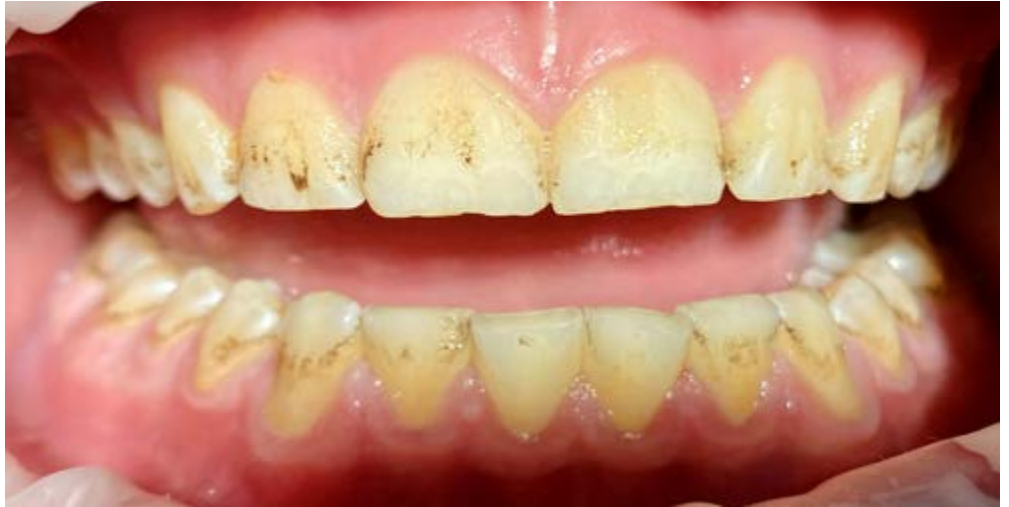TREATMENT

- ▶ Plaque removed with AIRFLOW® Prophylaxis Master using AIRFLOW® PLUS Powder. During check, all the demineralized areas could be seen clearly. The patient was advised to continue using a toothpaste twice per day and apply a remineralizing agent (GC Tooth Mousse Plus) after brushing.

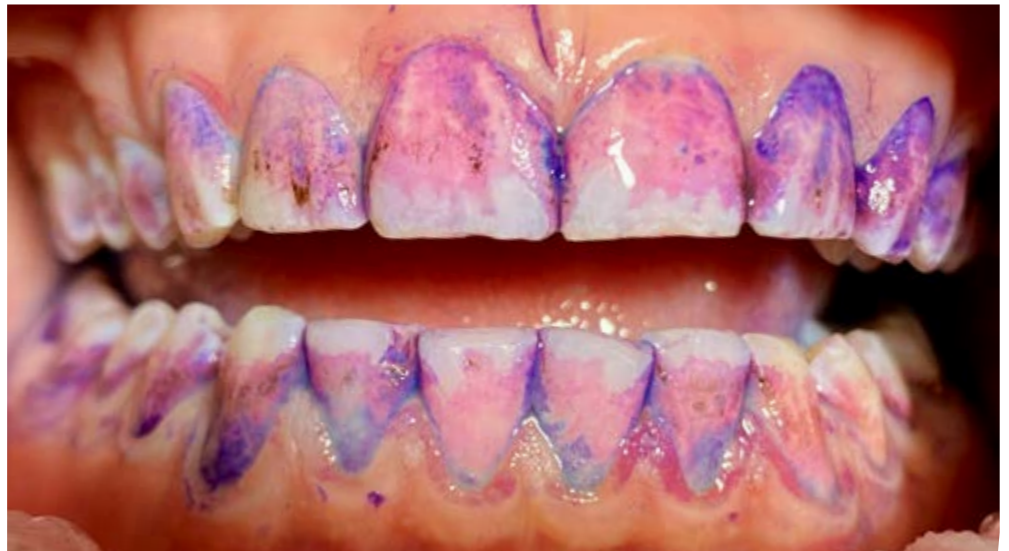PATIENT FEEDBACK

“I LIKE IT, IT IS QUICK, THERE IS NO PAIN. I WILL TRY BETTER TO BRUSH MY TEETH AT HOME IN THE MORNING AND EVENING.”

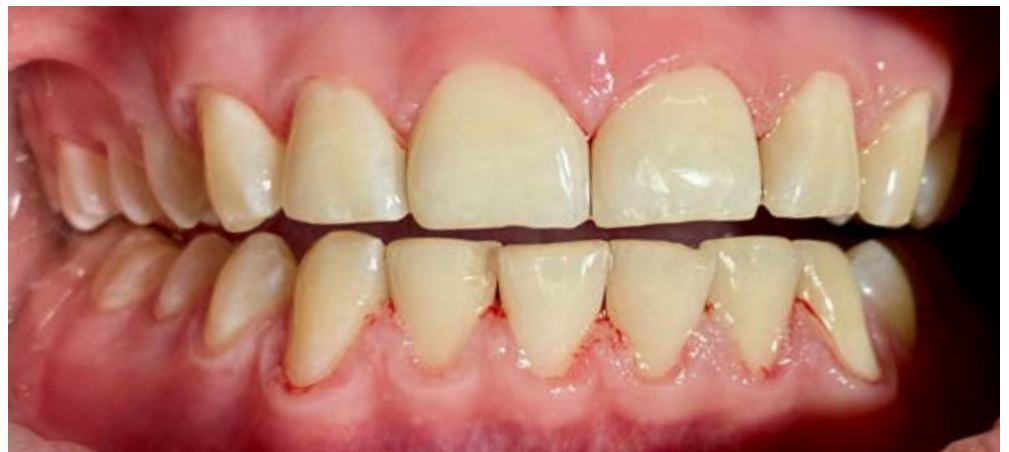BEFORE GBT



AFTER DISCLOSING



AFTER GBT



CHILDREN AND GBT

CASE 17



CLINICIAN

Lauren Smith Woodel
Dental hygienist
United States

PATIENT INFORMATION

- ▶ Age 12, male.

BACKGROUND INFORMATION

- ▶ Patient drinks mostly water, occasional soda, juice. Patient breathes mostly through the mouth at night. Asperger's, high functioning. Pre Diabetic. Vitamin D deficiency. No medications. Patient states that he brushes 0-2 times per day with a manual toothbrush. He is a not a highly motivated patient.

CLINICAL FINDINGS

- ▶ Patient has generalized moderate plaque at the gumline, most of the enamel surfaces and interdental spaces, generalized gingivitis with rolled, bulbous gingiva.

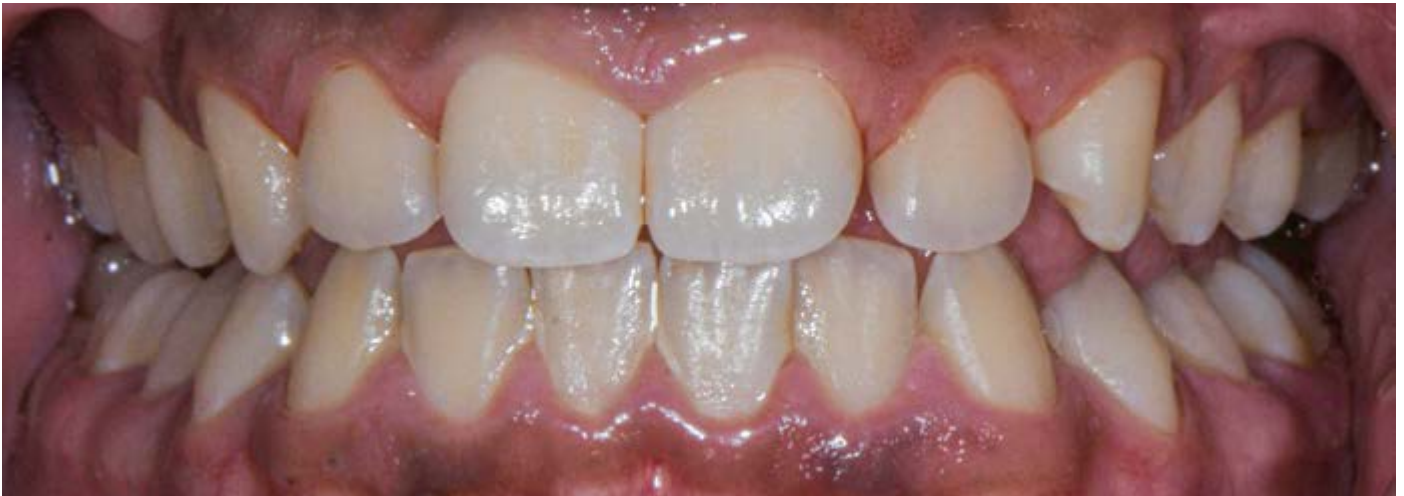TREATMENT

- ▶ Patient pre-rinsed with Ora Care mouthwash for 60 seconds before application of GC Tri Plaque ID. We removed the plaque and debris using the AIRFLOW® Master unit utilized AIRFLOW® PLUS Powder.

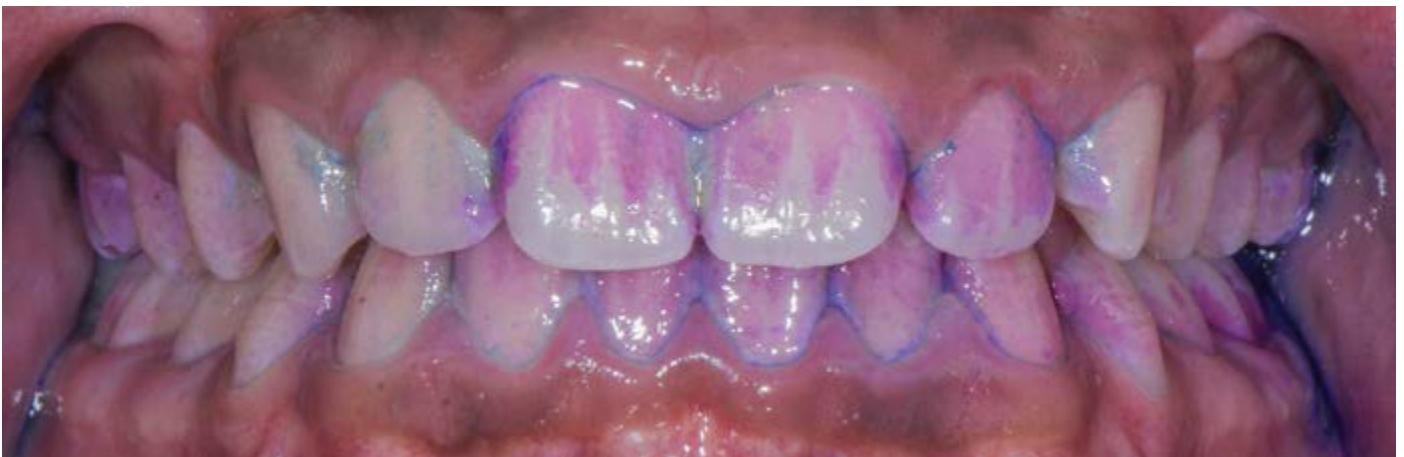PATIENT FEEDBACK

"I AM HAPPY!"

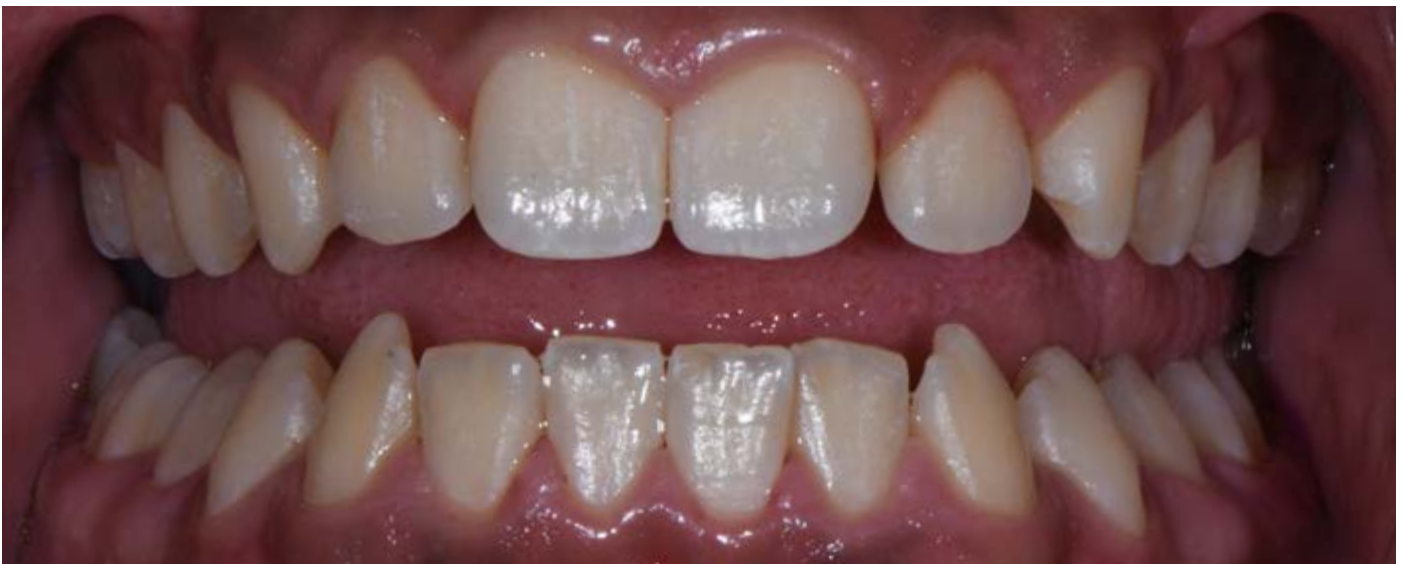BEFORE GBT



AFTER DISCLOSING



AFTER GBT



CHILDREN AND GBT

CASE 18



CLINICIAN

Ney Acurcio Cruz
Dental hygienist
Brazil

PATIENT INFORMATION

- ▶ Age 5, male.

BACKGROUND INFORMATION

- ▶ The patient has a low sugar intake. Need of prophylaxis with fluor application.

CLINICAL FINDINGS

- ▶ Preventive treatment.

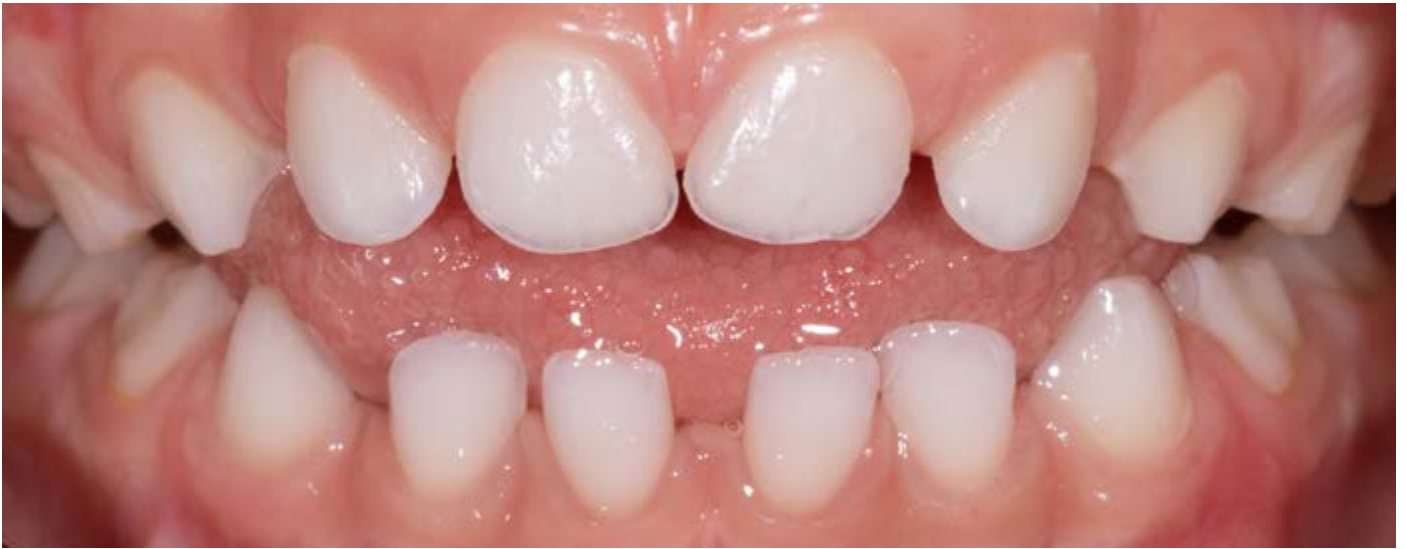TREATMENT

- ▶ GBT was performed with emphasis on patient motivation and home teeth cleaning education.

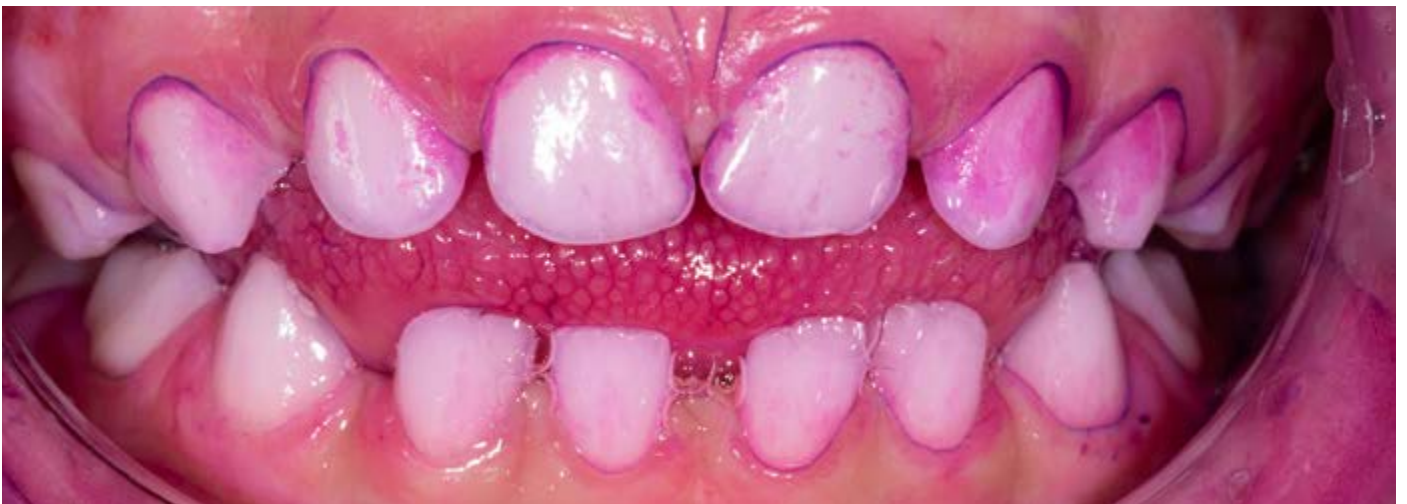PATIENT FEEDBACK

“WOW, IT WAS FAST AND PAINLESS!!! I’M NOT AFRAID OF THE DENTIST ANYMORE!”

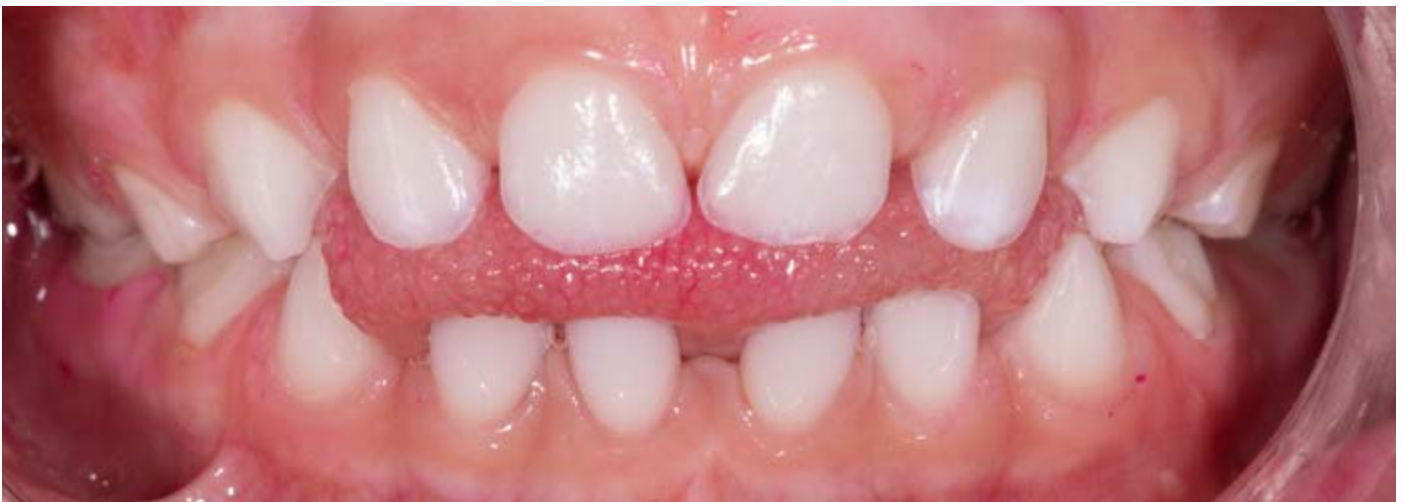BEFORE GBT



AFTER DISCLOSING



AFTER GBT



CHILDREN AND GBT

CASE 19



CLINICIAN

Henrietta Vass
Dental hygienist
Hungary

PATIENT INFORMATION

- ▶ Age 8, female.

BACKGROUND INFORMATION

- ▶ Patient's first prophylaxis visit. She regularly takes medication for epilepsy. That medication is also a cause for altered oral bacterial flora. Patient brushes her teeth twice a day with electronic toothbrush. No relevant habits

CLINICAL FINDINGS

- ▶ Visible biofilm present on teeth and on tongue. Supragingival calculus present. Minimal BOP+.

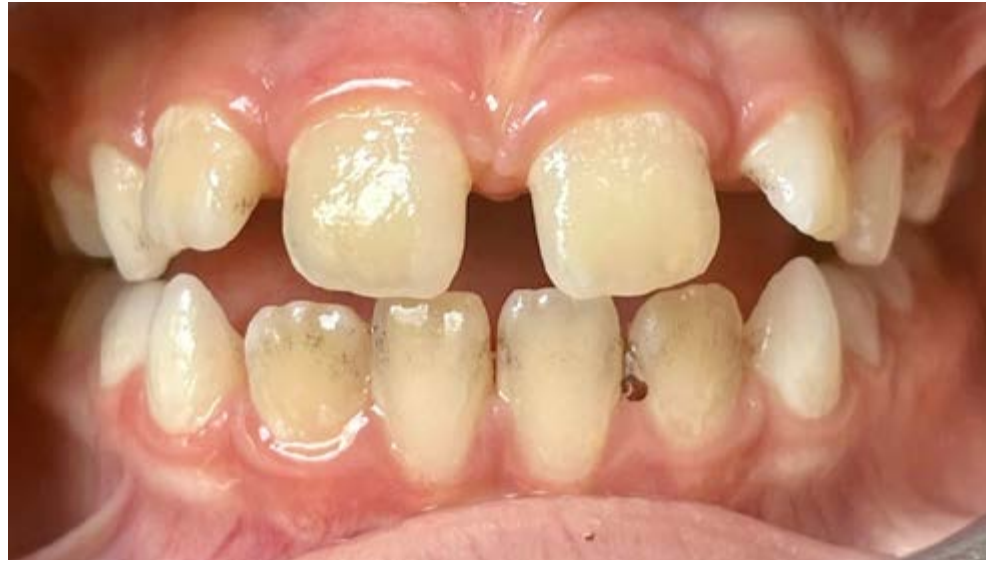TREATMENT

- ▶ After discussion with her regular GP, Guided Biofilm Therapy sessions started weekly for 1 month; using AIRFLOW® PLUS Powder and PIEZON® PS Instrument. Since then, regular monthly recalls. Bacterial flora, plaque index and overall result show significant improvement.

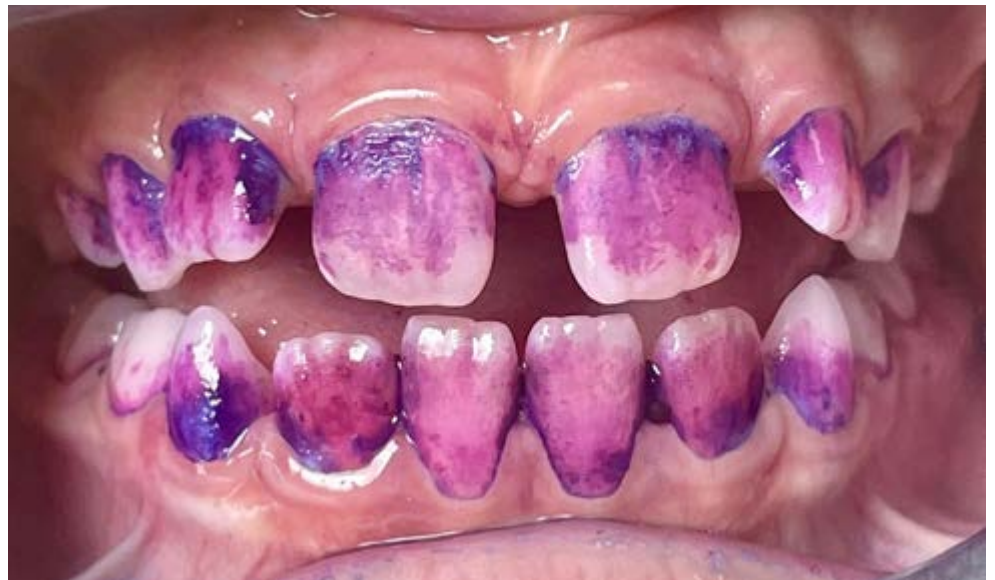PATIENT FEEDBACK

"I AM NOT AFRAID TO GO TO THE DENTAL PRACTICE. THE TREATMENT TICKLES A BIT BUT IS NEVER PAINFUL."

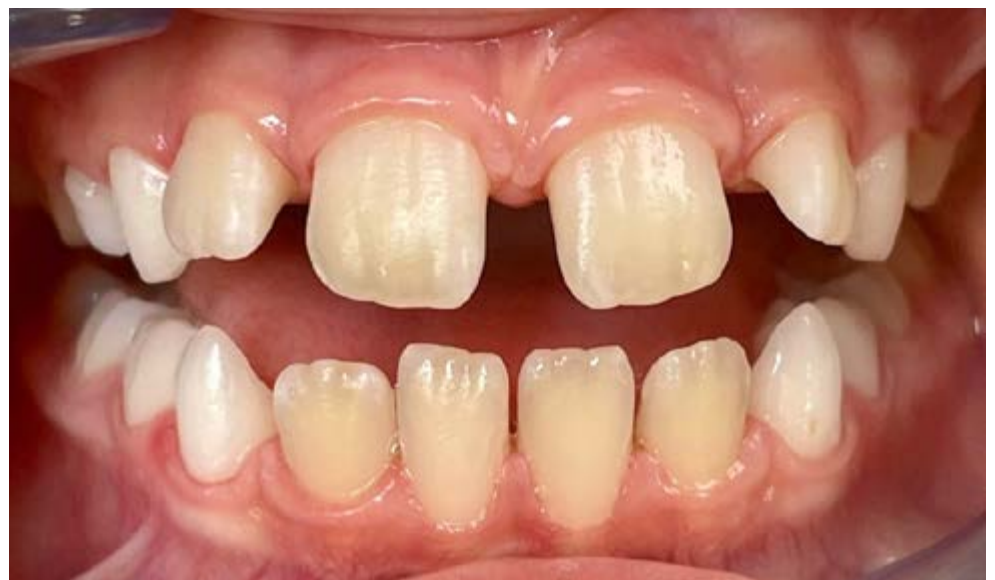BEFORE GBT



**AFTER
DISCLOSING**



AFTER GBT



IMPLANTS AND GBT

CASE 20



CLINICIAN

Andrea Sales do Prado Godoy
Endodontist, Prosthodontic, Dental Aesthetics
Brazil

PATIENT INFORMATION

► Age 58, male.

BACKGROUND INFORMATION

► The patient had an implant due to tooth extraction with endodontic and periodontal involvement. Patient is motivated and willing to have the most conservative treatment possible. No relevant eating habits but patient with high level of bruxism.

CLINICAL FINDINGS

► Patient with peri-implantitis. This motivated us to do a GBT (conservative treatment) through the PERIOFLOW® technique in an attempt to maintain the compromised element.

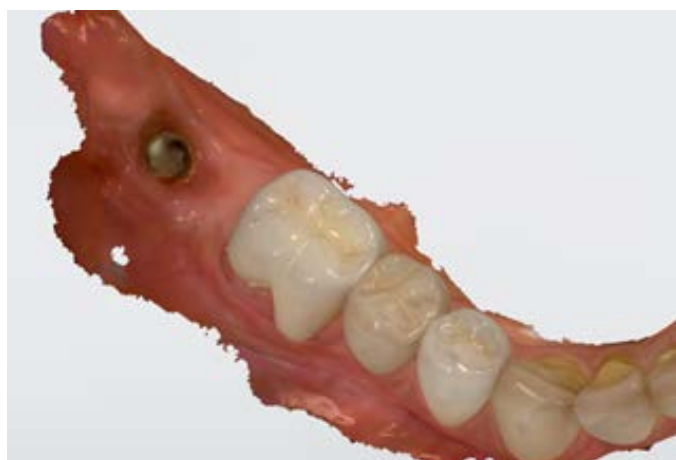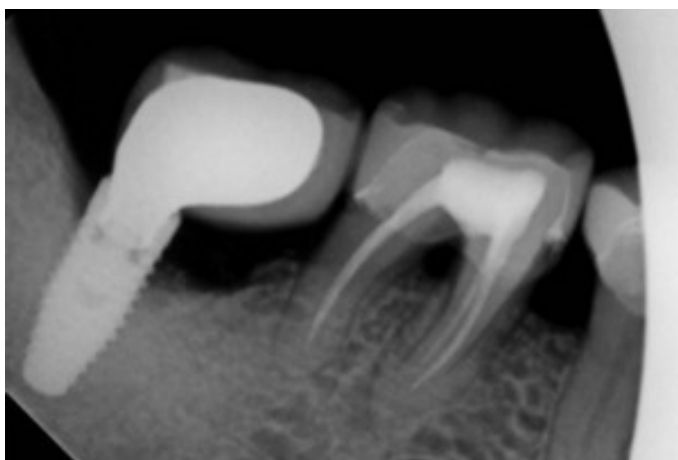TREATMENT

► Detailed assessment with radiographs was done. The GBT protocol was initiated, starting with the disclosing biofilm followed by the sub- and supragingival AIRFLOW® jet at a maximum of 4mm. In the sequence we introduced the PERIOFLOW® up to power 8 and finished with a new AIRFLOW® jet. Post 30 days, there was an improvement in bone growth.

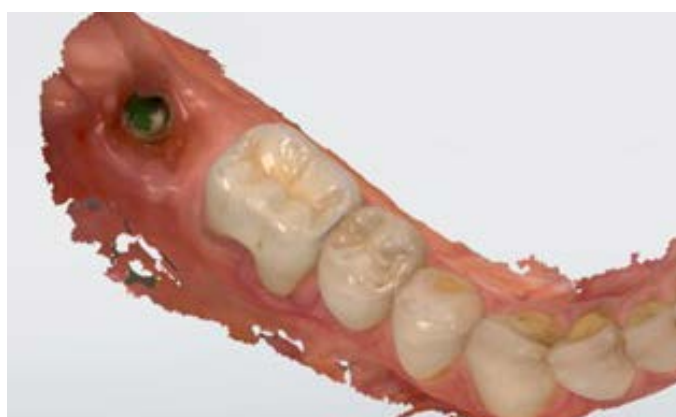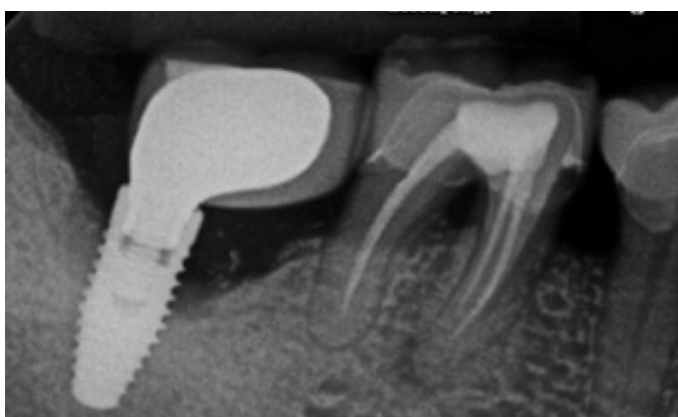PATIENT FEEDBACK

**“I AM EXTREMELY HAPPY WITH THE CONSERVATIVE APPROACH
IN ORDER TO SAVE MY IMPLANT.”**

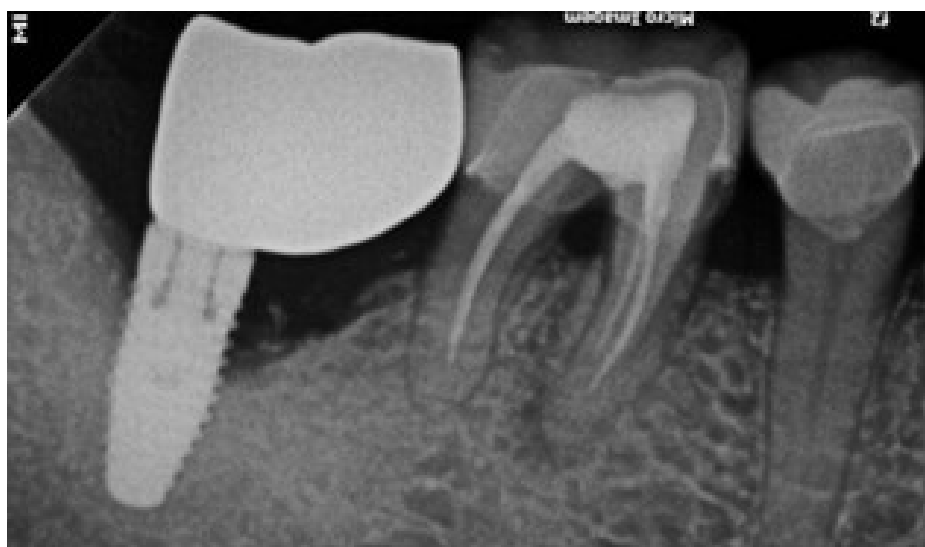BEFORE GBT



AFTER GBT



30 DAYS AFTER GBT



IMPLANTS AND GBT

CASE 21



CLINICIAN

Dr. Augusto Andre Baptista
Exclusive Practice Oral Surgery,
Periodontology and aesthetic dentistry
Luxembourg

PATIENT INFORMATION

- ▶ Age 55, male.

BACKGROUND INFORMATION

- ▶ Bad initial oral hygiene with inflammations, history of aggressive periodontitis, young toothless patient, treated with a double ALL on 6. Big former smoker.

CLINICAL FINDINGS

- ▶ Pain, mucositis, halitosis.

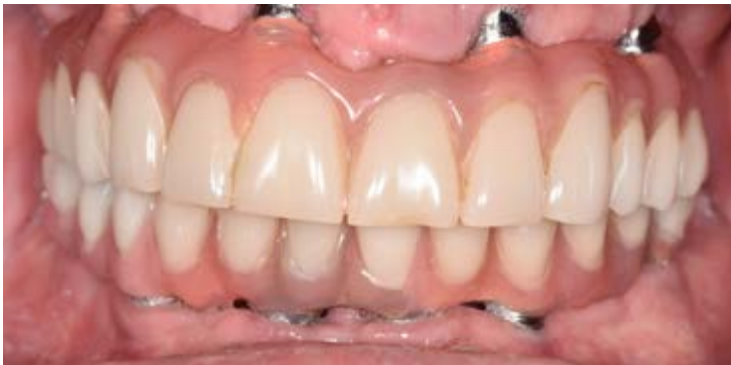TREATMENT

- ▶ Global oral hygiene teaching session and periodontal probing, small periodontal maintenance every 6 months without removing the prosthesis, cleaning and sanitation without anesthesia. Major maintenance session with removal of the prosthesis is scheduled after every 3 minor maintenance sessions. GBT session starts with probing, disclosing, cleaning with AIRFLOW® PLUS Powder with AIRFLOW MAX® handpiece then with PERIOFLOW® handpiece for the abutments, the biological width around implants and all the narrow areas with difficult access. Recall every 6 months: Good oral hygiene from the patient and suppression of symptoms.

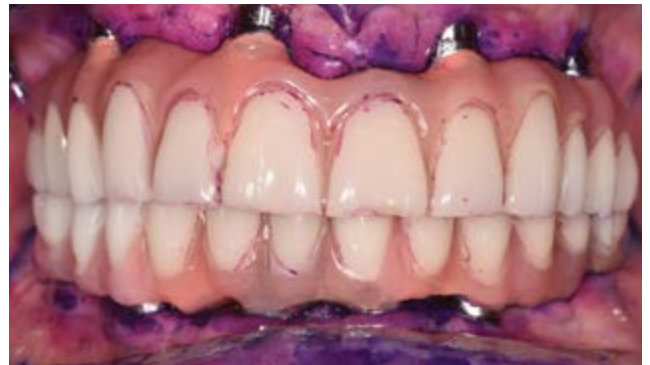PATIENT FEEDBACK

“I HIGHLY RECOMMEND THIS TREATMENT BY THE GBT PROTOCOL TO ALL PATIENTS WITH IMPLANTS, NO PAIN FEELING, VERY COMFORTABLE AND PERFECT DEEP CLEANING !”

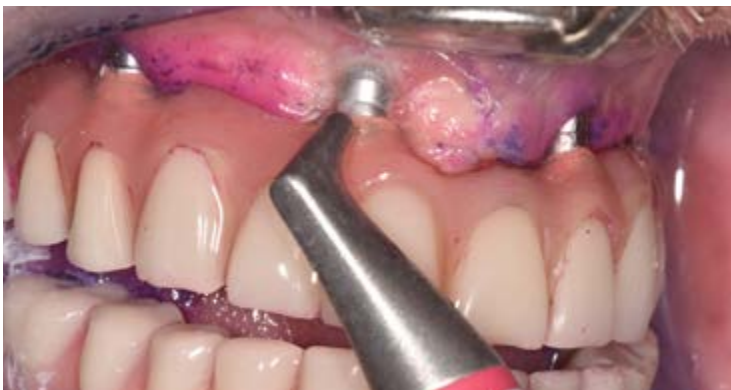BEFORE GBT



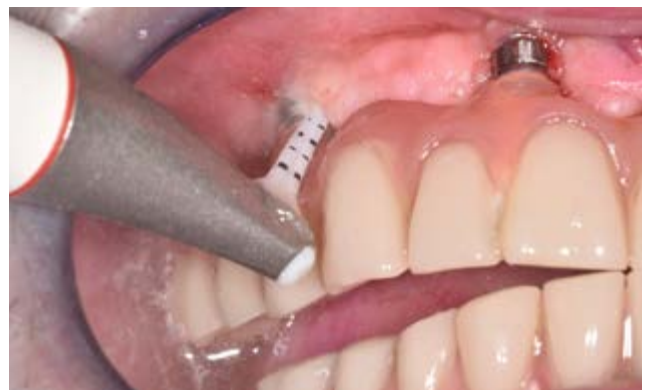AFTER DISCLOSING



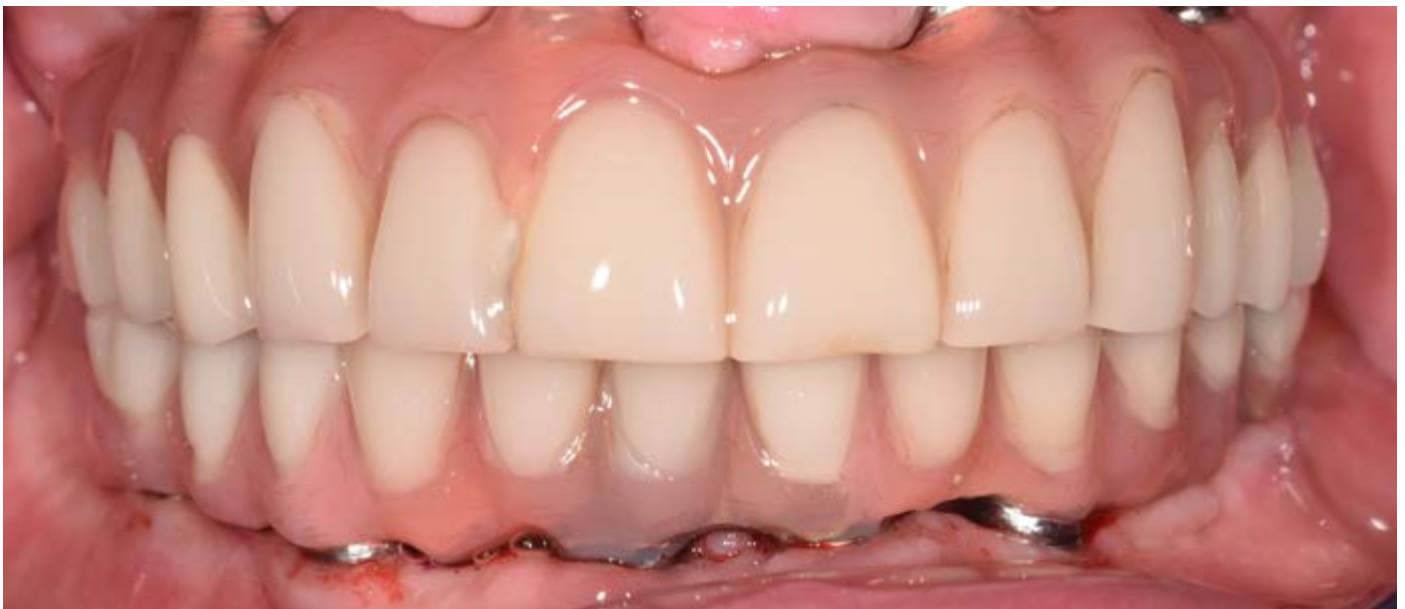AFTER AIRFLOW®



AFTER PERIOFLOW®



AFTER GBT



IMPLANTS AND GBT

CASE 22



CLINICIAN

Dr. Jacques Hassid
Periodontist and Implantologist
France

PATIENT INFORMATION

- ▶ Age 54, female.

BACKGROUND INFORMATION

- ▶ By the age of 30, this patient had stage 3, grade C periodontitis (formerly called aggressive periodontitis). Several periodontal treatments (non-surgical and surgical periodontal debridement and then periodontal maintenance) have been performed for several years. Despite regular follow-up, it was decided to extract all the maxillary teeth and keep some mandibular teeth, then to carry out an implant treatment and a removable prosthesis on the mandible. Non-smoker, no health problems.

CLINICAL FINDINGS

- ▶ On clinical examination, the patient does not present periodontal pockets, no signs of peri-implantitis but superficial inflammation of the gingival tissues due to tartaric deposits.

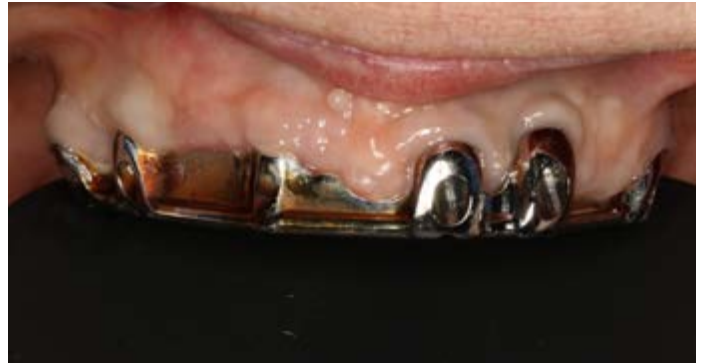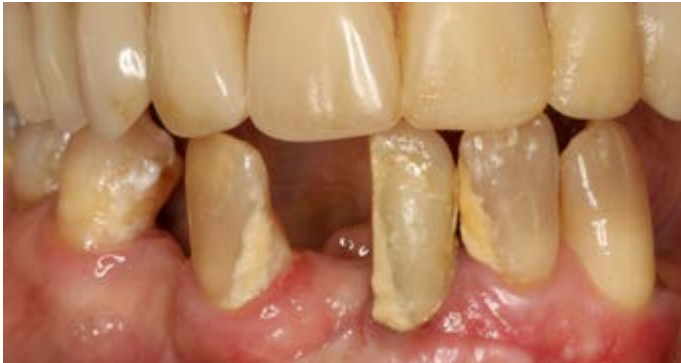TREATMENT

- ▶ After a complete periodontal examination, the GBT peri-implant maintenance session takes place as follows: used a disclosing agent, recommendations for oral hygiene. AIRFLOW® MAX handpiece with AIRFLOW® PLUS Powder, PERIOFLOW® and PIEZON® PS Instrument for cleaning tartaric concretions. Control reminder scheduled at 4 months.

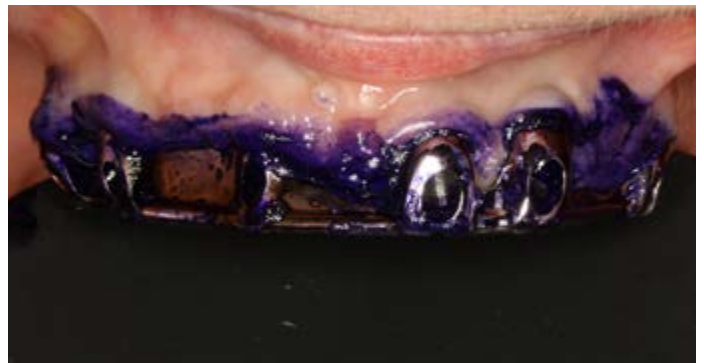
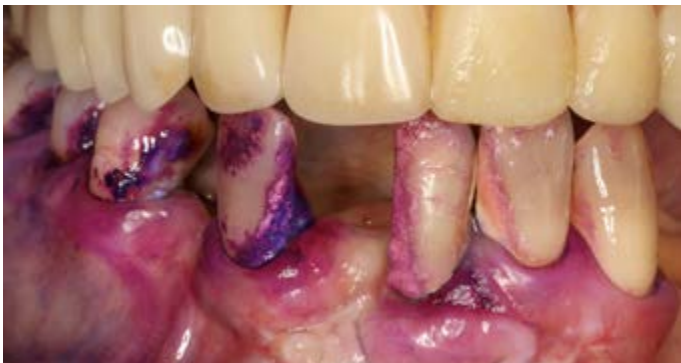PATIENT FEEDBACK

“PAINLESS TREATMENT, A REAL FEELING OF HAVING A HEALTHY AND CLEAN MOUTH”

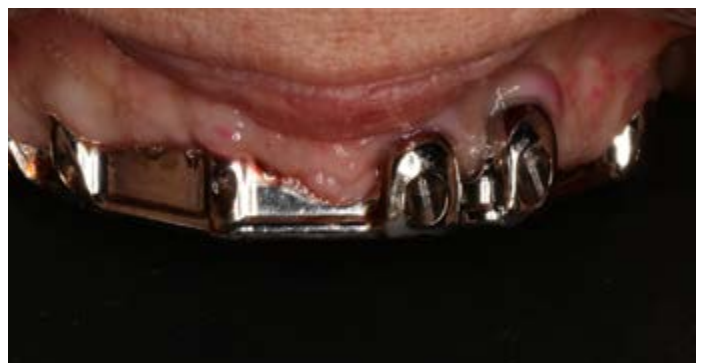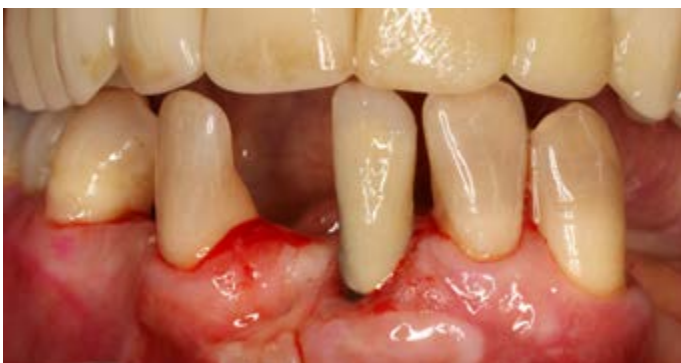BEFORE GBT



AFTER DISCLOSING



AFTER GBT



IMPLANTS AND GBT

CASE 23



CLINICIAN

Lauren Smith Woodel
Dental hygienist
USA

PATIENT INFORMATION

- ▶ Age 35, male.

BACKGROUND INFORMATION

- ▶ Patient drinks energy drinks and Coke Classic daily, doesn't "enjoy" drinking water. Patient snores, breathes mostly through the mouth, undiagnosed sleep apnea. Health history includes asthma, daily Symbicort, Albuterol as needed. Patient also has seasonal allergies. Patient states that he brushes 1-2 times per day with a Sonicare toothbrush. He does not use dental floss, but uses a Waterpik every morning. He is a moderately motivated patient with caries. 3-month recall.

CLINICAL FINDINGS

- ▶ Patient has generalized old, sticky plaque at the gumline of the natural teeth, generalized gingivitis with rolled, bulbous facial gingiva. The Zirconia All on Four has generalized light plaque, heavier on the upper right, debris between the prosthesis and boney ridge. There are no exposed implant threads visually or radiographically. All periodontal pockets were <5mm, no exudate, light BOP.

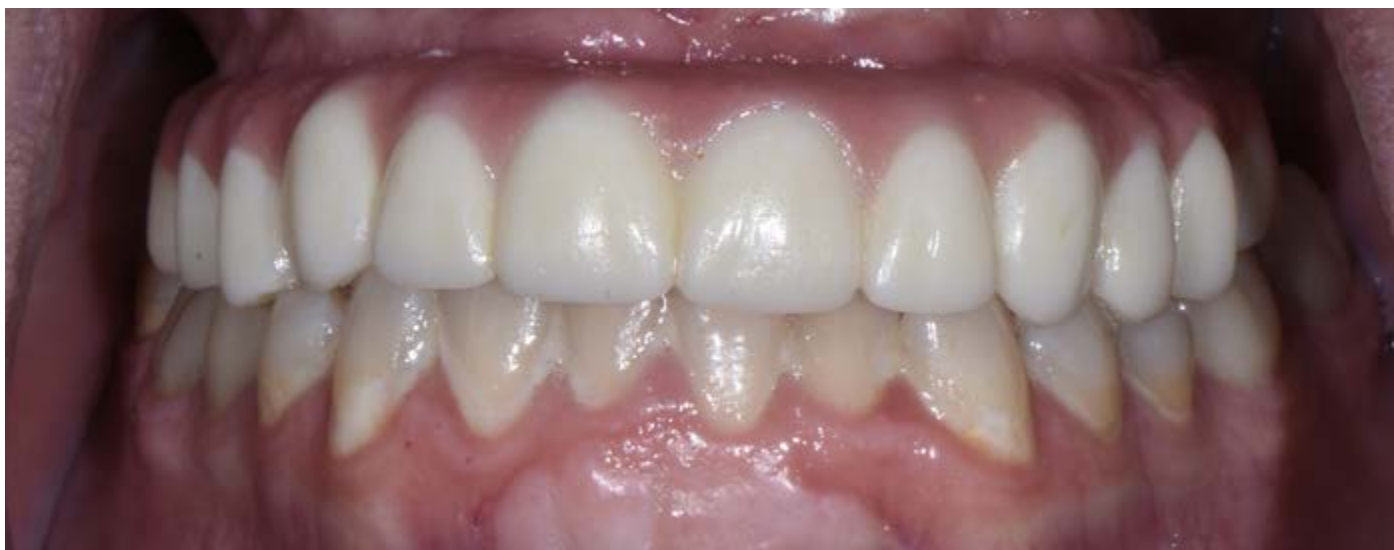TREATMENT

- ▶ Patient pre-rinsed with Ora Care mouthwash for 60 seconds before application of GC Tri Plaque ID Gel. We removed the biofilm with AIRFLOW® PLUS Powder and hand scaled any remaining hard deposit which was inaccessible for ultrasonics.

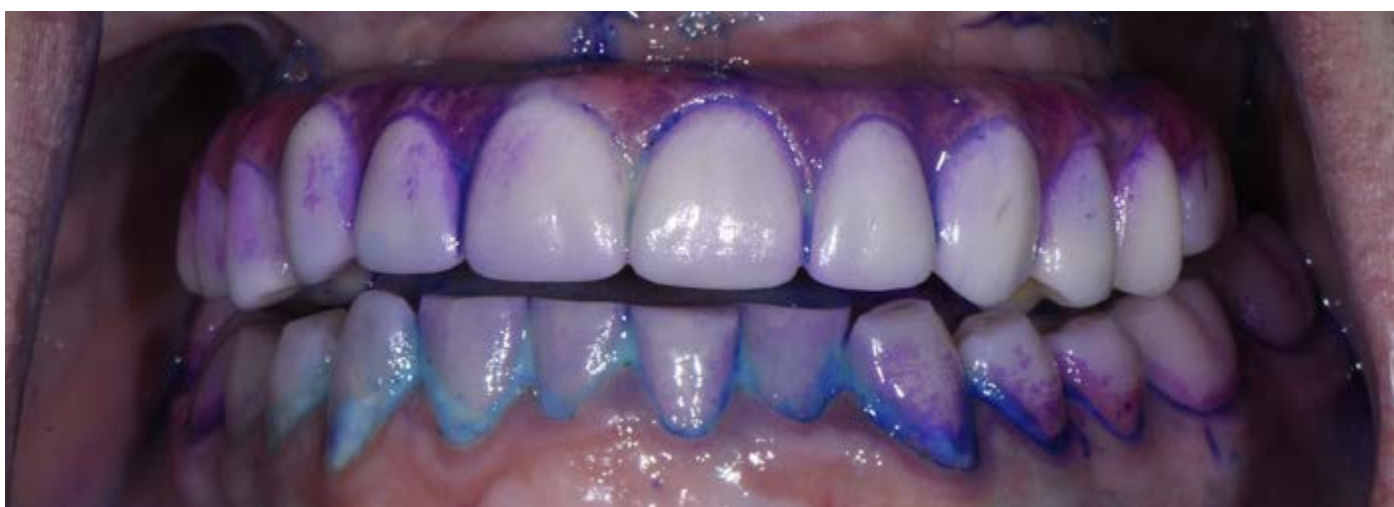PATIENT FEEDBACK

"I ALWAYS FEEL BETTER AFTER BEING HERE, I FEEL CLEAN AND FRESH AND MY TEETH LOOK WHITER."

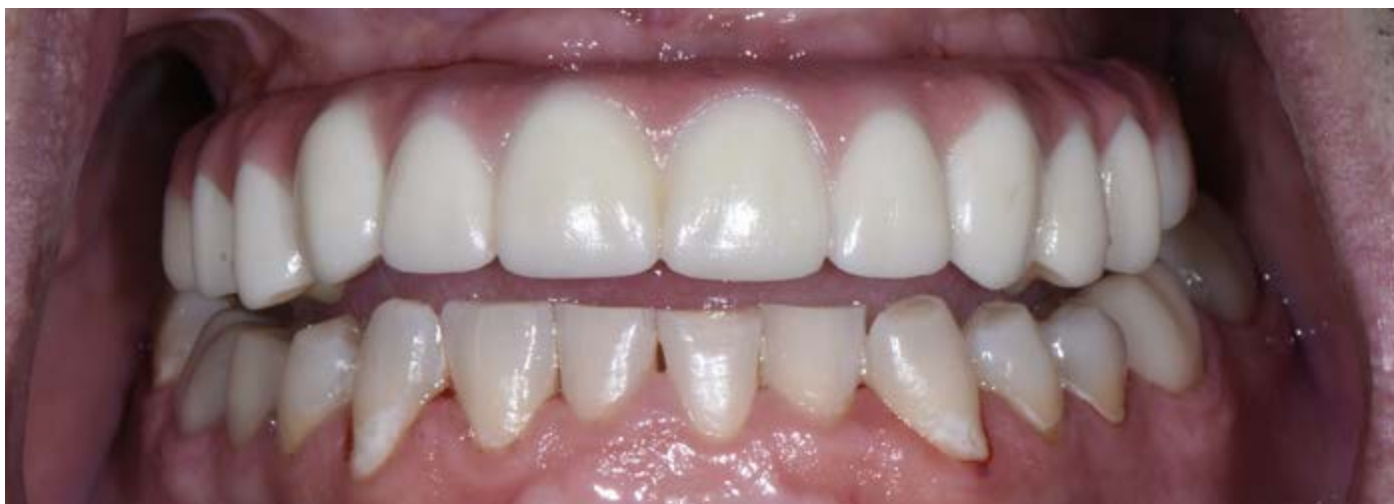BEFORE GBT



AFTER DISCLOSING



AFTER GBT



IMPLANTS AND GBT

CASE 24



CLINICIAN

Pascale Hemelrijk
Dental hygienist
Netherlands

PATIENT INFORMATION

- ▶ Age 73, male.

BACKGROUND INFORMATION

- ▶ He lost his teeth at the age of thirty because of caries and bad financial situation. The implants were placed due to poorly fitting prosthesis 15 years ago. Last visit to dentist and dental hygienist was two years ago due to a range of various illnesses. No smoking, under and upper jaw prosthesis held by implants. No oral hygiene habits.

CLINICAL FINDINGS

- ▶ Implants in upper and lower jaw prosthesis. The patient presented a peri-implant mucositis with a pocket depth of 4mm and BOP+ (bleeding on probing). Generalized sub- and supragingival plaque, stains and tartar. Poor oral hygiene.

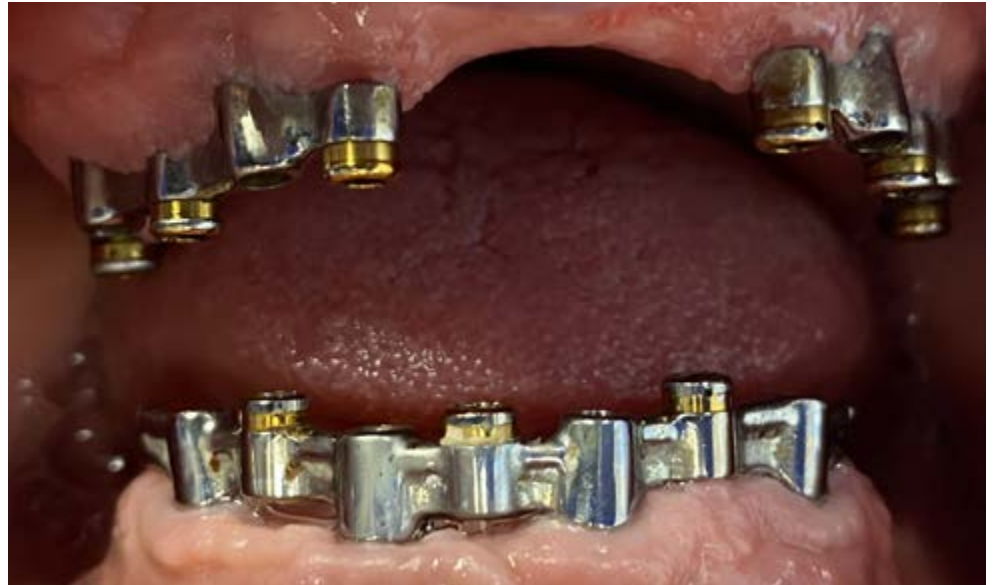
TREATMENT

- ▶ Upon disclosing, biofilm was eliminated from the prosthesis and the implants supra- and subgingivally with the AIRFLOW® MAX and AIRFLOW® PLUS Powder. Use of the PIEZON® PI Instrument on generalized supra- and subgingival tartar on the mandibular implants. Despite the blood thinners taken by the patient, the bleeding during the non-invasive GBT treatment was low in contrast to traditional treatment.

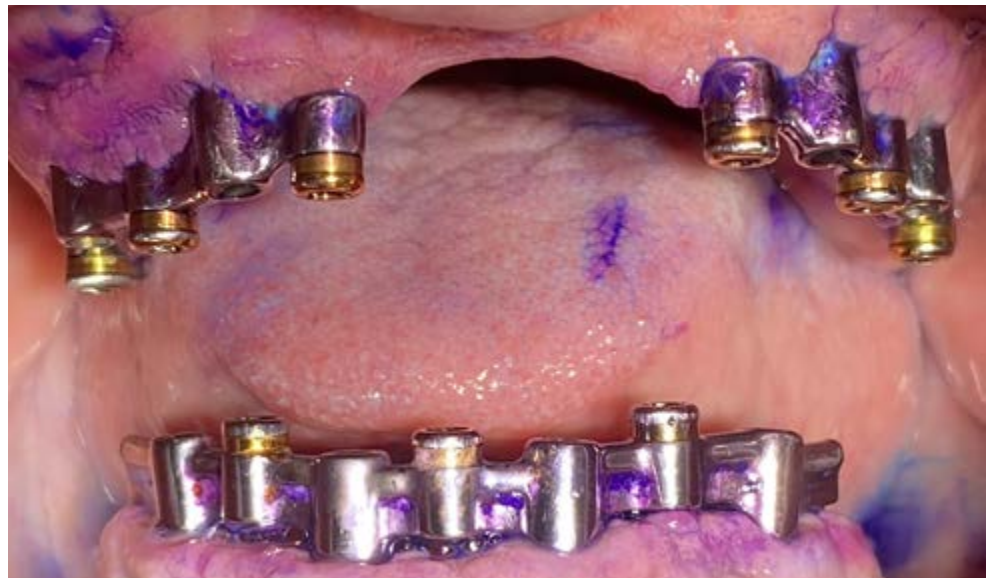PATIENT FEEDBACK

“I AM SO HAPPY, I DID NOT FEEL ANYTHING. MY IMPLANTS ARE SHINING AGAIN AND LOOK SO CLEAN. I AM COMING BACK IN 3 MONTHS.”

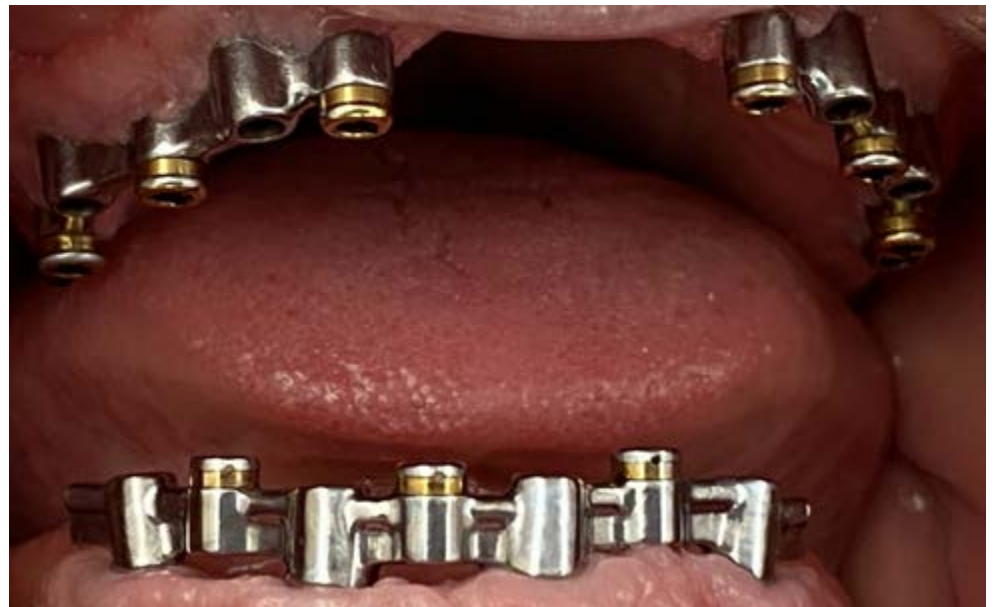BEFORE GBT



**AFTER
DISCLOSING**



AFTER GBT



IMPLANTS AND GBT

CASE 25



CLINICIAN

Roxanne Rigter
Dental hygienist
Netherlands

PATIENT INFORMATION

- ▶ Age 77, female.

BACKGROUND INFORMATION

- ▶ Implant 23 has been removed on 03-04-22 due to peri-implantitis. Poor oral health. No significant habits.

CLINICAL FINDINGS

- ▶ 4 to 6 mm peri-implant sulcus depth
The mandible pockets 4-5mm, bleeding on probing (BOP)

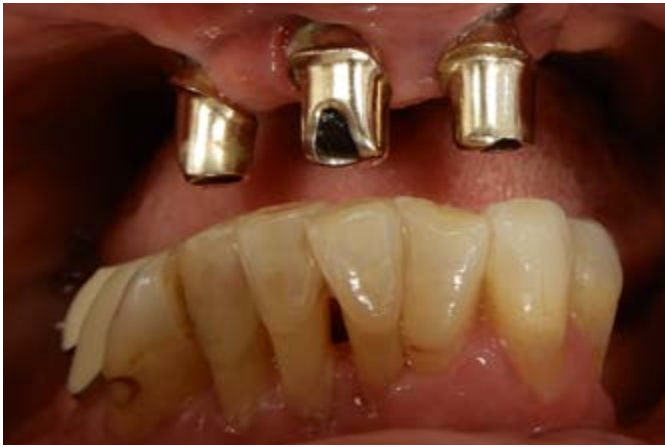TREATMENT

- ▶ Examination of the implants and the tooth surfaces in the lower jaw. Cleaning the implants and the tooth surfaces GBT. First disclosing the implants and the dental surfaces with EMS Biofilm Discloser. Patient motivated and instructions given. Using Airflow handpiece with AIRFLOW® PLUS Powder for the implants and tooth surfaces. Removed calculus in the mandibular using the PIEZON® handpiece and PIEZON® PS Instrument. Used PERIOFLOW® to clean the 4 to 6mm sulcus depth at the implants (GBT).

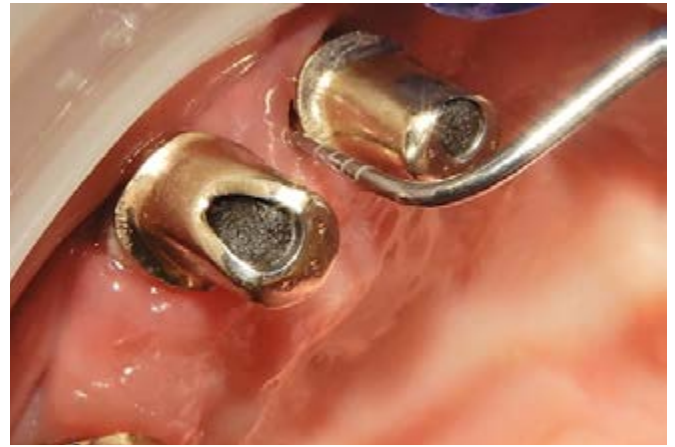PATIENT FEEDBACK

“FINE PAINLESS TREATMENT.”

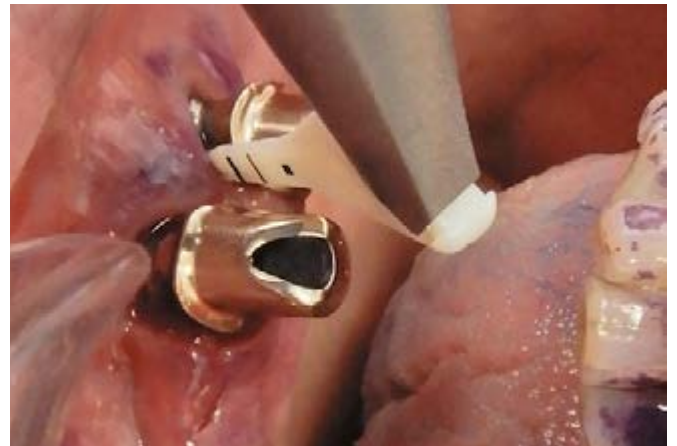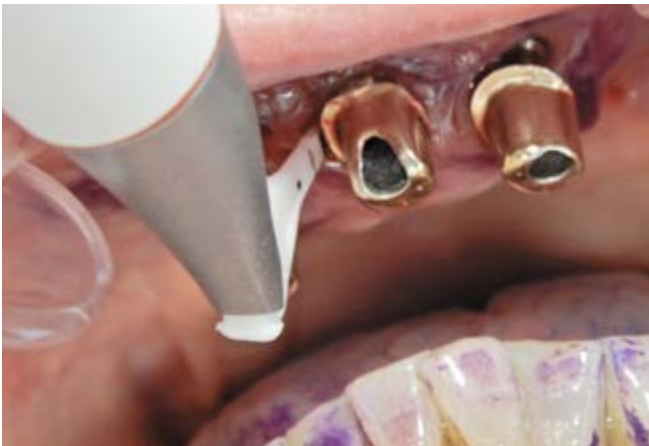BEFORE GBT



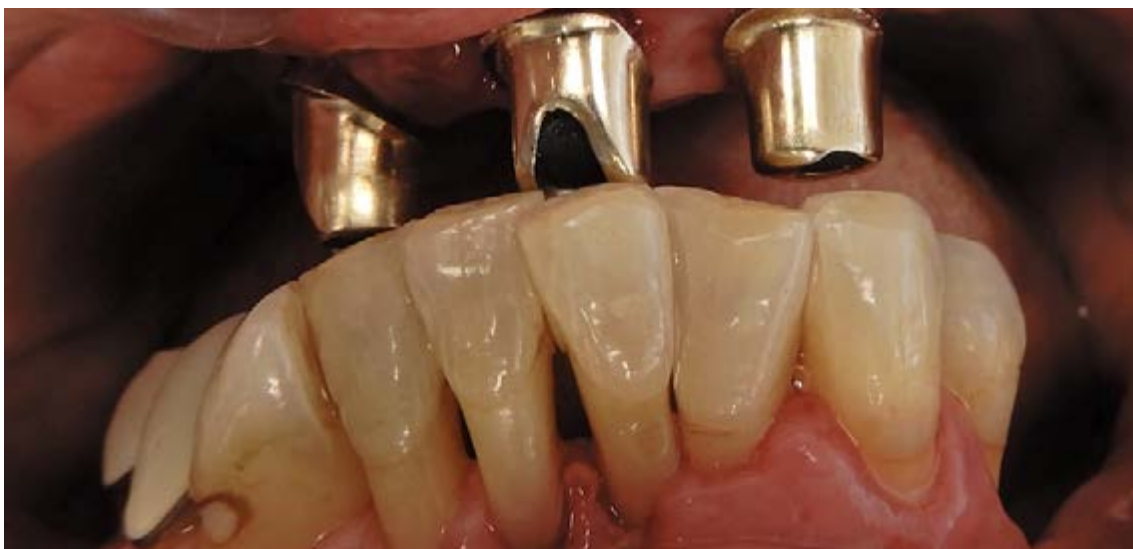PIEZON®



PERIOFLOW®



AFTER GBT



IMPLANTS AND GBT

CASE 26



CLINICIAN

Serim Cho
Dental hygienist
Korea

PATIENT INFORMATION

► Age 51, male.

BACKGROUND INFORMATION

► Medicated for diabetes in the past but stopped it after being completely cured. Self-care was poor. CC: chief compliant.

CLINICAL FINDINGS

► Loss of multiple teeth, implant prosthesis with inflammation overall, BOP + (bleeding on probing), sub- and supragingival calculus and halitosis issue.

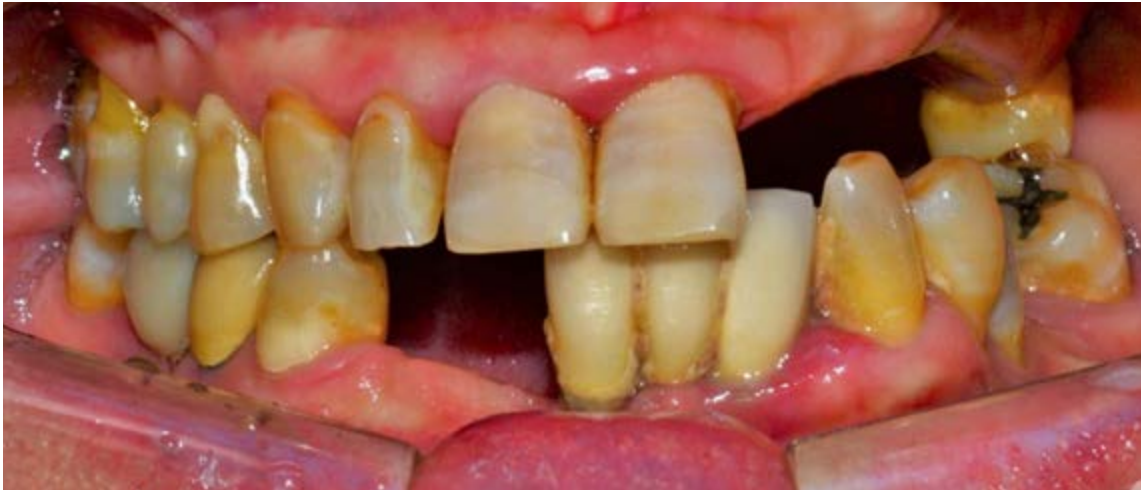TREATMENT

► To establish self-care, 4 sessions were performed in a weekly interval. On the first visit, the oral bacteria test, the progression of periodontal disease, and the use of interdental toothbrushes and mouthwash were explained. On the second visit after one week, introduced AIRFLOW® and PIEZON® and removed biofilm and stain using PIEZON® PS Instrument. After that, AIRFLOW® and periodontal treatment were combined in two maintenance sessions for the two following weeks..

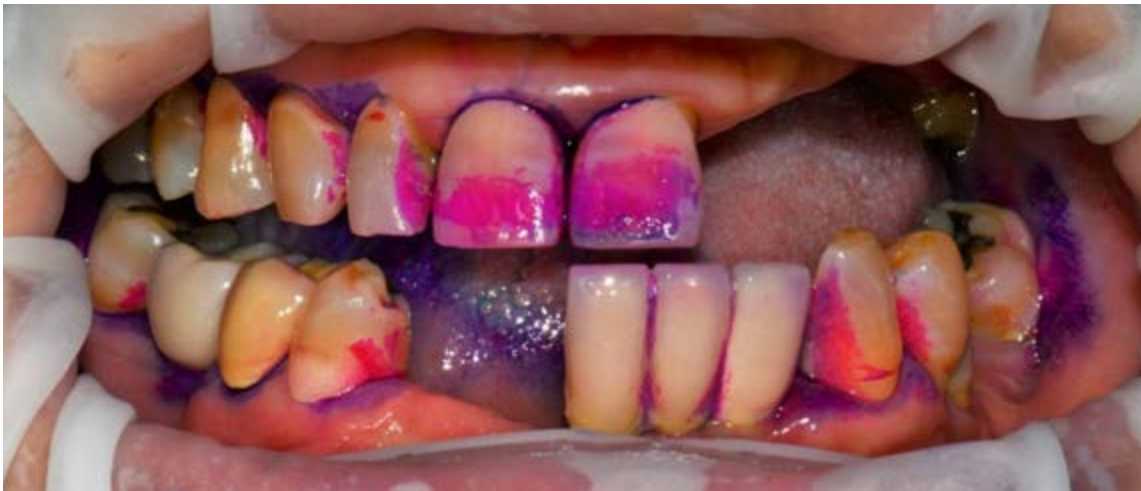PATIENT FEEDBACK

“PREVIOUSLY, IT WAS PAINFUL AND UNCOMFORTABLE EVERY TIME WHEN I RECEIVED SCALING OR PERIO TREATMENT, BUT GBT WAS COMFORTABLE. I HAVE LESS BAD BREATH, SO I’M CONFIDENT TO TALK. I’M LOOKING FORWARD TO THE FUTURE TREATMENT.”

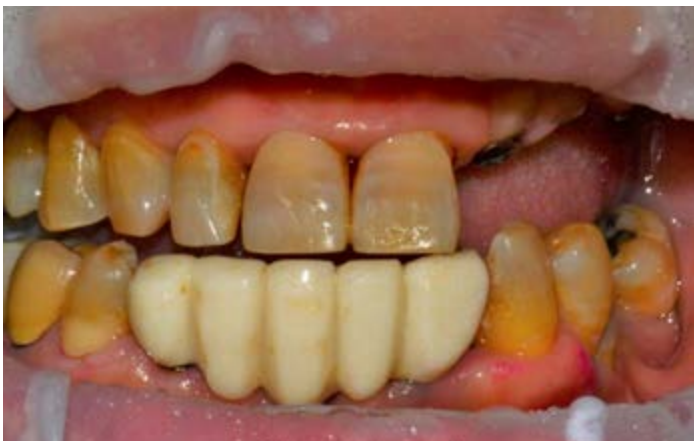BEFORE GBT



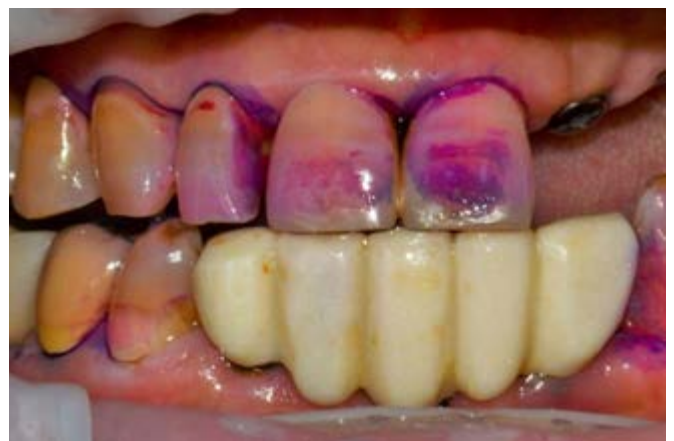AFTER DISCLOSING



AFTER GBT



2-WEEK RECALL



IMPLANTS AND GBT

CASE 27



CLINICIAN

Seonmi Park
Dental hygienist
Korea

PATIENT INFORMATION

▶ Age 65, female.

BACKGROUND INFORMATION

▶ Hyperlipidemia. #16 Implant after extraction. The patient was passive in recall only to treat relapse of periodontitis. But the frequency of periodontitis recurrence decreased through continuous co-therapy.

CLINICAL FINDINGS

▶ #16 Gingival crevicular fluid around implant +, BOP +, Biofilm ++.

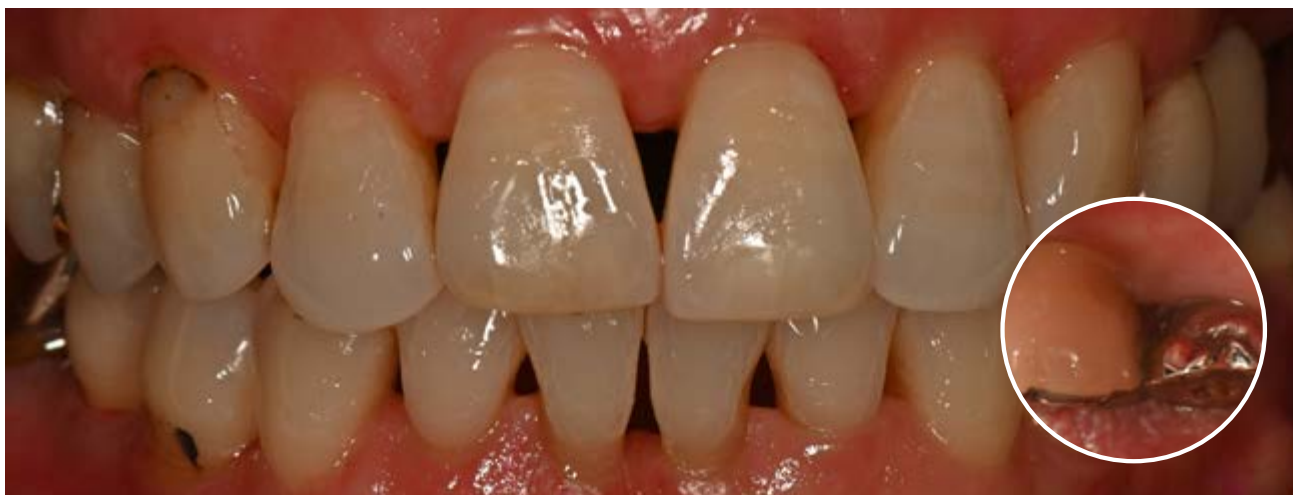TREATMENT

▶ Explained to the patient that disease progresses faster around implant areas than around natural teeth, and healing is also slow. To enforce motivation, checked the gingival crevicular fluid → checked the biofilm visually → Homecare training → GBT protocol → Application of fluoride varnish to prevent root caries.

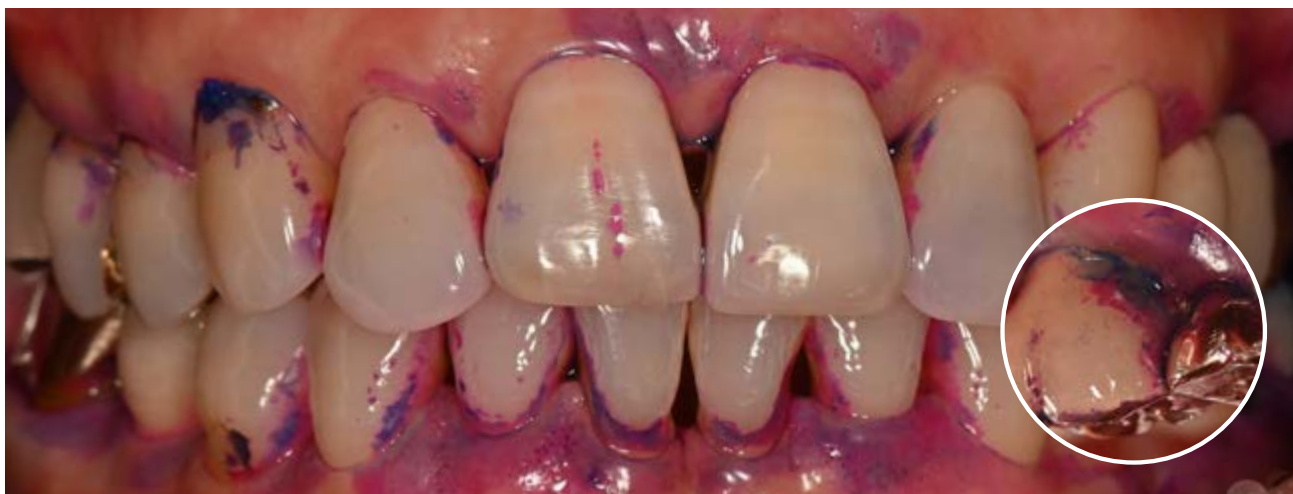PATIENT FEEDBACK

“THANKS, GBT PROTOCOL.”

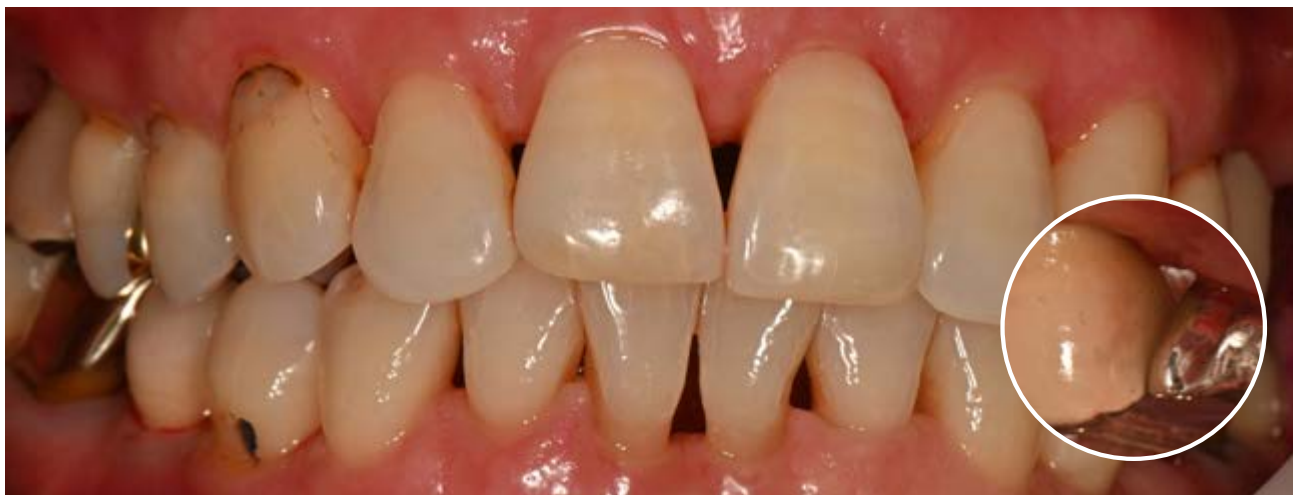BEFORE GBT



AFTER DISCLOSING



AFTER GBT



IMPLANTS AND GBT

CASE 28



CLINICIAN

Beverley Watson RDH,
Hygienist
UAE

PATIENT INFORMATION

► Age 49, male.

BACKGROUND INFORMATION

► Has a difficult prosthesis design attached to implants. Motivated to care for his bridge work and implants. Smoker.

CLINICAL FINDINGS

► Suppuration visible and bone loss after taking radiographs around #11,12,13. Upper right implants showed peri-implantitis.

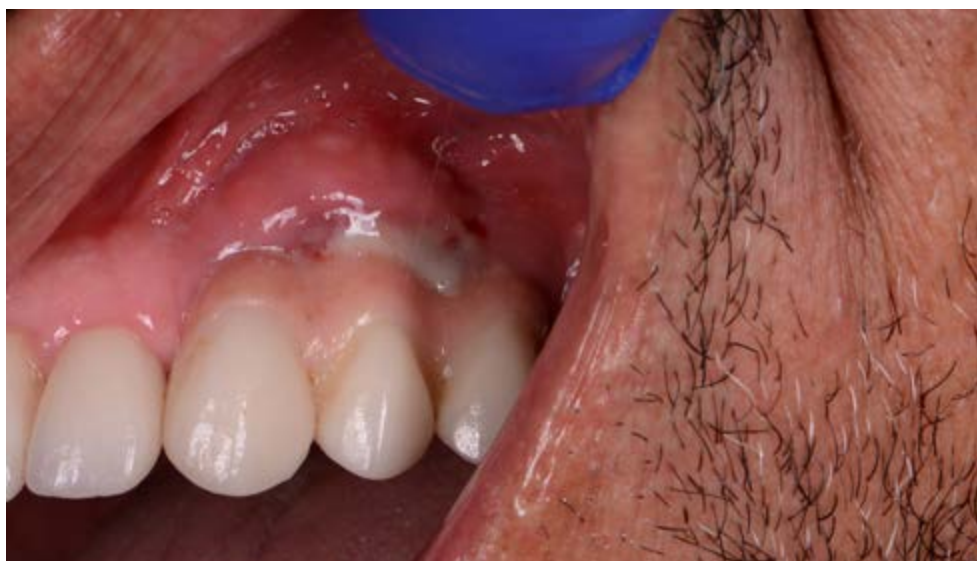TREATMENT

► AIRFLOW® MAX was used to remove biofilm followed by PIEZON® PS Instrument to remove calculus. No PERIOFLOW® at this appointment due to suppuration.

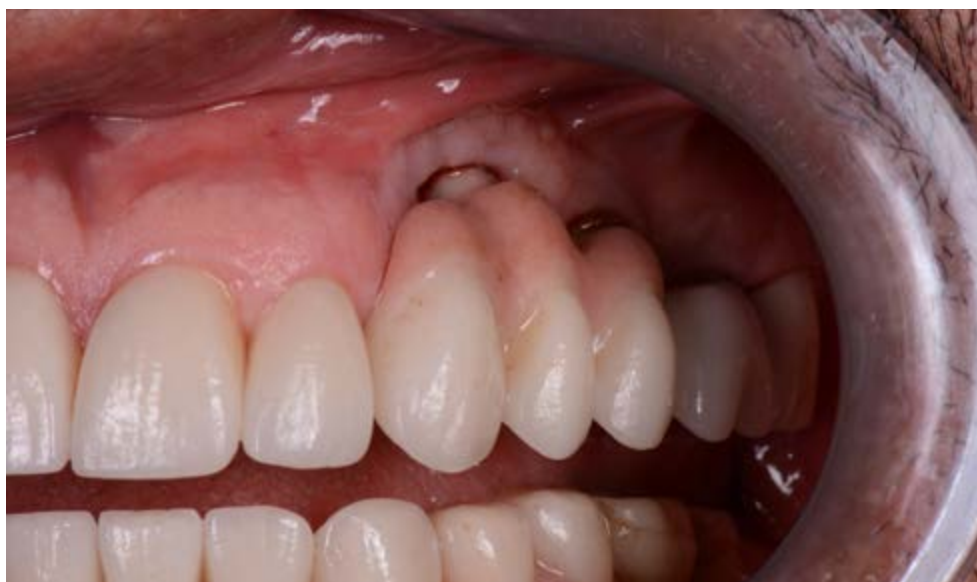PATIENT FEEDBACK

“I’M HAPPY THIS TYPE OF GBT CLEANING WAS ABLE TO HELP SAVE MY IMPLANT. I REALLY DIDN’T WANT TO HAVE TO GET A NEW ONE PLACED.”

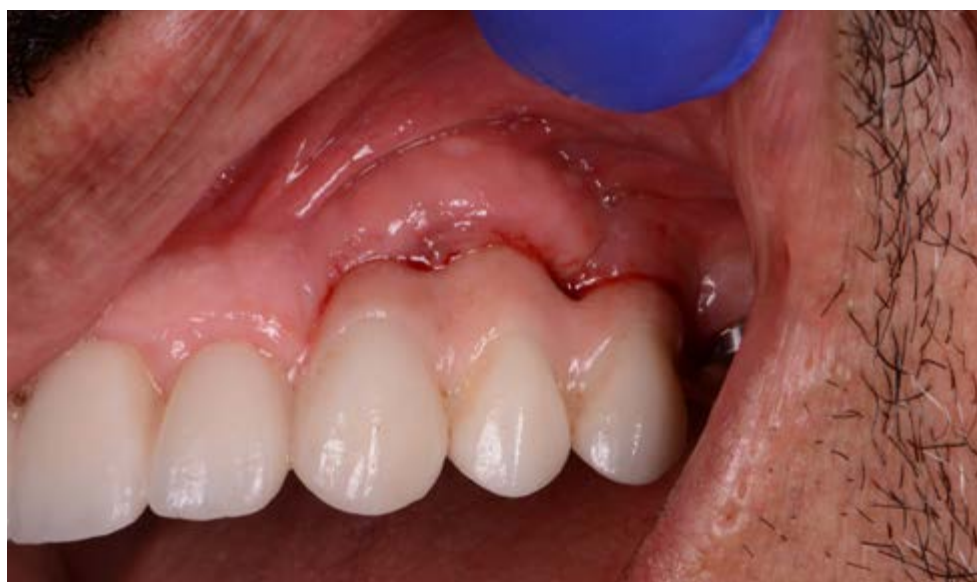BEFORE GBT



**AFTER
DISCLOSING**



AFTER GBT



IMPLANTS AND GBT

CASE 29



CLINICIAN

Manuela Netto
Pedro De Luca
Dentists
Brazil

PATIENT INFORMATION

- ▶ Age 43, female.

BACKGROUND INFORMATION

- ▶ Not very regular with professional teeth cleaning.

CLINICAL FINDINGS

- ▶ Severe localized periodontitis, 6 mm and 7 mm deep pockets on the upper premolars 15 and 14, and mucositis on anterior upper implants.

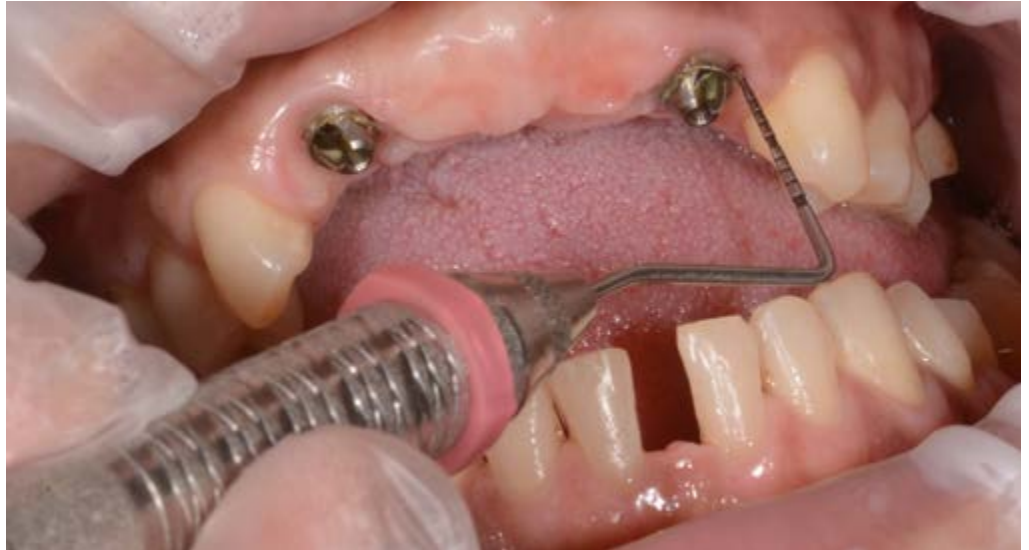TREATMENT

- ▶ The GBT protocol was completed using AIRFLOW® MAX handpiece with PLUS Powder around area of mucositis specifically.. In addition PERIOFLOW® Nozzle and PIEZON® PS Instrument were used to clean deep periodontal pockets and remove calculus around natural teeth.

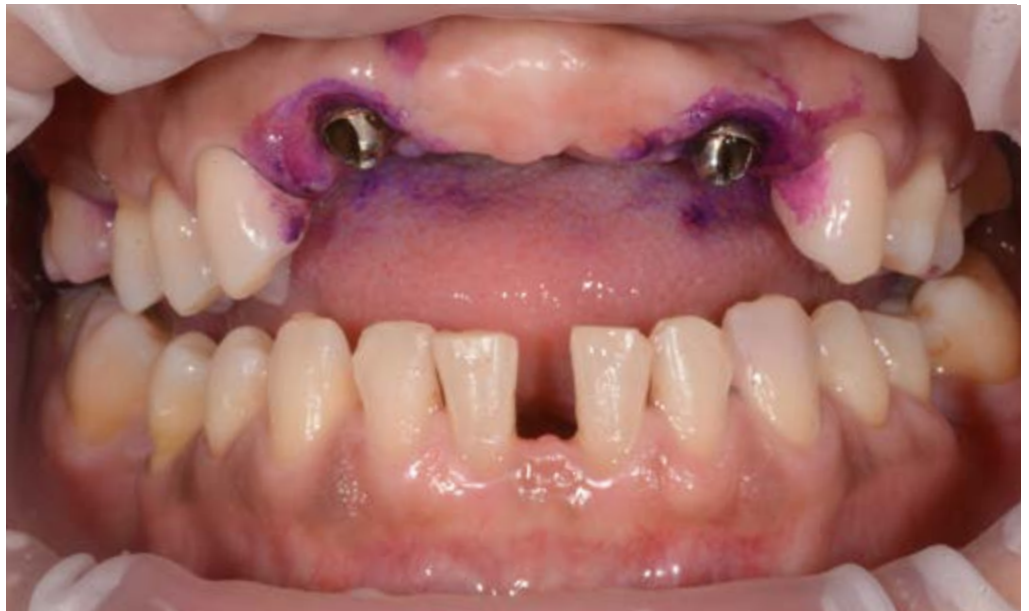PATIENT FEEDBACK

“VERY COMFORTABLE TREATMENT WITH NO PAIN AT ALL!” I FEEL AN IMPROVEMENT AFTER GBT IN MY ORAL HEALTH.”

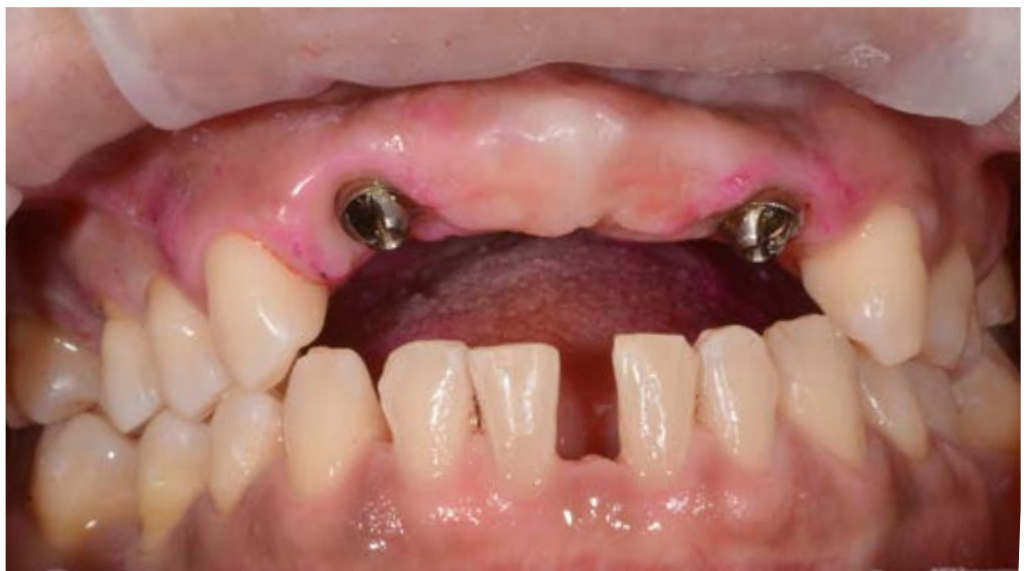BEFORE GBT



**AFTER
DISCLOSING**

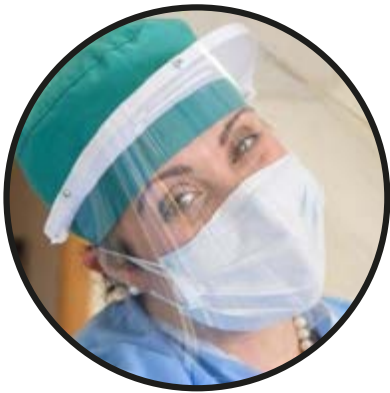

AFTER GBT



IMPLANTS AND GBT

CASE 30



CLINICIAN

Marisa Cataneo
Dental hygienist
Italy

PATIENT INFORMATION

- ▶ Age 60, female.

BACKGROUND INFORMATION

- ▶ The patient smokes and not much motivated about dental hygiene. Patient with severe inflammation. No relevant habits.

CLINICAL FINDINGS

- ▶ Pain and functional discomfort. Presence of inflammation around the implants. BOP +

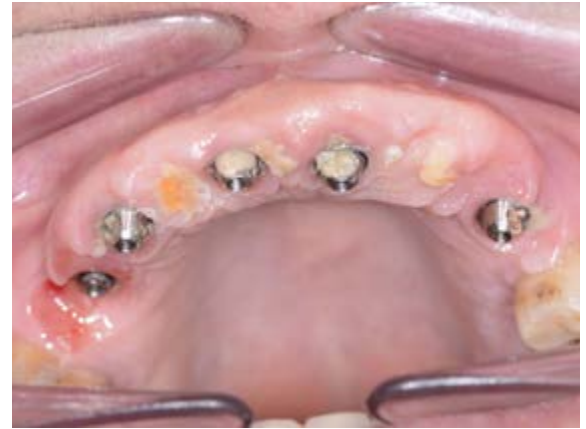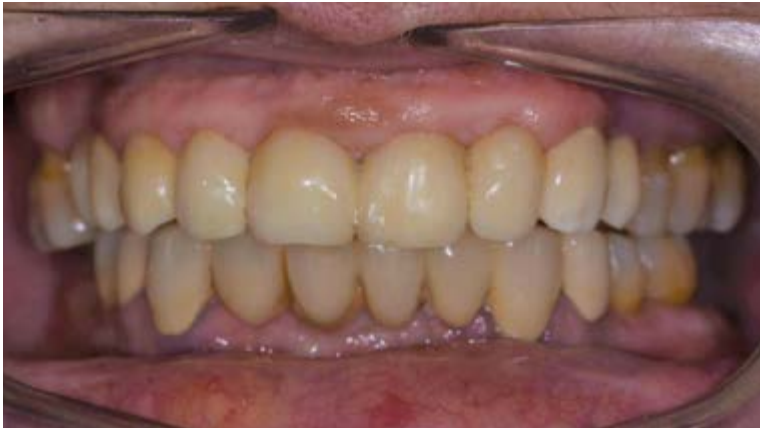TREATMENT

- ▶ Guided Biofilm Therapy session with AIRFLOW® PLUS Powder with AIRFLOW® and PERIOFLOW® handpieces. Subsequently, removal of calculus using the PIEZON® handpiece and PIEZON® PS Instrument. Prescription of antibiotic therapy of amoxicillin 500 + metronidazole 500 mg and 0.20% Clx mouthwash for 7 days.

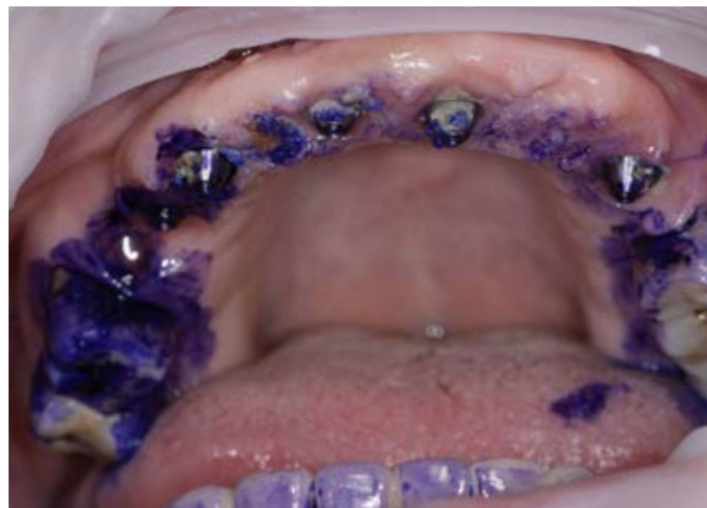PATIENT FEEDBACK

“FEW DAYS AFTER THE TREATMENT ALL SWELLING DISAPPEARED. I FELT REALLY RELIEVED AND ALL THE IRRITANTS WERE GONE. THANK YOU FOR EVERYTHING.”

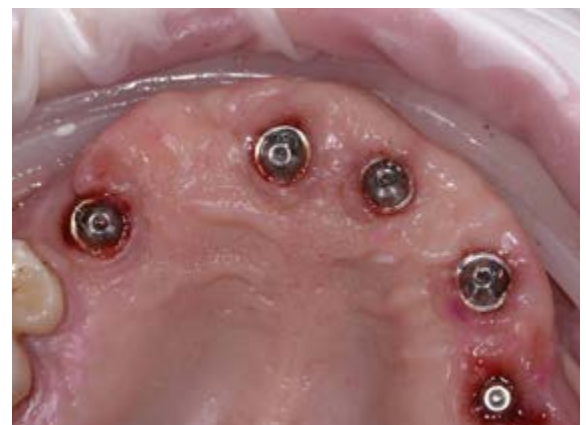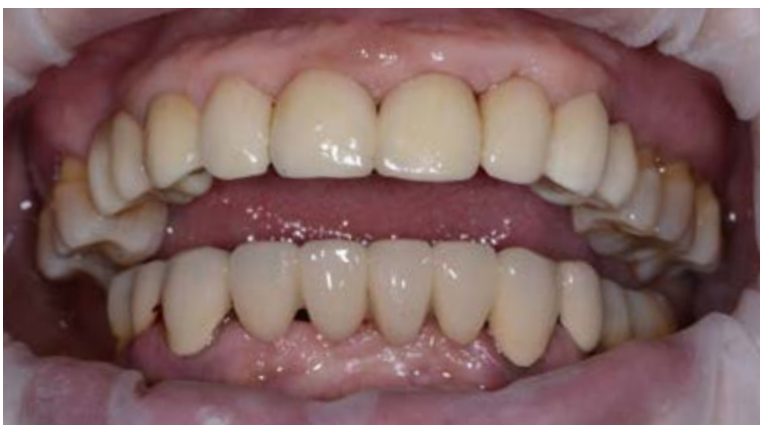BEFORE GBT



AFTER DISCLOSING



AFTER GBT



IMPLANTS AND GBT

CASE 31



CLINICIAN

Nicole Stevanello
Dental hygienist
Italy

PATIENT INFORMATION

- ▶ Age 62, female.

BACKGROUND INFORMATION

- ▶ Poor oral hygiene. Non-smoker, no disease, no medication.

CLINICAL FINDINGS

- ▶ Presence of plaque and BOP on all implants. The patient presented signs of peri-implantitis with profuse bleeding on probing, a probing pocket depth (PPD) of ≥ 6 mm with level of bone loss of ≥ 3 mm to the implants in position (16; 26; 21; 23).

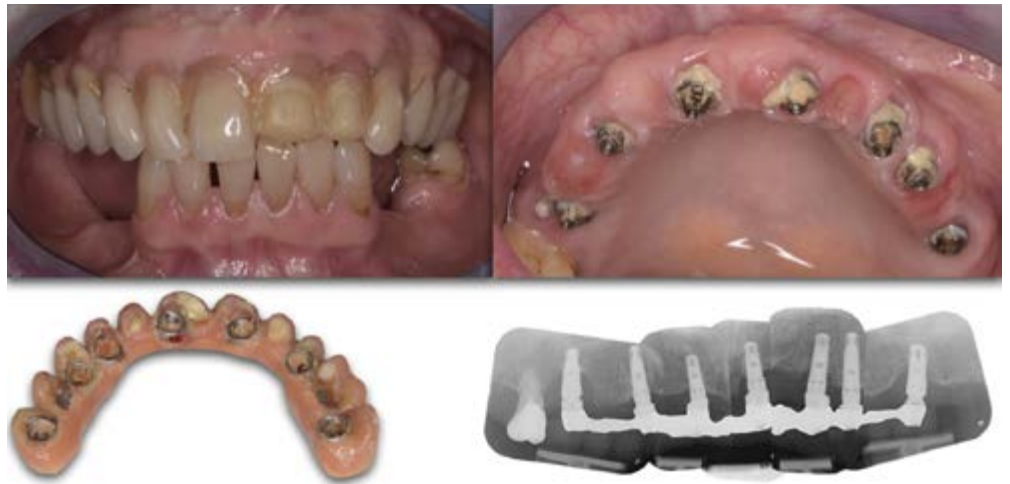TREATMENT

- ▶ AIRFLOW® with PLUS Powder used supra- and subgingivally followed by PERIOFLOW® into the peri-implant pockets to implants (16;26;23;21). After hygiene treatment the tissue compression was reduced through the removal of the buccal resin prosthetic pontics (flange reduction) for proper self-maintenance.

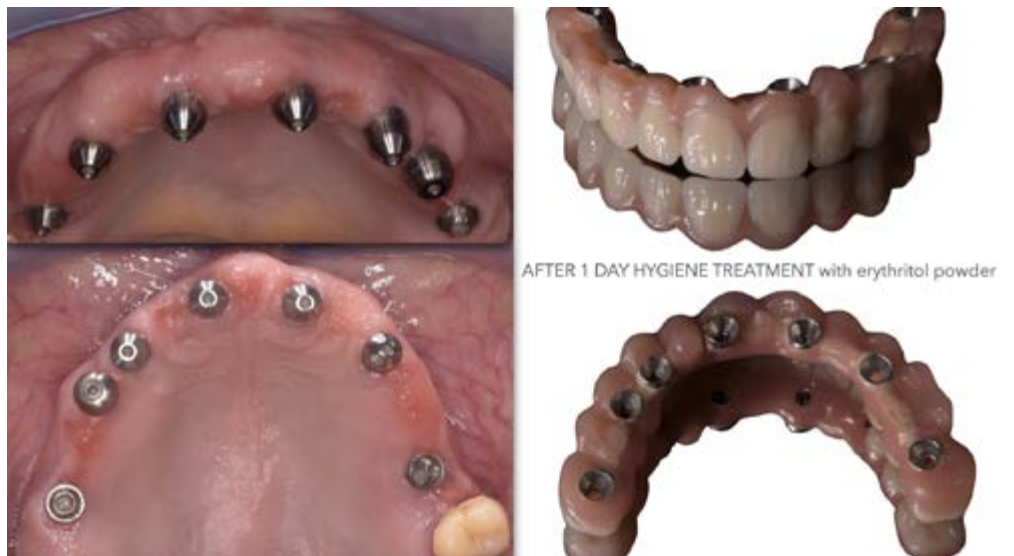PATIENT FEEDBACK

“NO MORE PAIN AND INFLAMMATION.”

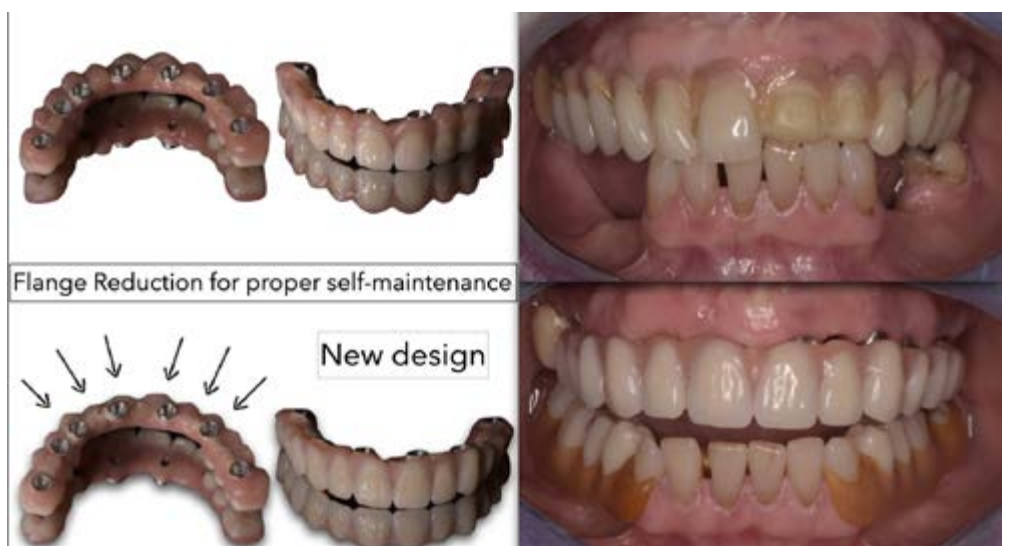BEFORE GBT



AFTER DISCLOSING



AFTER GBT



IMPLANTS AND GBT

CASE 32



CLINICIAN

Riccardo De Angelis
General dentist
Italy

PATIENT INFORMATION

- ▶ Age 55, female.

BACKGROUND INFORMATION

- ▶ Low level of oral hygiene with poor compliance. Smoker.

CLINICAL FINDINGS

- ▶ Presence of mucositis and deep probing depths around a few implants. BOP +

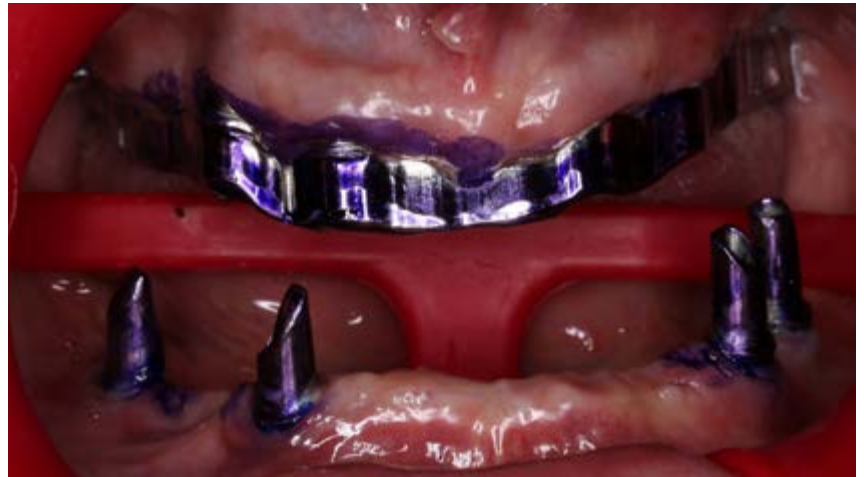TREATMENT

- ▶ Prosthesis removed, disclosing done. Patient was motivated to maintain better oral hygiene. Lecture on stopping smoking. Complete GBT treatment done with PERIOFLOW® Nozzle and PIEZON® PI Instrument.

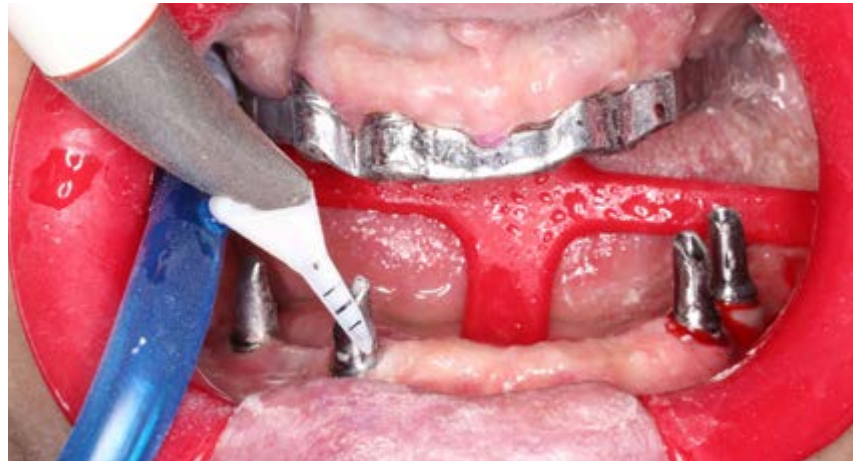PATIENT FEEDBACK

“I AM HAPPY AND HAVE NO PAIN.”

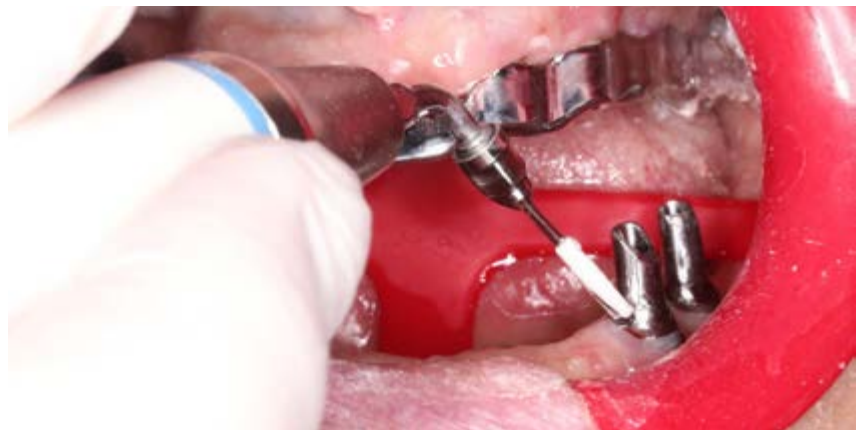**AFTER
DISCLOSING**



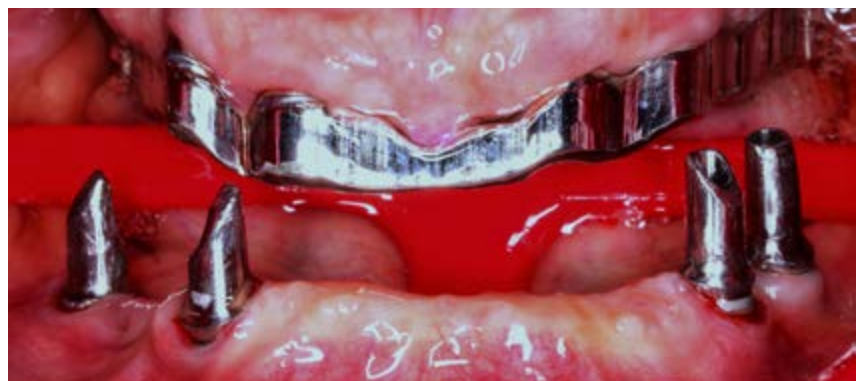PERIOFLOW®



PIEZON® PI



AFTER GBT



MAINTENANCE - RECALL

CASE 33



CLINICIAN

Adina Mauder
Dental hygienist
Germany

PATIENT INFORMATION

- ▶ Age 37, male.

BACKGROUND INFORMATION

- ▶ Last treatment 2 years ago; ceramic bridge from teeth 34-37; missing tooth 32, manual toothbrush; no interdental brushes or dental floss; oral habits, clench and grind. No relevant habits.

CLINICAL FINDINGS

- ▶ Redness, swelling; general gum bleeding; BOP 62%, calculus was found on teeth 13-23, 16,17,26, 27,36,37,46,47; generalized gingivitis; plaque index 80%.

TREATMENT

- ▶ Biofilm removed with AIRFLOW® MAX handpiece and AIRFLOW® PLUS Powder. Calculus removed with PIEZON® PS Instrument. After 1 month: BOP 10% ; API 8% ; better oral hygiene.

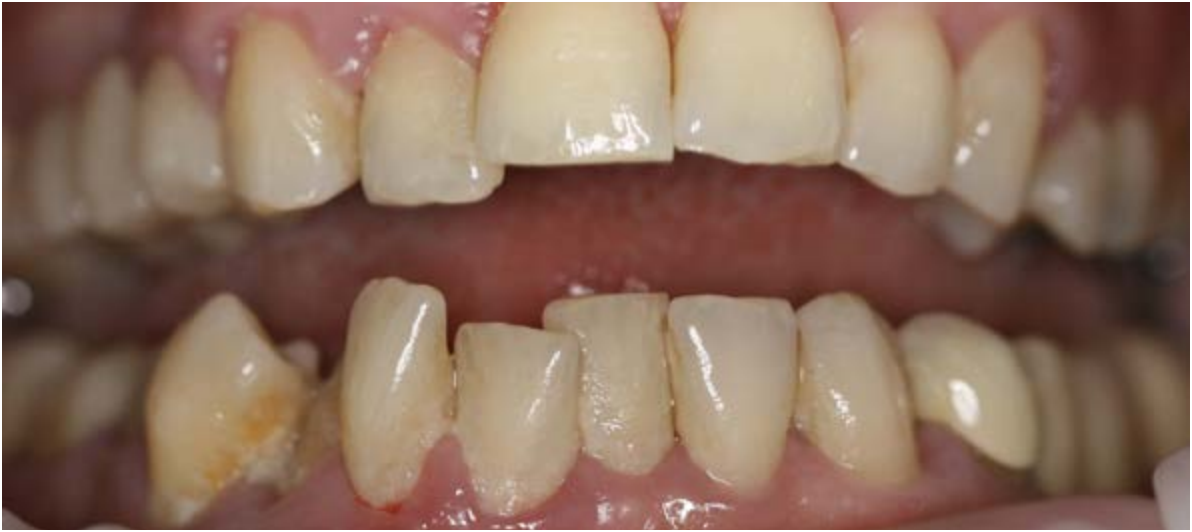PATIENT FEEDBACK

“ MY TEETH ARE SHINY AND FEEL VERY CLEAN!”

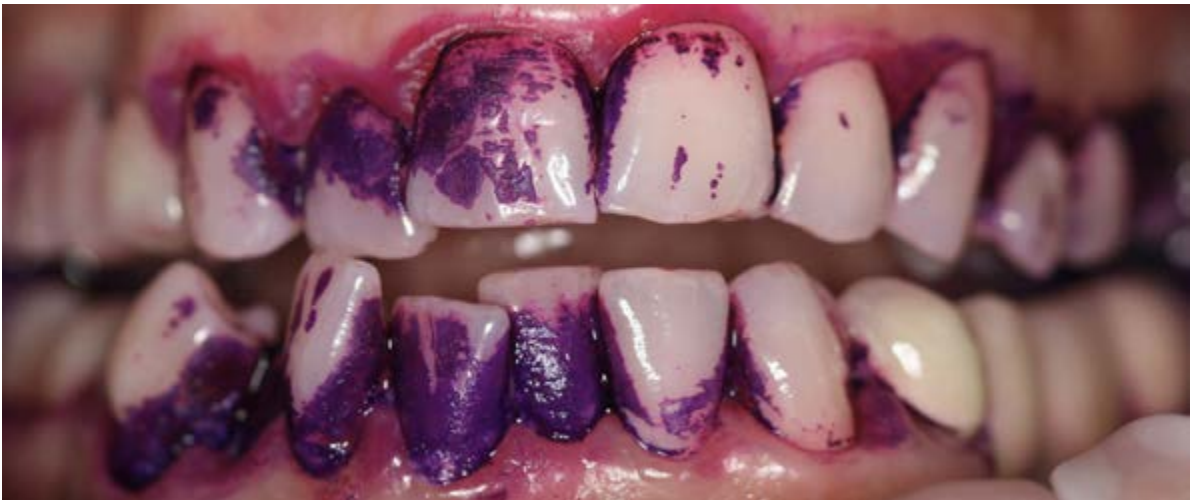PATIENT MOTIVATION



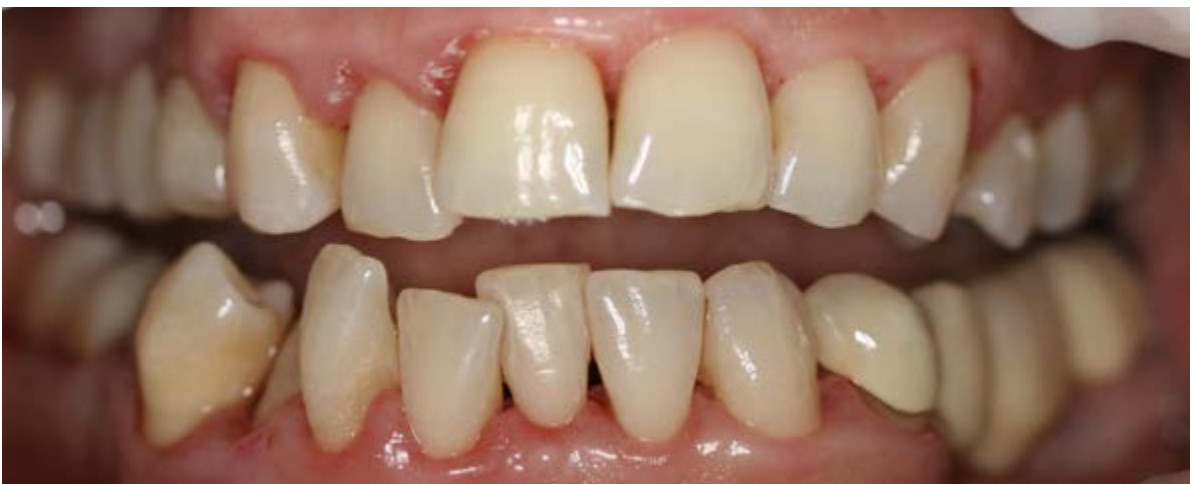BEFORE GBT



AFTER DISCLOSING



AFTER GBT



MAINTENANCE - RECALL

CASE 34



CLINICIAN:

Allison Arendziak
Dental hygienist
USA

PATIENT INFORMATION

- ▶ Age 73, male.

BACKGROUND INFORMATION

- ▶ Patient is on a 3-month periodontal maintenance recall due to heavy soft plaque and calculus accumulation and history of periodontal disease. Patient has multiple restorations present and a fissured, geographic tongue. Oral hygiene is poor. Habit of clenching and grinding.

CLINICAL FINDINGS

- ▶ Patient diagnosed with generalized stage IV, grade B disease. Probing depths range from 1-7mm with generalized bleeding points. 28% of teeth have a probing depth of 6mm or greater. Localized recessive defects noted in the left posterior. Generalized soft plaque and localized moderate calculus in the lower anteriors and upper posteriors.

TREATMENT

- ▶ Patient was disclosed with a 3 tone dye – tri tone GC. After educating the patient and reviewing oral hygiene instructions, the AIRFLOW® was used to remove the biofilm on teeth, tongue, and soft tissues. PIEZON® PS was used to remove all hard calculus and in a few areas hand instrument to remove inaccessible calculus.

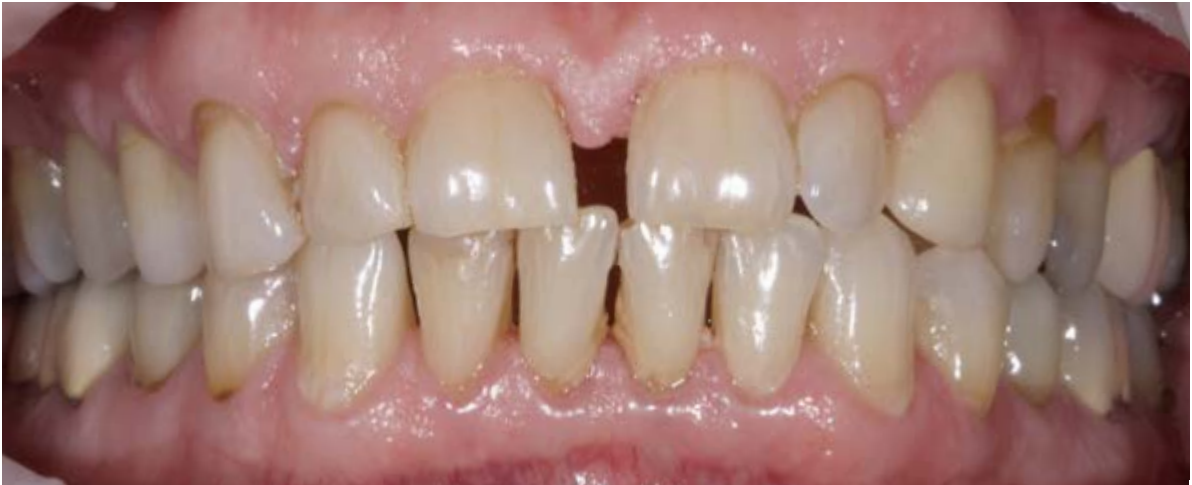PATIENT FEEDBACK

“THIS WAS THE MOST COMFORTABLE TREATMENT. I AM SATISFIED!”

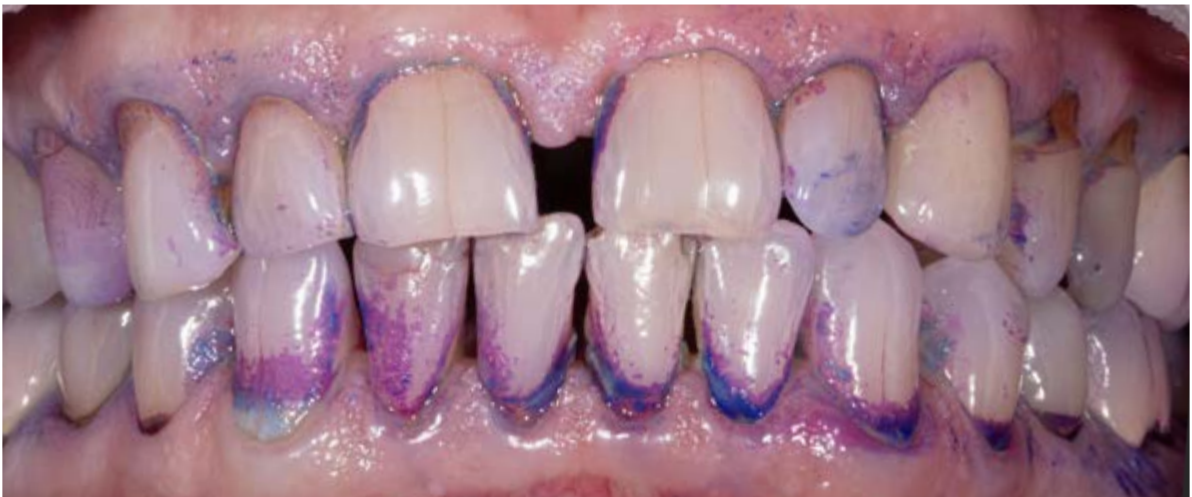PATIENT MOTIVATION



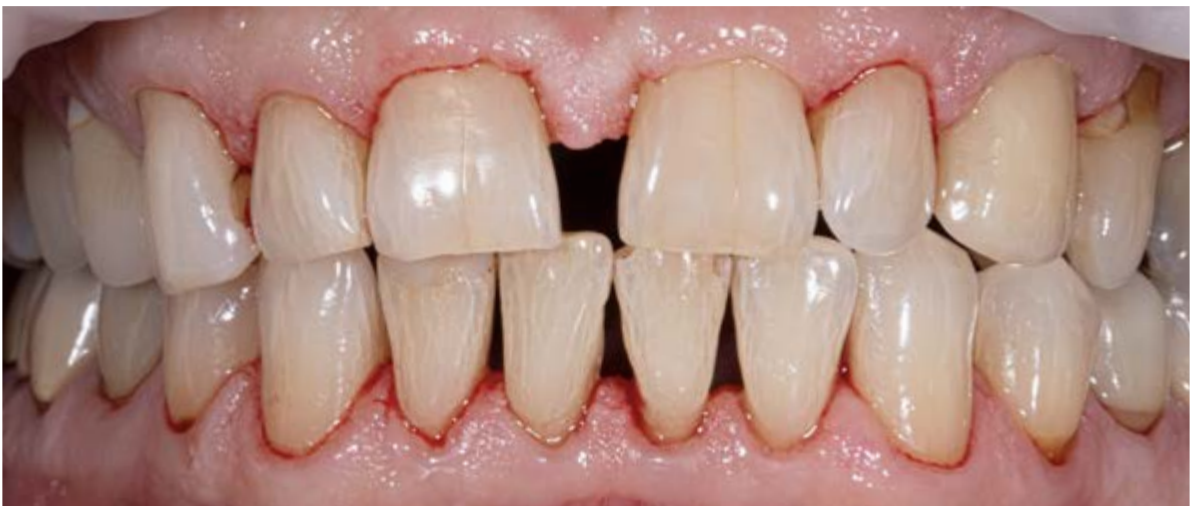BEFORE GBT



AFTER DISCLOSING



AFTER GBT



MAINTENANCE - RECALL

CASE 35



CLINICIAN

Bianca Maria Messina
Dental hygienist
Italy

PATIENT INFORMATION

- ▶ Age 26, male.

BACKGROUND INFORMATION

- ▶ No professional hygiene for at least 2 years. The patient came for a visit because of gum bleeding when brushing his teeth and to remove smoking stains. Uses manual toothbrushes, does not use floss. Smoker.

CLINICAL FINDINGS

- ▶ No deep periodontal pockets, presence of gingival inflammation, BOP + (bleeding on probing), presence of calculus especially in the lower anterior region and on upper canine.

TREATMENT

- ▶ Used biofilm discloser to show biofilm and calculus condition and motivated patient to use electric toothbrushes and dental floss. Performed GBT using AIRFLOW[®] MAX with AIRFLOW[®] PLUS Powder to remove all biofilm and stains and used PIEZON[®] PS Instrument to remove supragingival calculus.

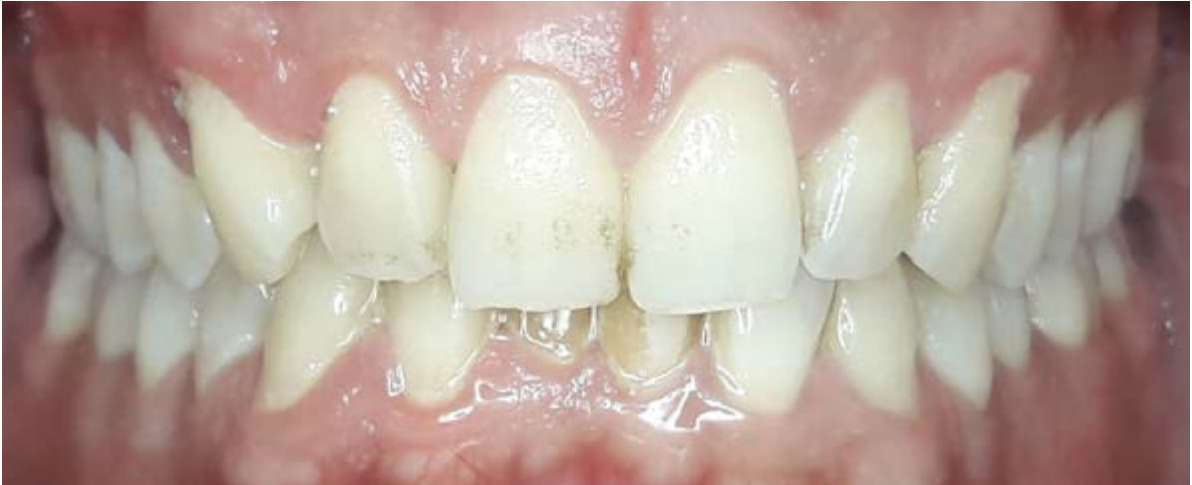PATIENT FEEDBACK

“I’M SATISFIED AND HAPPY. I’LL BE BACK FOR RECALL.”

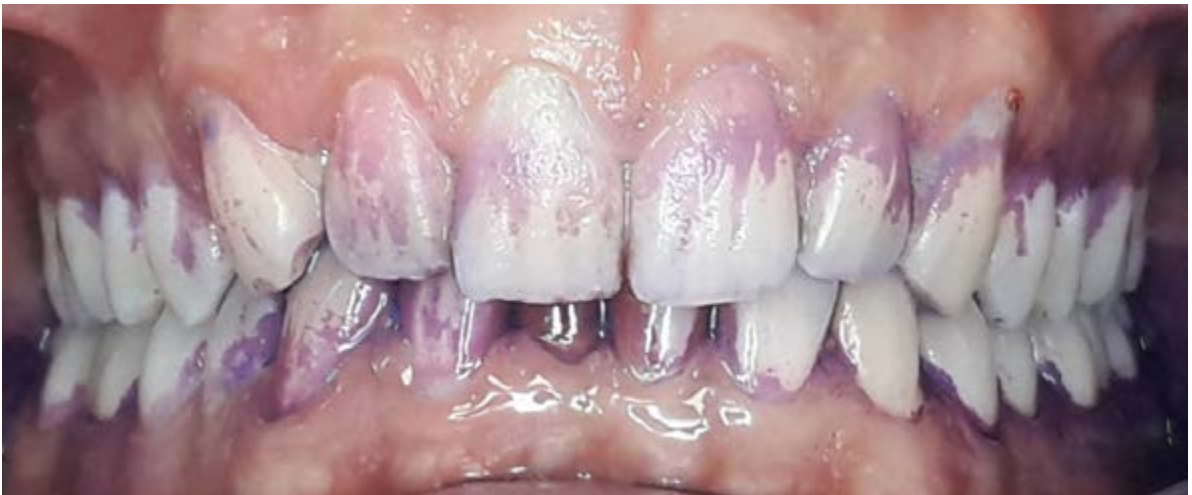PATIENT MOTIVATION



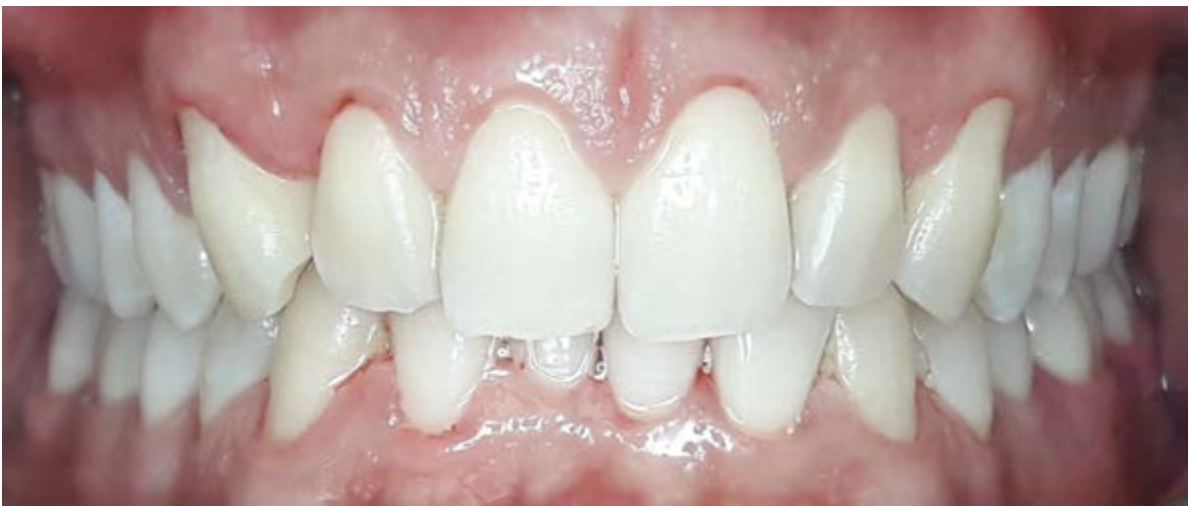BEFORE GBT



AFTER DISCLOSING



AFTER GBT



MAINTENANCE - RECALL

CASE 36



CLINICIAN

Boris Radenkov
Dentist
Bulgaria

PATIENT INFORMATION

► Age 22, male.

BACKGROUND INFORMATION

► He is referred to us by his boss, who is our patient (GBT user). His boss called us and said, “I’m sending you a young man. I can’t look at his teeth like that, you have to do something.” The patient claims that the last cleaning was less than a year ago - performed by the conventional method, without advice on better home oral hygiene. Regularly falls asleep watching movies and eating junk food.

CLINICAL FINDINGS

► Biofilm-induced gingivitis. There are no surfaces free of plaque. BOP+++. In this case the biofilm is visible to the naked eye, but the patient thought he had a good hygiene... until the “disclose” step.

TREATMENT

► GBT with an emphasis on motivation - recommendations for proper brushing and elimination of the harmful habit of eating in bed. After the first procedure, the patient was very happy because he did not feel any pain. At the recall one month later, the patient again showed unsatisfactory oral hygiene. He was advised to use disclosing tablets every evening for 2 weeks to better strengthen the habit of (proper) brushing. Two months later the patient shows much better oral hygiene and the gums look good - the papillae are not swollen and there is almost no bleeding on probing.

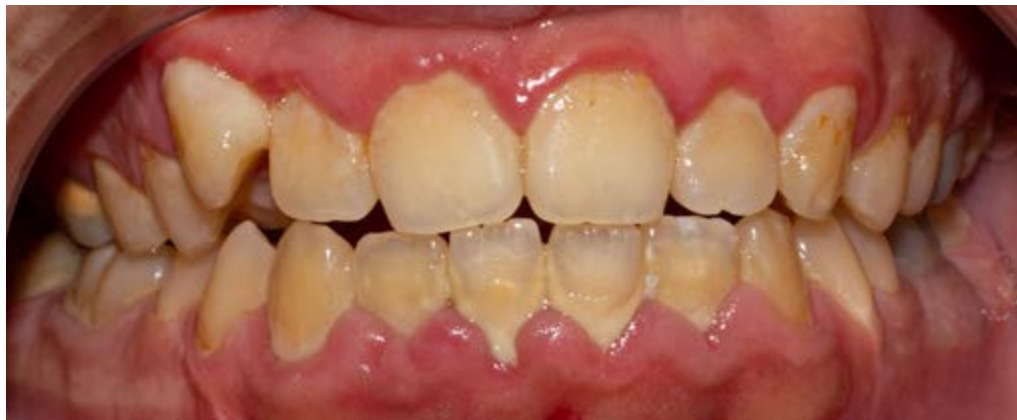PATIENT FEEDBACK

“THE FEELING IS TOTALLY DIFFERENT. I CAN COME EVERY WEEK!”

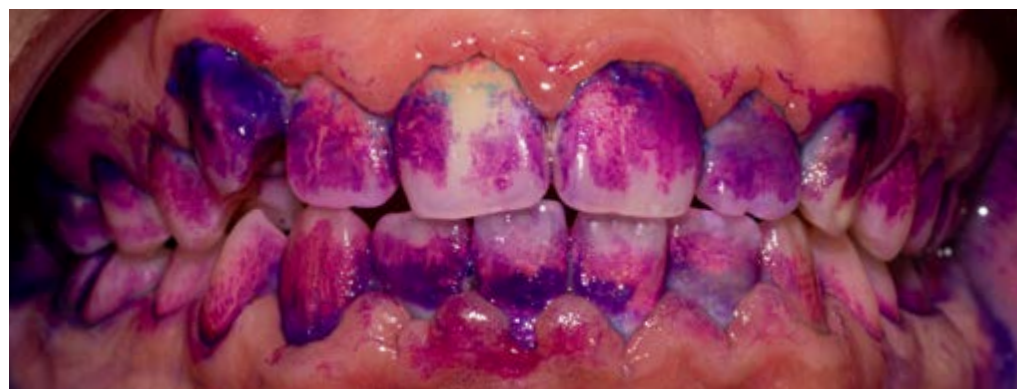PATIENT MOTIVATION



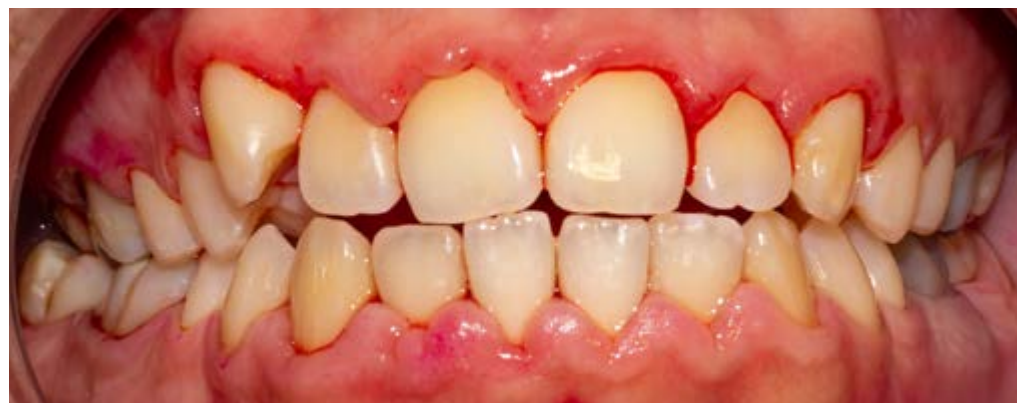BEFORE GBT



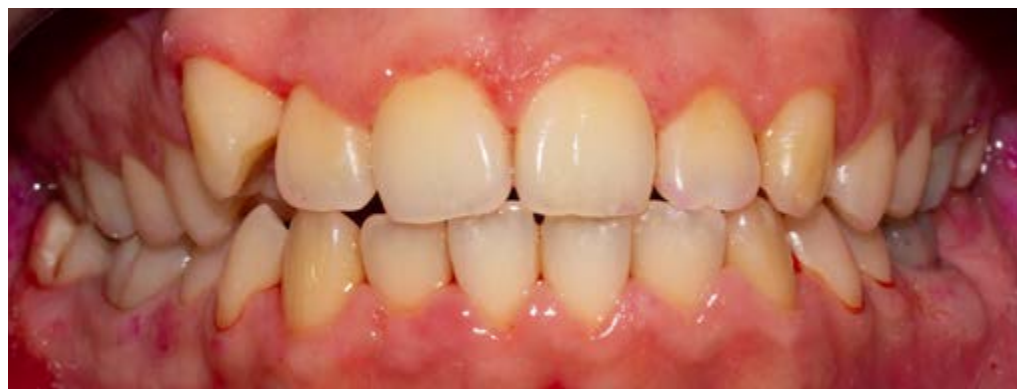AFTER DISCLOSING



AFTER GBT



**2-MONTH
RECALL**



MAINTENANCE - RECALL

CASE 37



CLINICIAN

Claudia Elizalde Molina
Periodontist
Mexico

PATIENT INFORMATION

- ▶ Age 30, female.

BACKGROUND INFORMATION

- ▶ History of orthodontics in the past and esthetic crown lengthening 18 weeks ago. No relevant habits.

CLINICAL FINDINGS

- ▶ Bleeding on probing and biofilm.
Orthodontic lingual retainer with the presence of biofilm and calculus.
Esthetic composite in superior incisors.

TREATMENT

- ▶ Biofilm disclosure motivated the patient to understand the importance of biofilm and good oral hygiene necessary for a healthy mouth. AIRFLOW® PLUS Powder was used first using GBT protocol and then we used the PIEZON® PS Instrument to remove the calculus. Patient recall every 6 months. Recall with GBT : every 6-8 weeks during the first year of treatment, later on every 3 months.

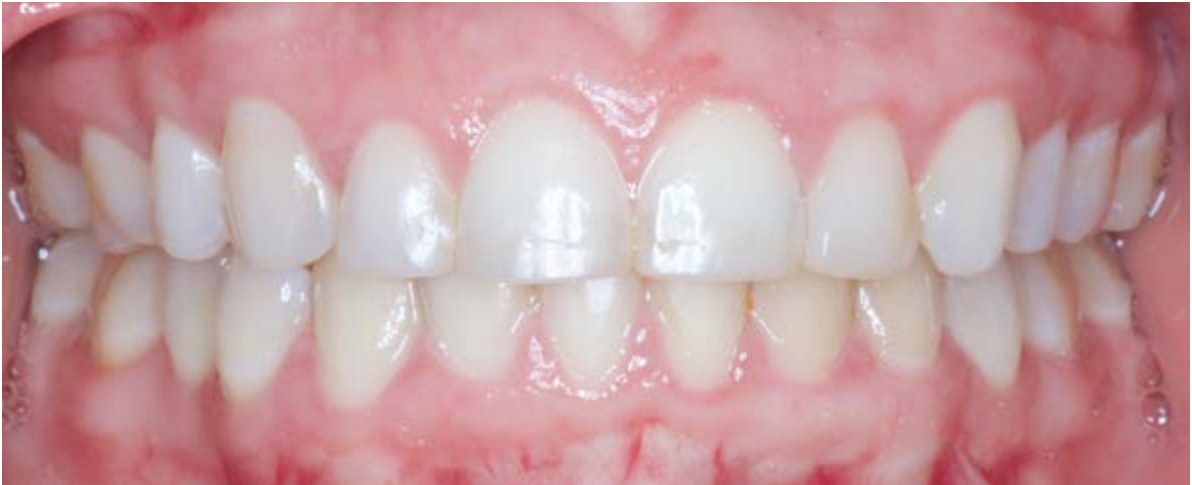PATIENT FEEDBACK

“I AM VERY HAPPY BECAUSE I HAVE MY TEETH CLEANED WITH THE NEW TECHNOLOGY WITHOUT PAIN BECAUSE I DON’T WANT ANYMORE THE OLD FASHION WAY BECAUSE MY ESTHETIC COMPOSITE COULD BE DAMAGED WITH THE ULTRASONIC SCALER.”

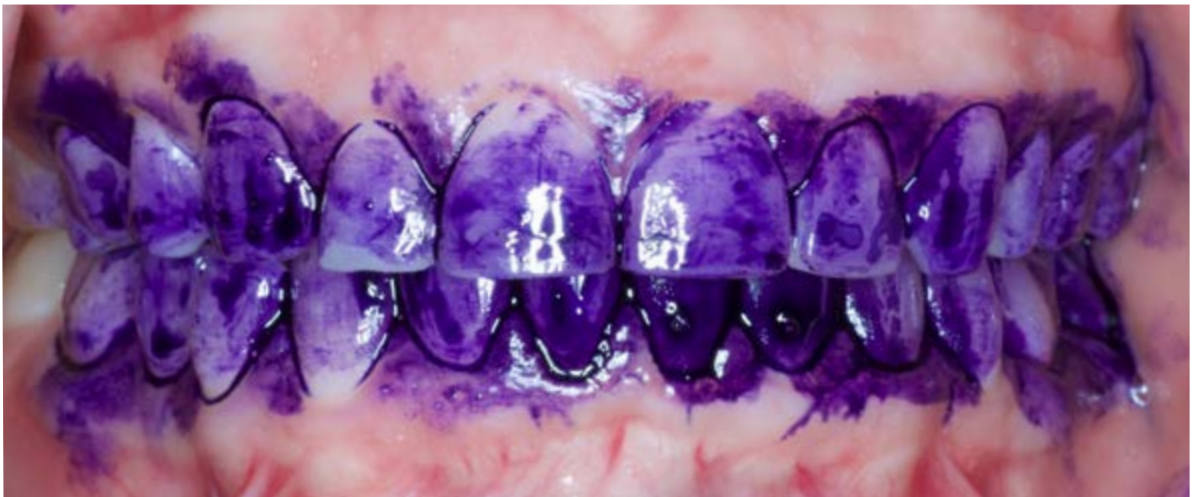PATIENT MOTIVATION



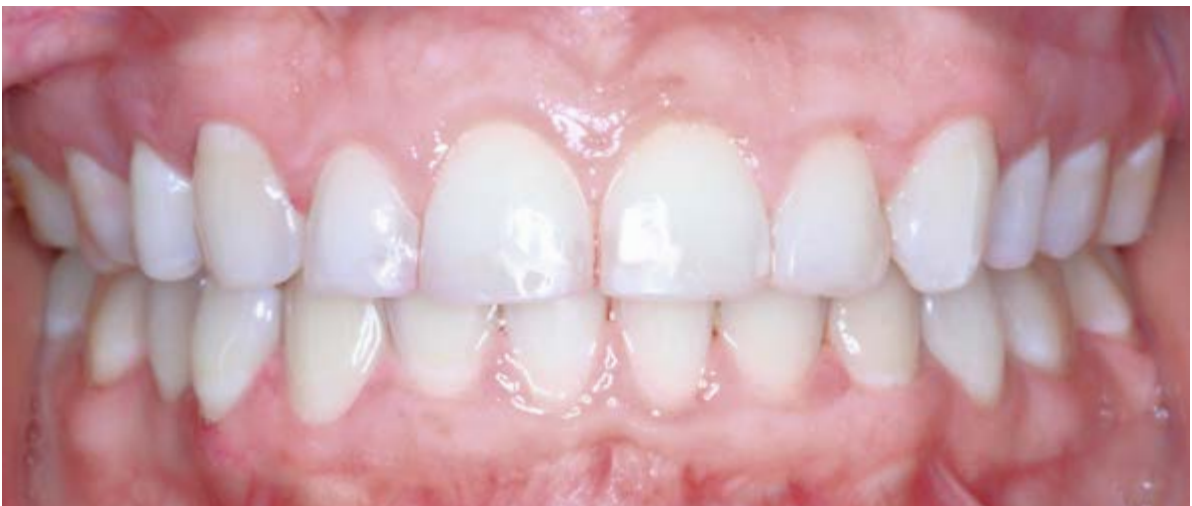BEFORE GBT



AFTER DISCLOSING



AFTER GBT



MAINTENANCE - RECALL

CASE 38



CLINICIAN

Dai Jinjing
Dental hygienist
China

PATIENT INFORMATION

► Age 27, male.

BACKGROUND INFORMATION

► Habit of smoking since the age of 23. Lazy in general. Heavy smoker, poor habit of brushing teeth, doesn't know how to use dental floss. No professional oral cleaning for a long time.

CLINICAL FINDINGS

► Generalized gingivitis. BOP +. Oral hygiene average. Presence of interdental calculus.

TREATMENT

► First, carry out preoperative tooth staining examination, explain and communicate the results and explain the precautions. According to inspection, first use AIRFLOW® to clean plaque and heavy smoke stains, then use PIEZON® PS to remove the calculus.

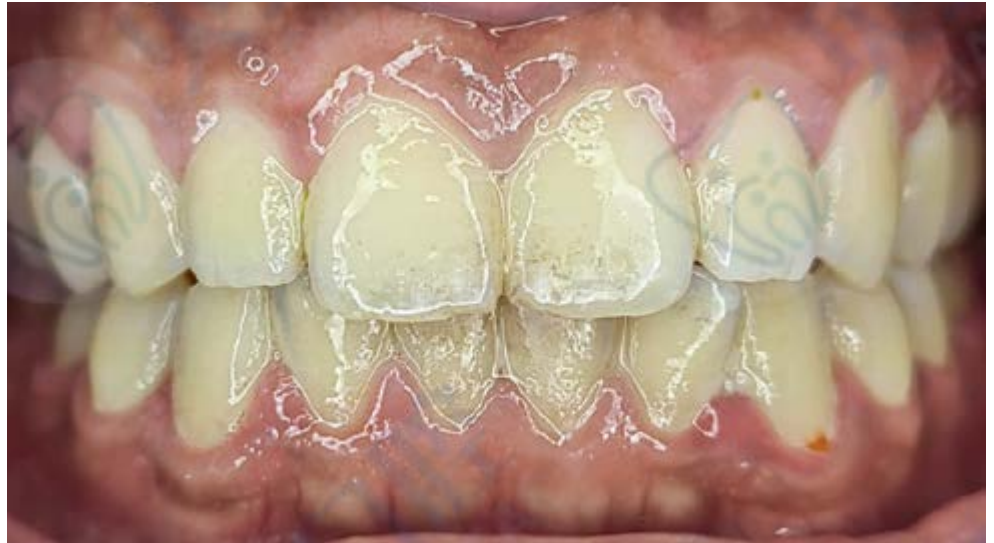PATIENT FEEDBACK

"I NEVER THOUGHT MY TEETH COULD BE THAT CLEAN! THANKS GBT!"

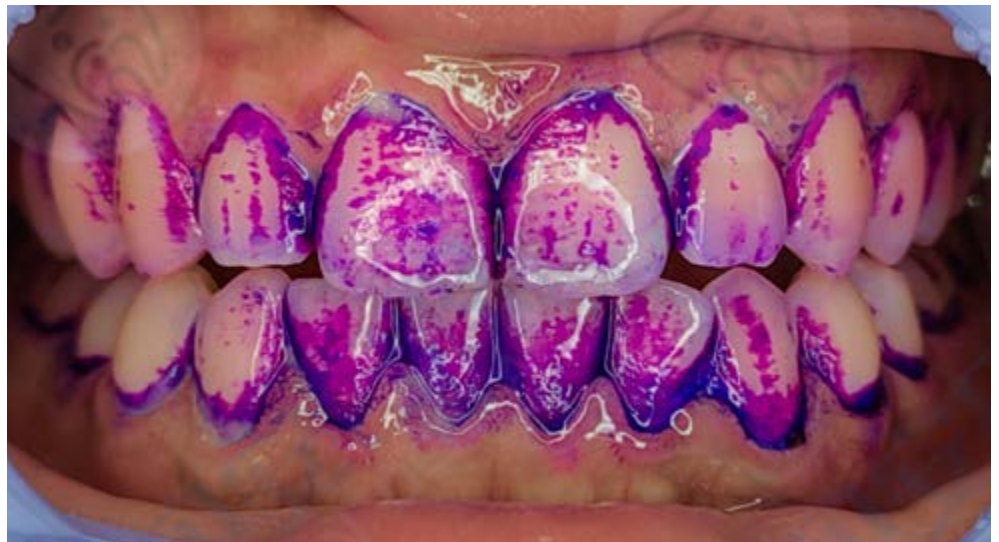PATIENT MOTIVATION



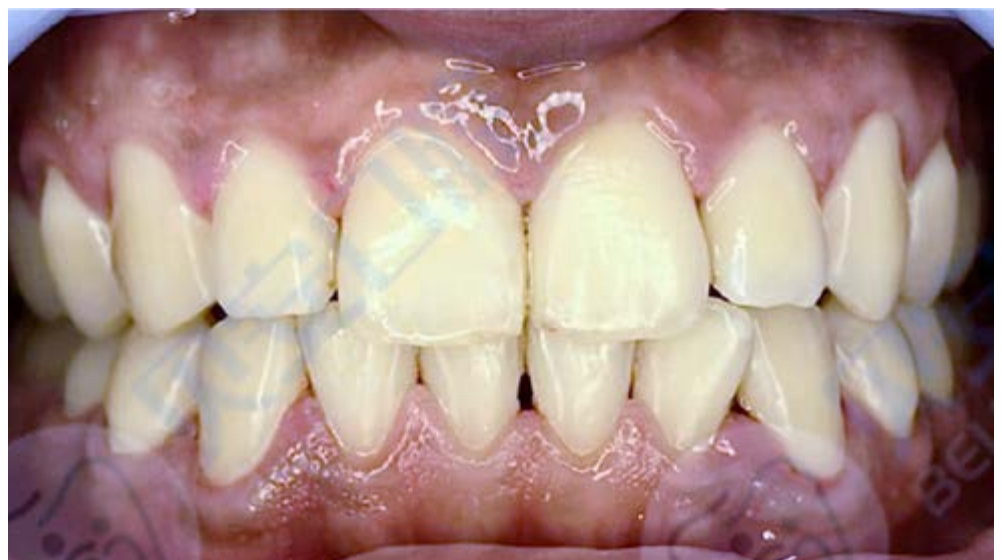BEFORE GBT



AFTER DISCLOSING



AFTER GBT



MAINTENANCE - RECALL

CASE 39



CLINICIAN

Dr. Hu Xiang,
Dr. Lv Da,
Dr. Wang Xiyu
Dr. Chen Gang
Dentists
China



PATIENT INFORMATION

► Age 37, female.

BACKGROUND INFORMATION

► Multiple teeth gradually loosened for a year. She rarely cleaned her teeth. Her gums often bled. Lost a few teeth during pregnancy. She is healthy and has no smoking habits.

CLINICAL FINDINGS

► Intraoral examination. Poor hygiene, dark red and swollen gums, calculus ++. Multiple periodontal pockets. Presence of periodontitis stage III, grade C.

TREATMENT

► GBT treatment oriented towards biofilm management using AIRFLOW® PLUS Powder followed by surgical intervention (implant placement), orthodontic treatment with regular professional plaque control. Follow up at 2, 8, 18 and 23 months. Improvement in oral health.

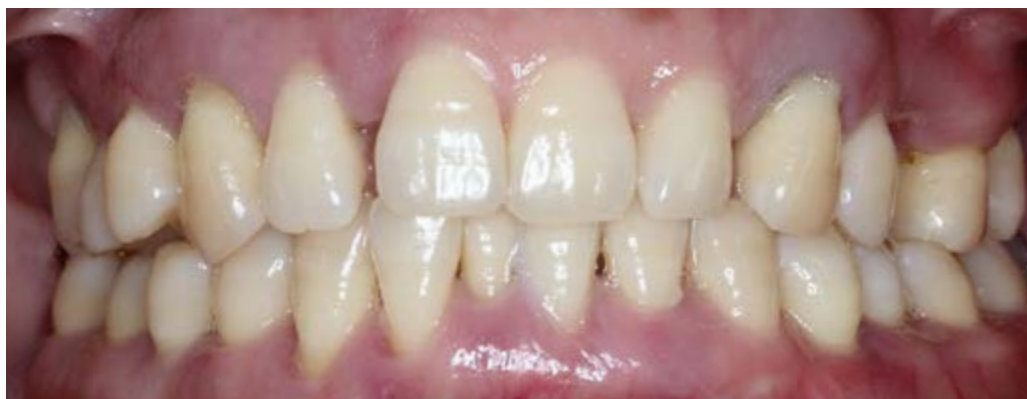PATIENT FEEDBACK

**“I CAN SEE ALL THE GOOD CHANGES. WILL COME BACK
FOR REGULAR CHECKUPS.”**

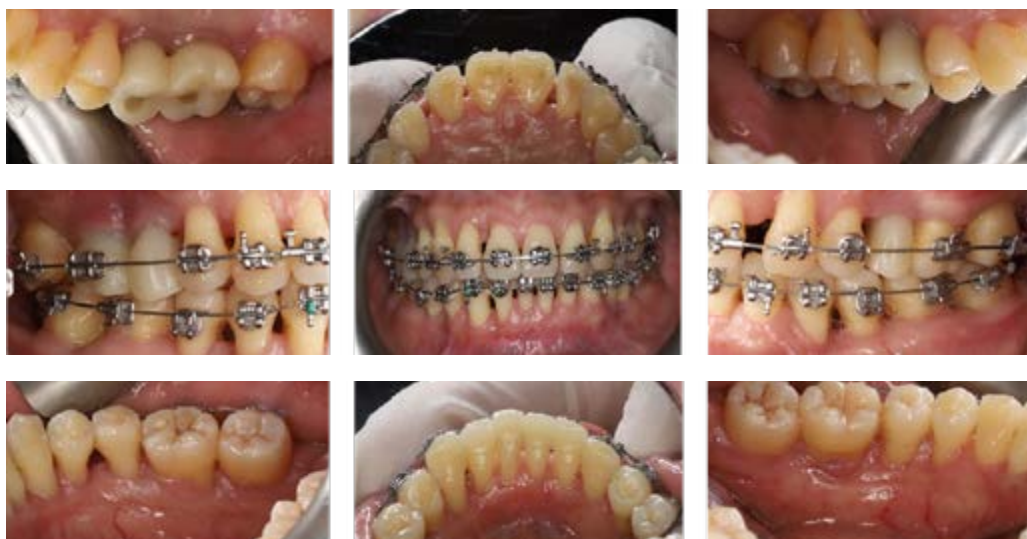PATIENT MOTIVATION



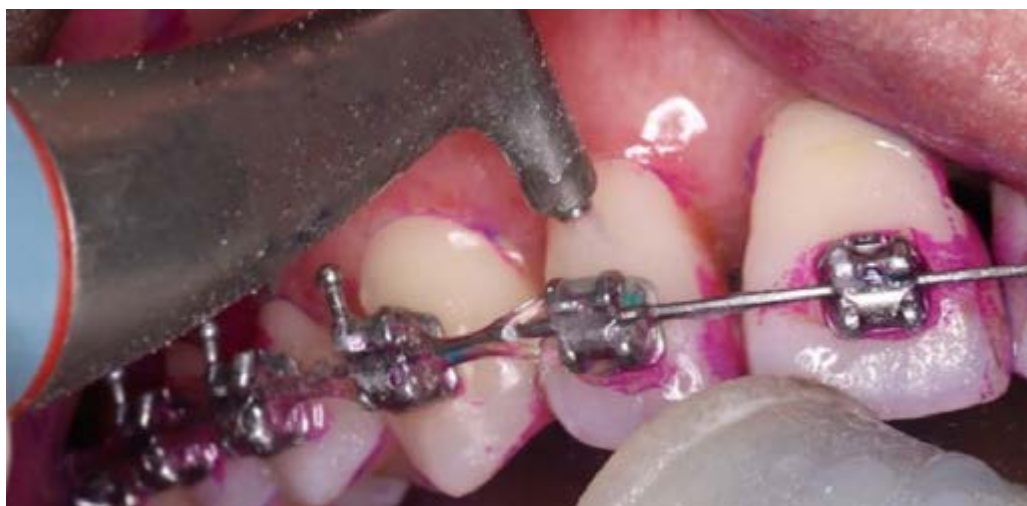BEFORE



POST IMPLANT AND ORTHONDICS



GBT WITH AIRFLOW®



MAINTENANCE - RECALL

CASE 40



CLINICIAN

Manuela Netto
Pedro De Luca
Dentists
Brazil

PATIENT INFORMATION

► Age 32, male.

BACKGROUND INFORMATION

► Heavy smoker, no systemic diseases. His major complaint was the pigmentation caused by nicotine. Brushes well.

CLINICAL FINDINGS

► Diagnosed with gingivitis. No bleeding on probing. Good oral hygiene. Presence of interdental calculus. Stains present in the palatal and lower anterior region.

TREATMENT

► GBT protocol was done, and all stains were removed with AIRFLOW® PLUS Powder. PIEZON® PS was used to remove the calculus. Repair or replacement were recommended because flaws and gaps were detected in the composite restoration during the recheck phase.

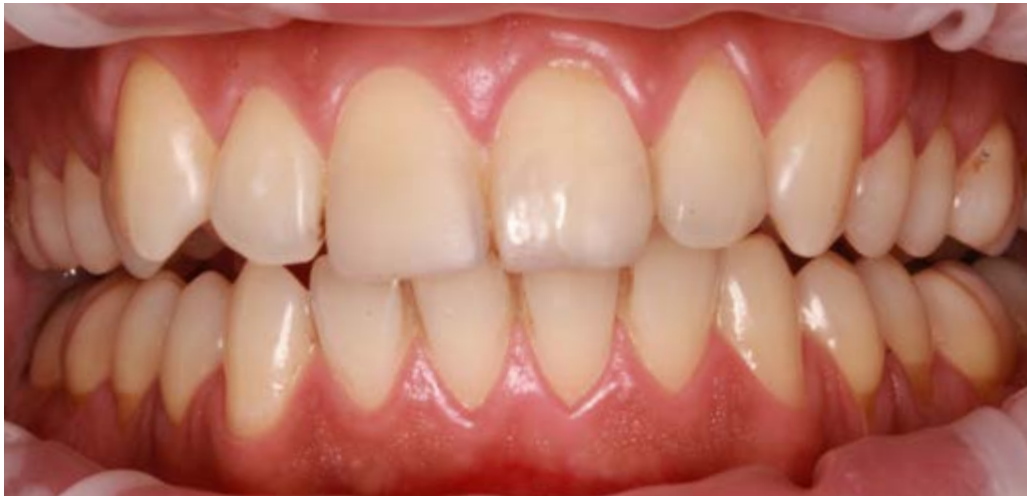PATIENT FEEDBACK

“I’M REALLY HAPPY THAT THE WHOLE APPOINTMENT LASTED ONLY 40 MINUTES TO REMOVE ALL THE STAINS, WHILE IT TOOK AT LEAST 90 MINUTES BEFORE WITH THE CONVENTIONAL METHOD.”

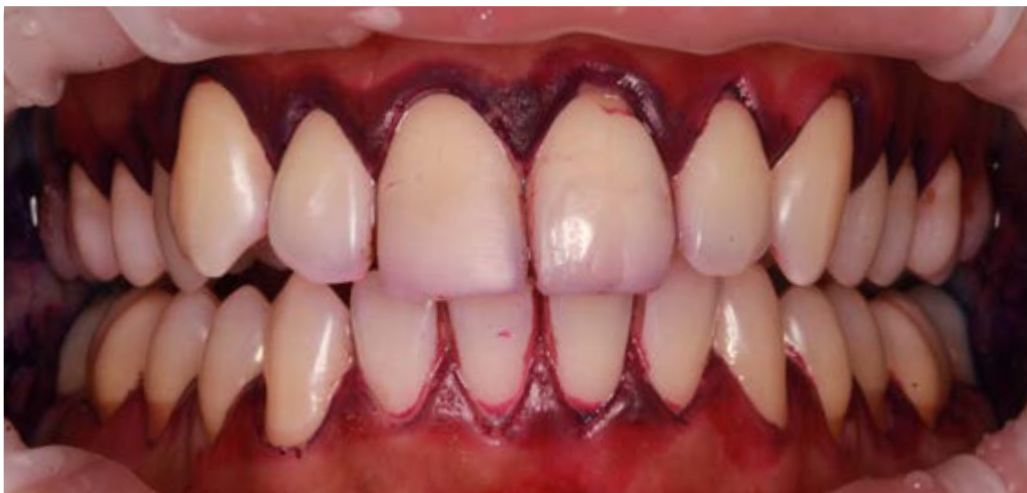PATIENT MOTIVATION



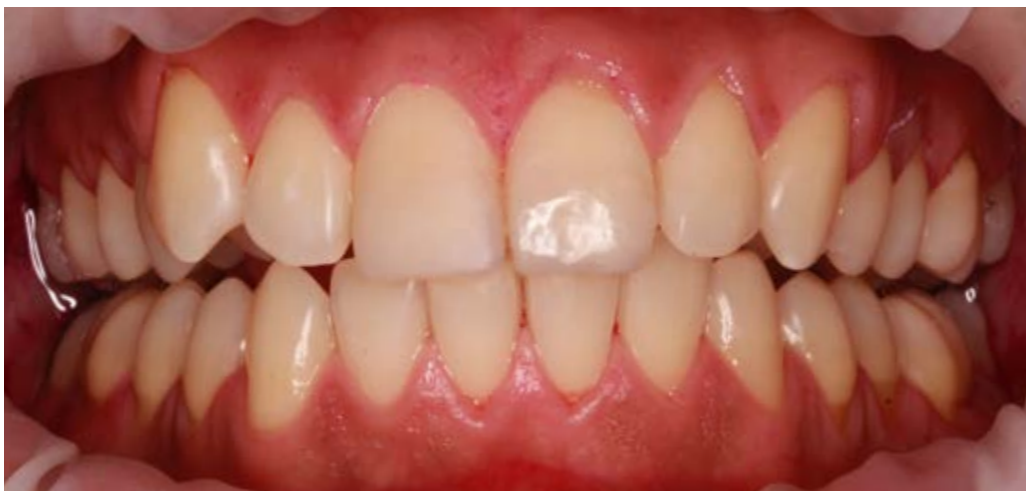BEFORE GBT



AFTER DISCLOSING



AFTER GBT



MAINTENANCE - RECALL

CASE 41



CLINICIAN

Kim Eunae
Dental hygienist
South Korea

PATIENT INFORMATION

- ▶ Age 52, male.

BACKGROUND INFORMATION

- ▶ Non-smoker. “I think I got more stain because I was wearing a mask all the time because of COVID-19”. He visited the clinic to inquire if he needed whitening his teeth. No habits.

CLINICAL FINDINGS

- ▶ Lack of plaque control causing stain. Found overall bleeding and swollen gingiva.

TREATMENT

- ▶ After disclosing, showed the patient that biofilm was mostly found on where stain was. Motivated the patient then performed tooth brushing instructions. It was emphasized that not only tooth brushing but also Waterpik should be used to manage the interproximal area. Removed all stains and biofilm using AIRFLOW® PLUS Powder.

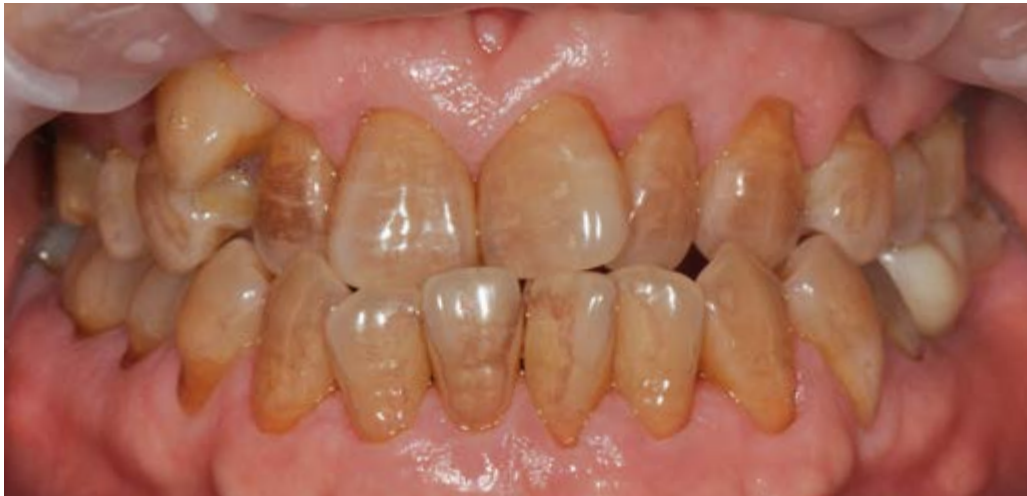PATIENT FEEDBACK

**“I DIDN’T NEED TO GET WHITENING!
I WILL GET GBT NEXT TIME AGAIN FOR SURE.”**

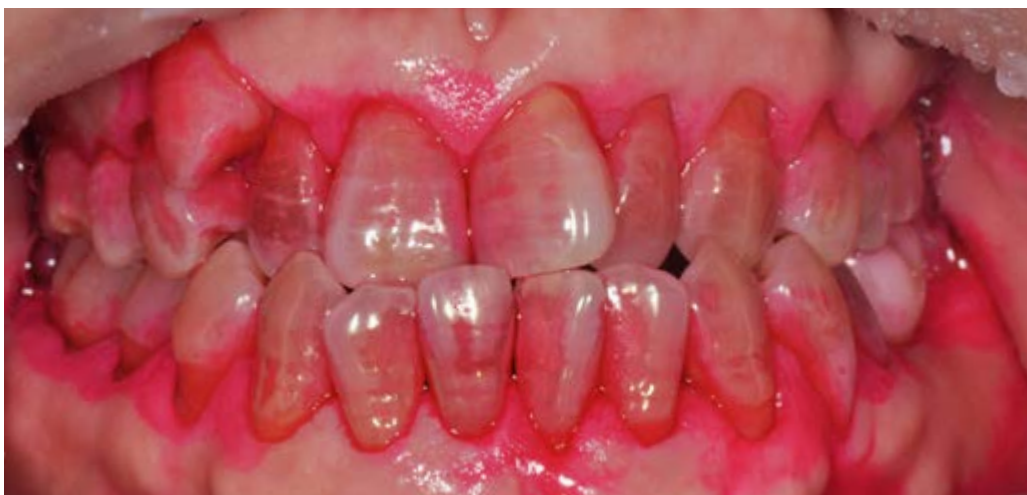PATIENT MOTIVATION



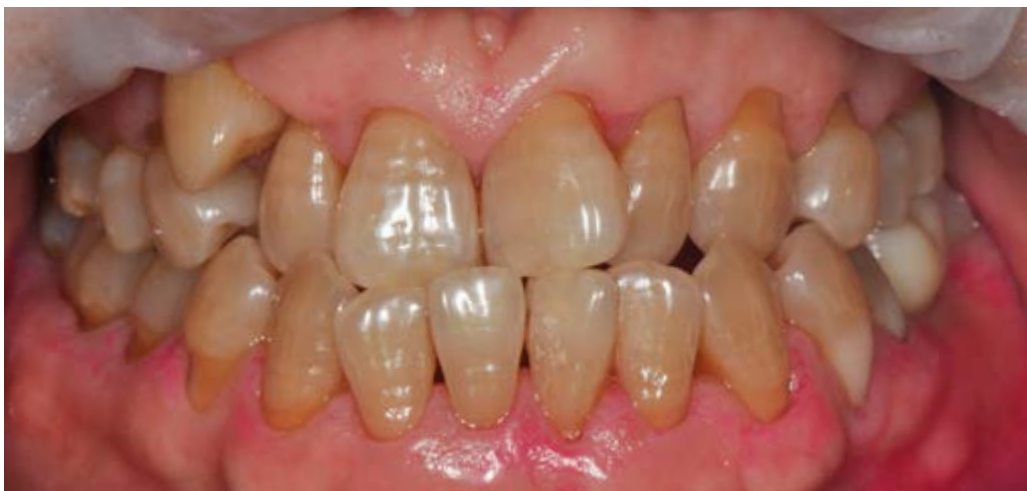BEFORE GBT



AFTER DISCLOSING



AFTER GBT



MAINTENANCE - RECALL

CASE 42



CLINICIAN

Francesca Gammino
Dental hygienist
Italy

PATIENT INFORMATION

- ▶ Age 30, male. Pushes the lower lip against the teeth.

BACKGROUND INFORMATION

- ▶ The patient had not realized the situation. I explained to him how to best use the toothbrush.

CLINICAL FINDINGS

- ▶ Gingival recession.

TREATMENT

- ▶ GBT done in the patient with AIRFLOW® PLUS Powder and PIEZON® PS Instrument to remove all the biofilm. After 2 weeks, excellent tissue healing.

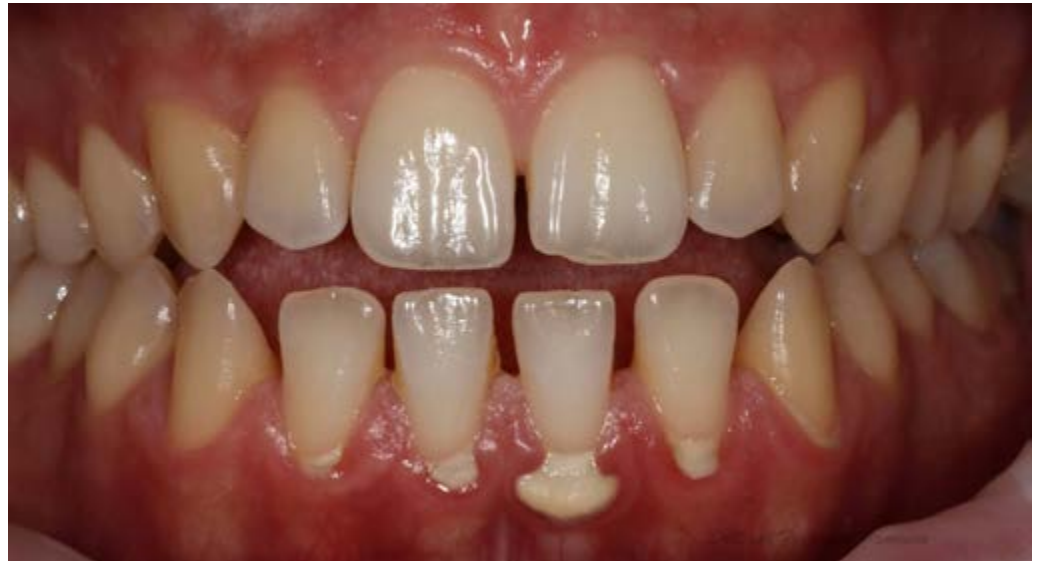PATIENT FEEDBACK

“I’M VERY VERY HAPPY!”

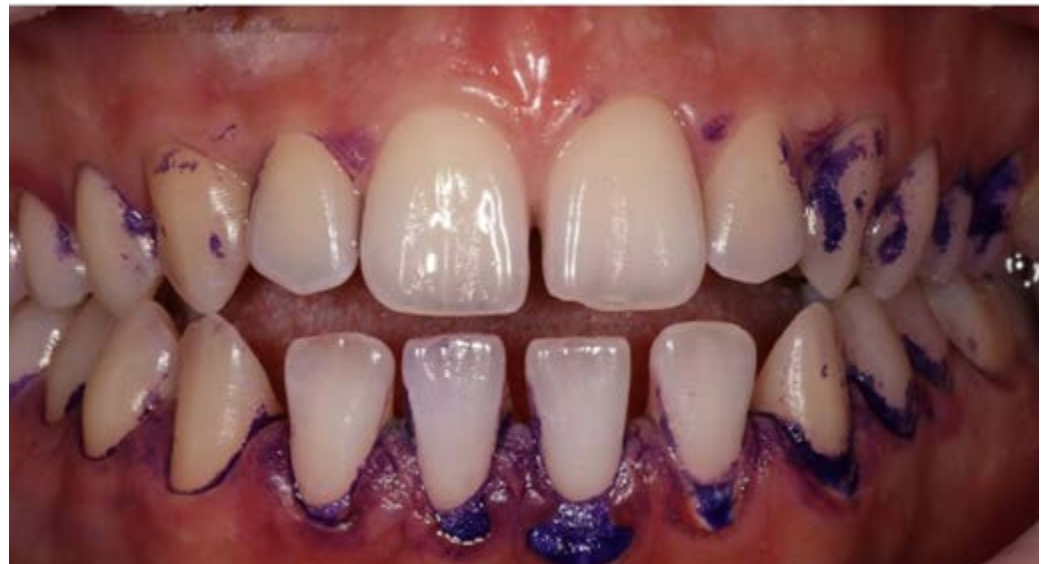PATIENT MOTIVATION



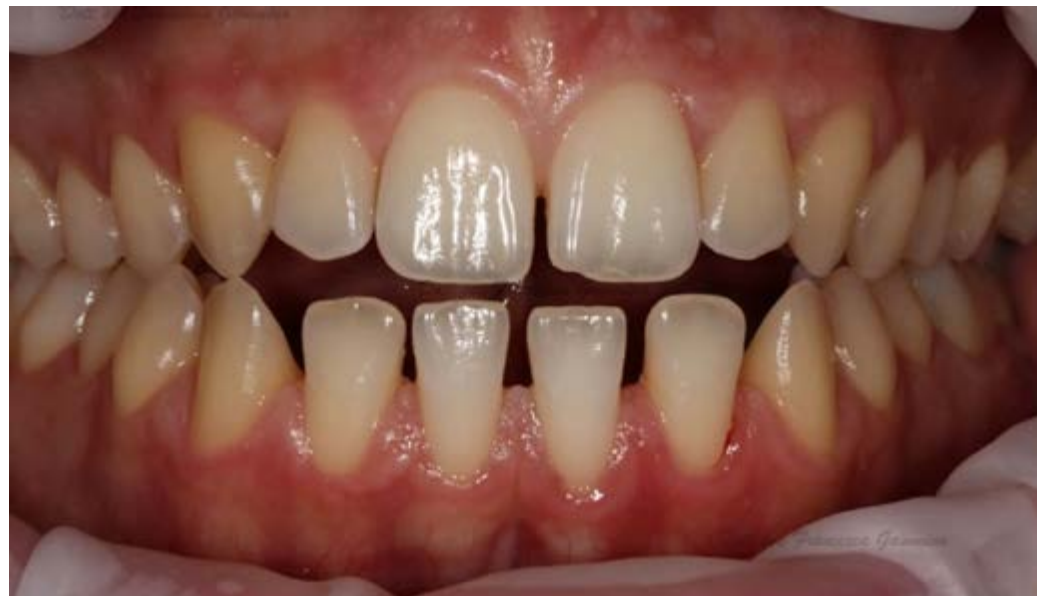BEFORE GBT



AFTER DISCLOSING



AFTER 2 WEEKS



MAINTENANCE - RECALL

CASE 43



CLINICIAN

Seo Gahye
Dental hygienist
South Korea

PATIENT INFORMATION

- ▶ Age 56, male.

BACKGROUND INFORMATION

- ▶ High blood pressure

CLINICAL FINDINGS

- ▶ Biofilm accumulation around prosthetics. Mandibular anterior and #26 subgingival calculus and BOP(+)

TREATMENT

- ▶ Oral care was continuously performed every three months, and the ability for self-management of mandible has improved compared to three months ago, but periodontal condition was still poor. Performed a full arch with GBT. Repeated teeth brushing instructions.

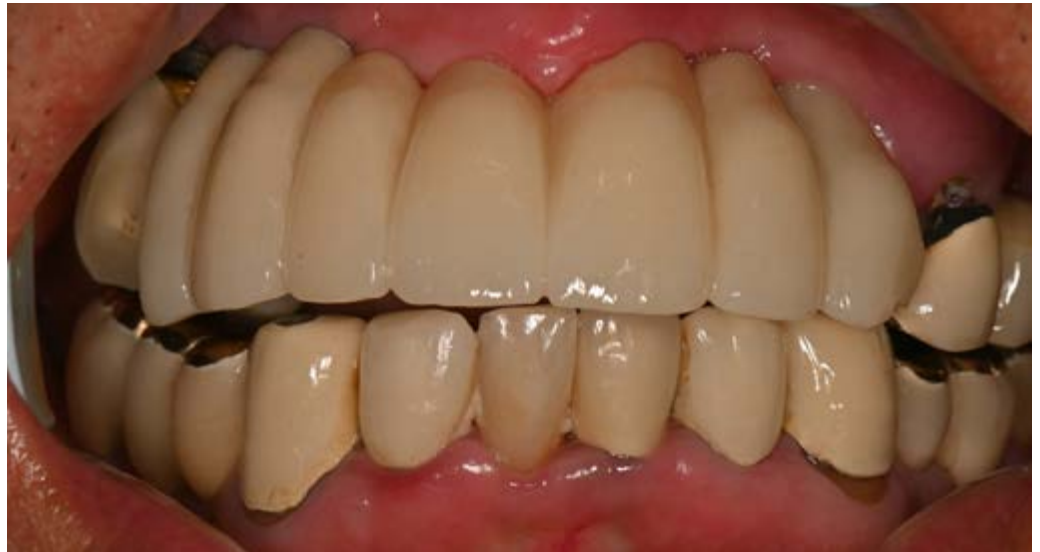PATIENT FEEDBACK

“I FEEL REFRESHED AFTER RECEIVING IT AND, I’M RELIEVED. ABOVE ALL, IT’S GREAT TO BE ABLE TO RECEIVE IT COMFORTABLY.”

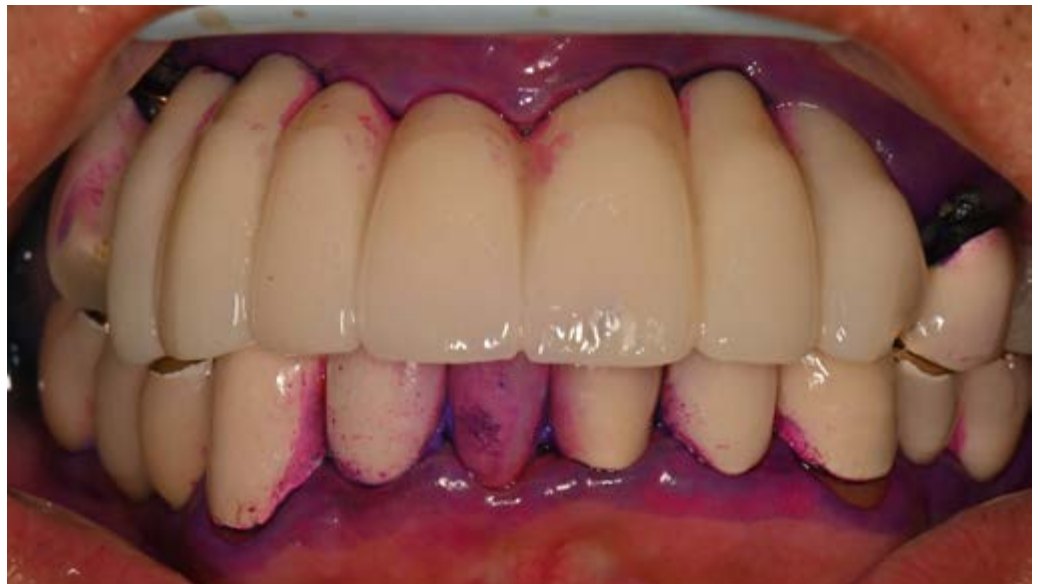PATIENT MOTIVATION



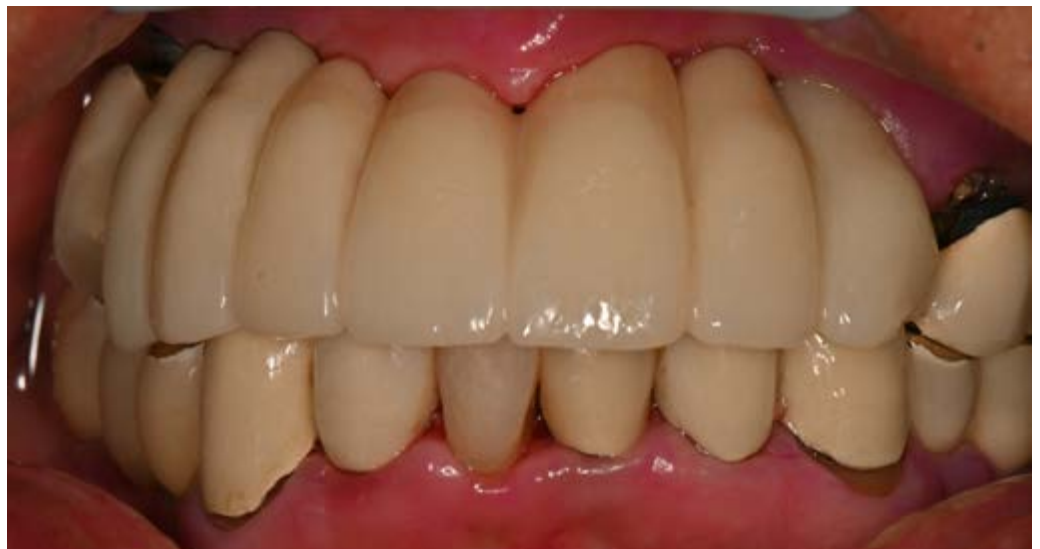BEFORE GBT



AFTER DISCLOSING



AFTER GBT



MAINTENANCE - RECALL

CASE 44



CLINICIAN

Iva Zezulova
Dental hygienist
Czech Republic

PATIENT INFORMATION

- ▶ Age 39, male.

BACKGROUND INFORMATION

- ▶ Patient was detected with sideropenic anemia. Non-smoker, without medication, healthy. Great oral care, exposed to psychological and physical issues since 10/21.

CLINICAL FINDINGS

- ▶ Due to usage of local anesthetics, rinsings and ointments during continuous period of 6 months, huge amount of pigmentations from internal and external parts of teeth was found. Aesthetic appearance of the teeth was unacceptable especially in the case of dentist. No BOP during probing.

TREATMENT

- ▶ GBT done. In this case treatment was done with AIRFLOW® PLUS Powder and AIRFLOW® Classic Comfort Powder followed by AIRFLOW® PLUS Powder. Interdental calculus was removed with PIEZON® PS Instrument.

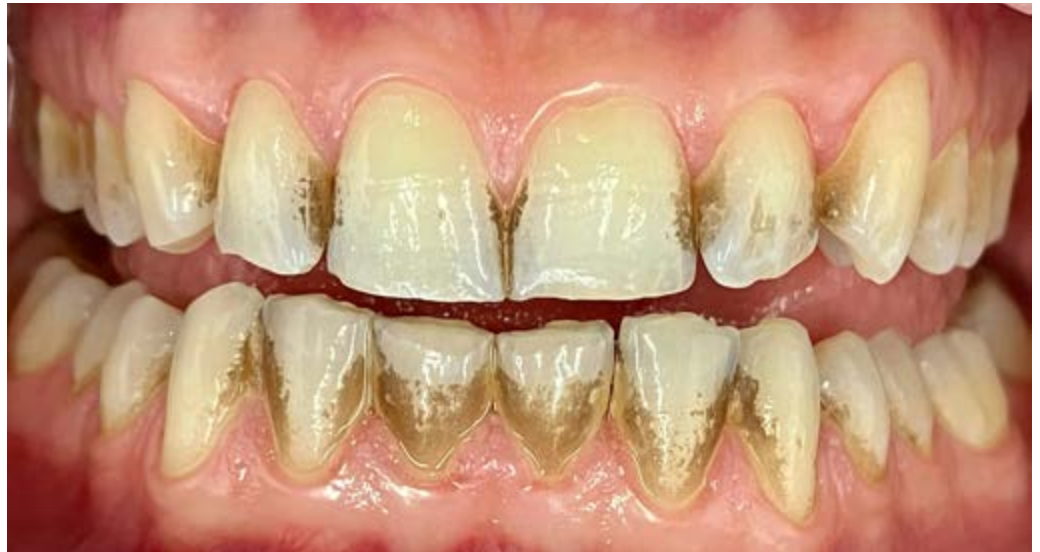PATIENT FEEDBACK

“I AM GLAD THAT STAINS AND AESTHETICS OF MY TEETH IS SOLVED.”

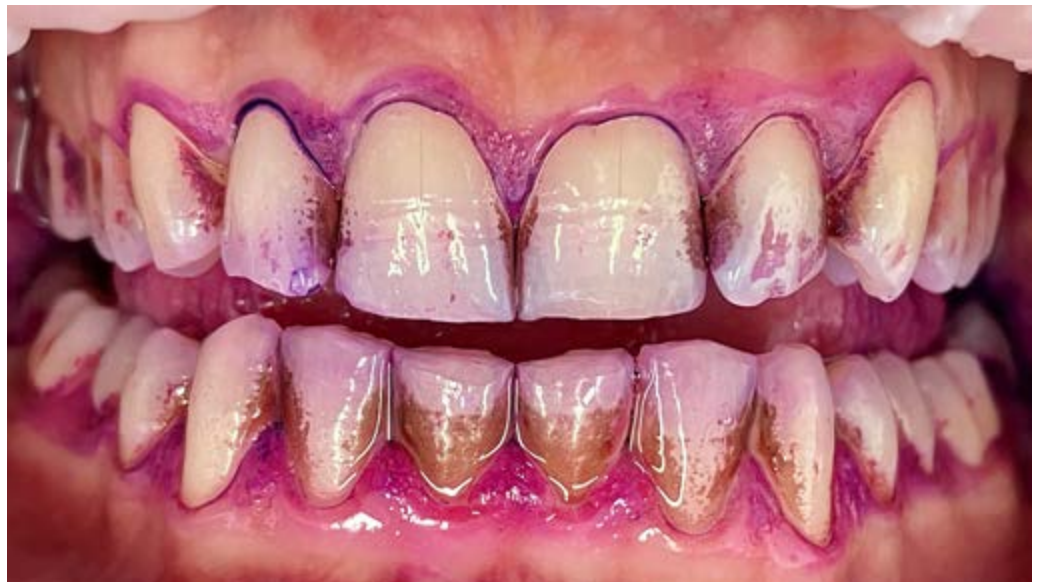PATIENT MOTIVATION



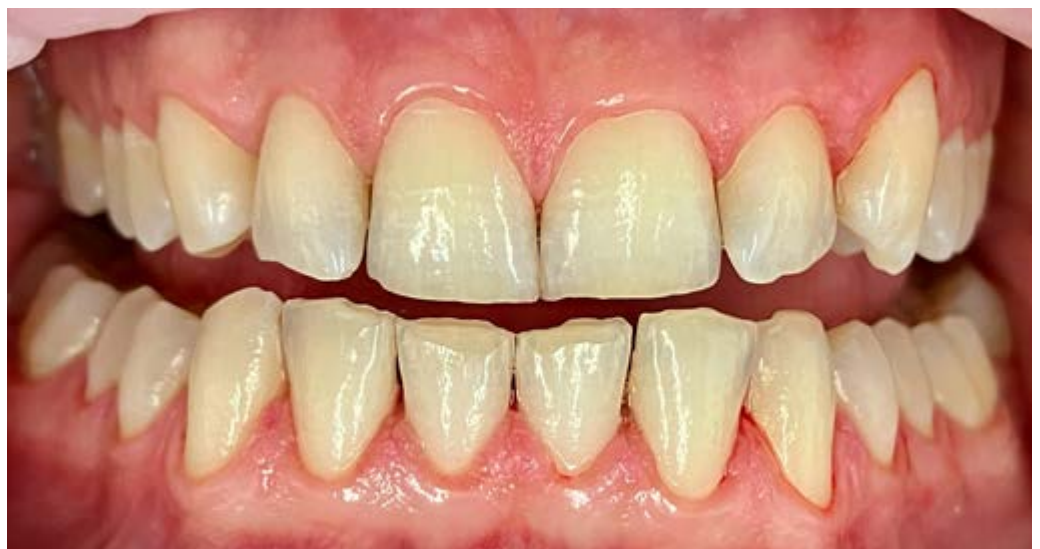BEFORE GBT



AFTER DISCLOSING



AFTER GBT



MAINTENANCE - RECALL

CASE 45



CLINICIAN

Jana Krajčiková
Dental hygienist
Czech Republic

PATIENT INFORMATION

► Age 33, male.

BACKGROUND INFORMATION

► He visits his dentist every 6 months. For dental hygiene treatment he travels 100km to my dental office because he loves GBT treatment and he prefers communication in sign language. His last GBT treatment was 1,5 years ago. He visited other dental hygiene offices when I was on maternity leave but he was not satisfied- without disclosing, without AIRFLOW®, bad communication, insufficient quality and painful treatment. Deaf, no medication, no diseases.

CLINICAL FINDINGS

► Periodontitis, active periodontal pockets 4-5mm, bleeding gums, supra + subgingival calculus, bruxism, erosion

TREATMENT

► GBT treatment with AIRFLOW® PLUS Powder and PIEZON® PS Instrument. Deaf patients often have a problem with understanding, disclosing helps a lot to understand the importance of regular dental hygiene. Thanks to disclosing, teeth cleaning instruction is easier. Patient brochure of all GBT processes is very helpful for patient home study.

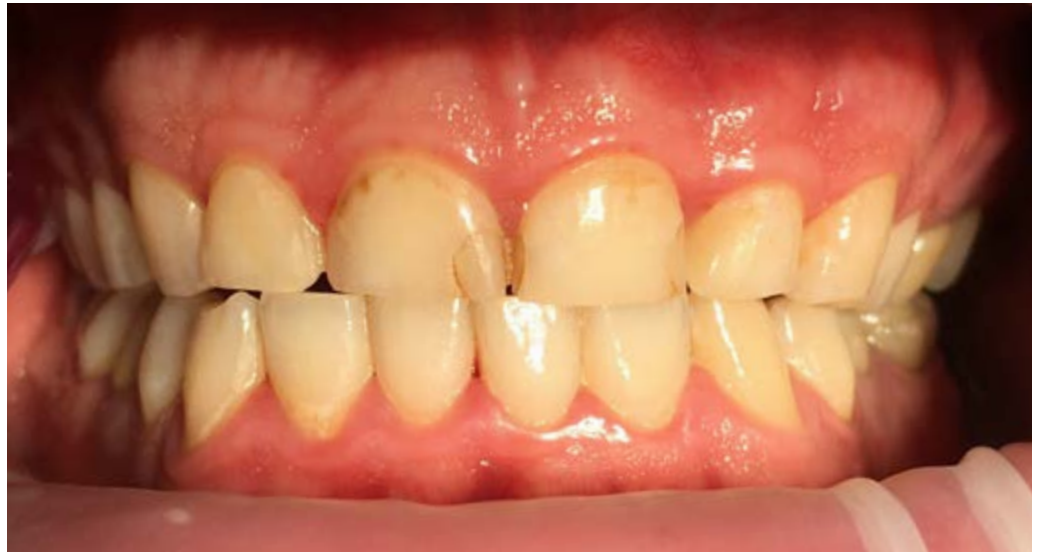PATIENT FEEDBACK

“VERY GENTLE AND QUALITY TREATMENT. I FEEL VERY GOOD. THANK YOU!”

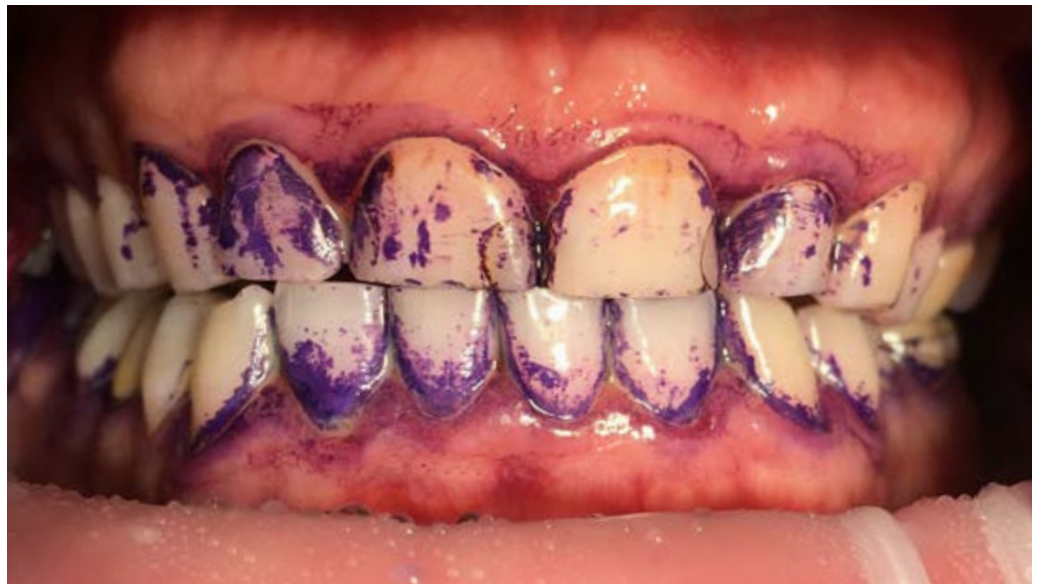PATIENT MOTIVATION



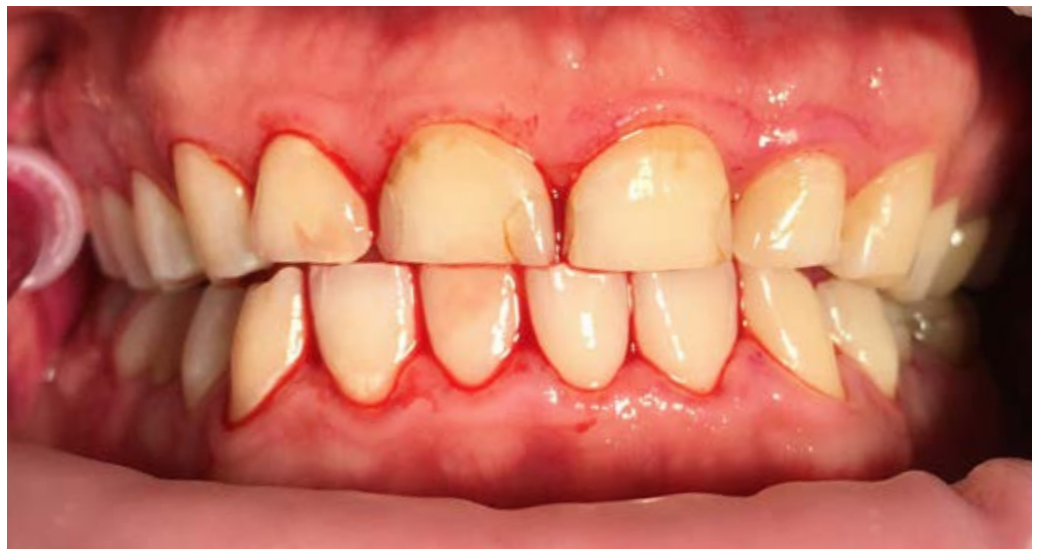BEFORE GBT



**AFTER
DISCLOSING**



AFTER GBT



MAINTENANCE - RECALL

CASE 46



CLINICIAN

Kateřina Jurenková
Dental hygienist
Czech Republic

PATIENT INFORMATION

► Age 23, female.

BACKGROUND INFORMATION

► Following orthodontic treatment, patient felt dissatisfied with her teeth after braces were removed. With low motivation to brush teeth. No significant habits.

CLINICAL FINDINGS

► Gingivitis, bleeding on probing positive, no interdental hygiene. Halitosis present. After removing braces, patient's enamel showed several small tiny scratches on all vestibular parts of teeth. So it creates places where biofilm resists.

TREATMENT

► GBT done. Patient motivated and reinstructed how to take care about her interdental places, which technique of cleaning teeth to do every day. Last but not least patient's teeth were professionally polished. Scratches on enamel were better recognized thanks to plaque detector. Patient recalled after 3 months for an evaluation.

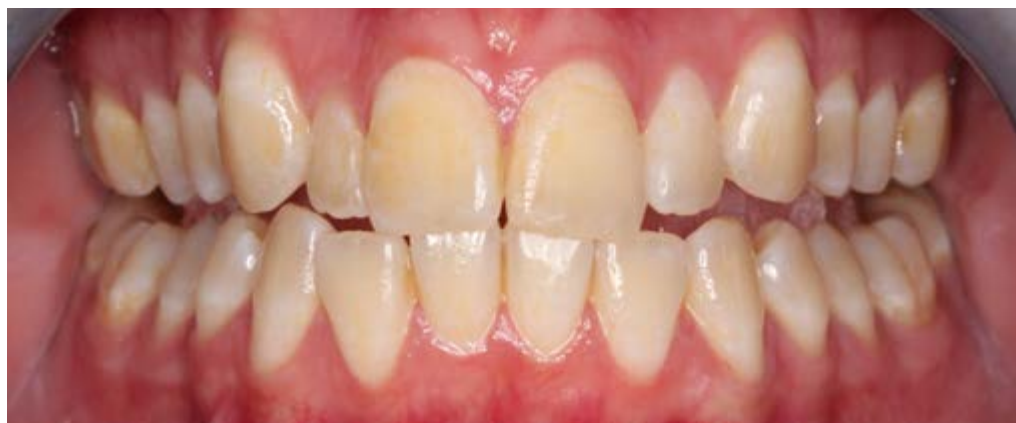PATIENT FEEDBACK

"I AM VERY SATISFIED SINCE THE TREATMENT WAS VERY COMFORTABLE."

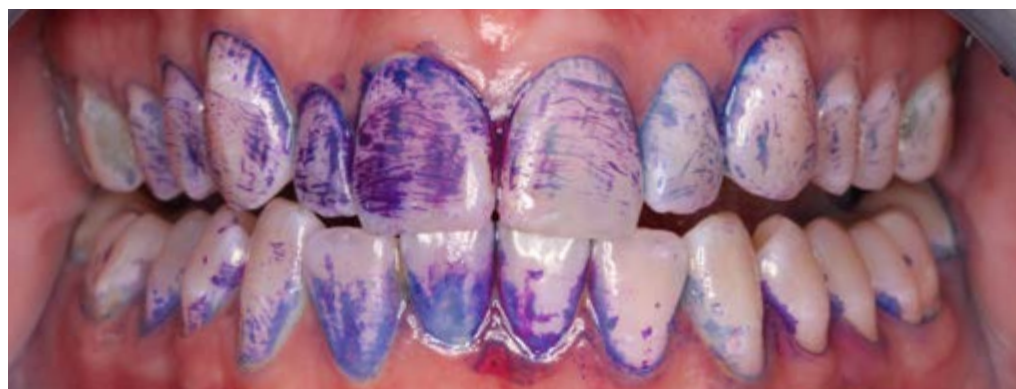PATIENT MOTIVATION



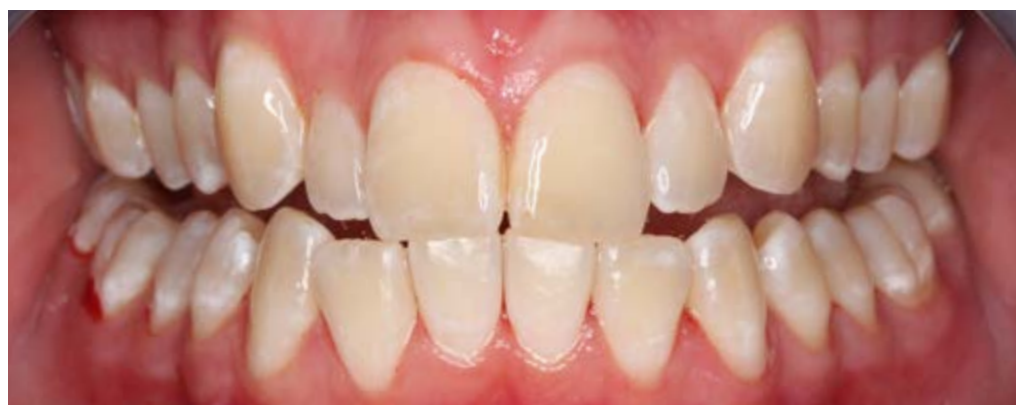BEFORE GBT



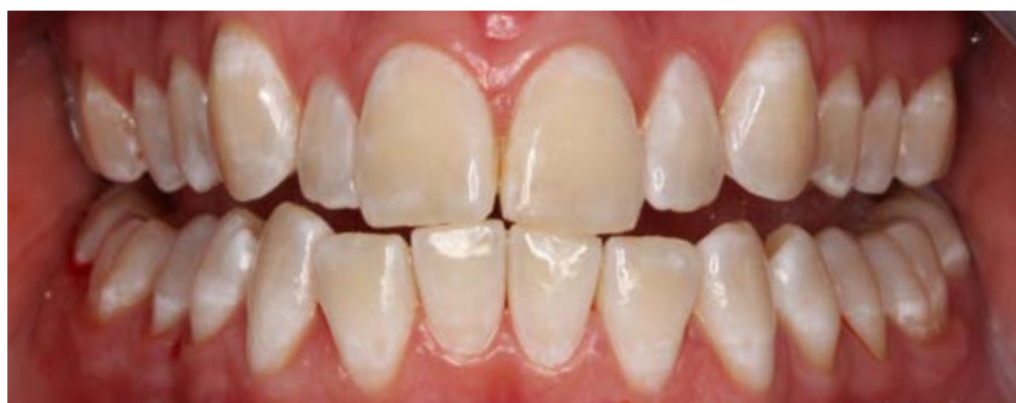AFTER DISCLOSING



AFTER GBT



3-MONTH RECALL



MAINTENANCE - RECALL

CASE 47



CLINICIAN

Khalid M Hannouneh
Dentist
UAE

PATIENT INFORMATION

- ▶ Age 25, male.

BACKGROUND INFORMATION

- ▶ Overall poor oral hygiene. History of a restorative aesthetic treatment. Different types of smoking habits (cigar, pipe, dokha).

CLINICAL FINDINGS

- ▶ BOP +, supragingival calculus present. Moderate periodontitis around the veneers. He doesn't brush his teeth regularly and doesn't use floss.

TREATMENT

- ▶ Patient was educated about the proper brushing technique and the flossing importance. GBT was done with emphasis on disclosing agent. He saw the biofilm distribution and understood the importance of GBT, correct brushing and flossing especially around the veneers. AIRFLOW® PLUS Powder was used to remove all biofilm followed by PIEZON® PS Instrument.

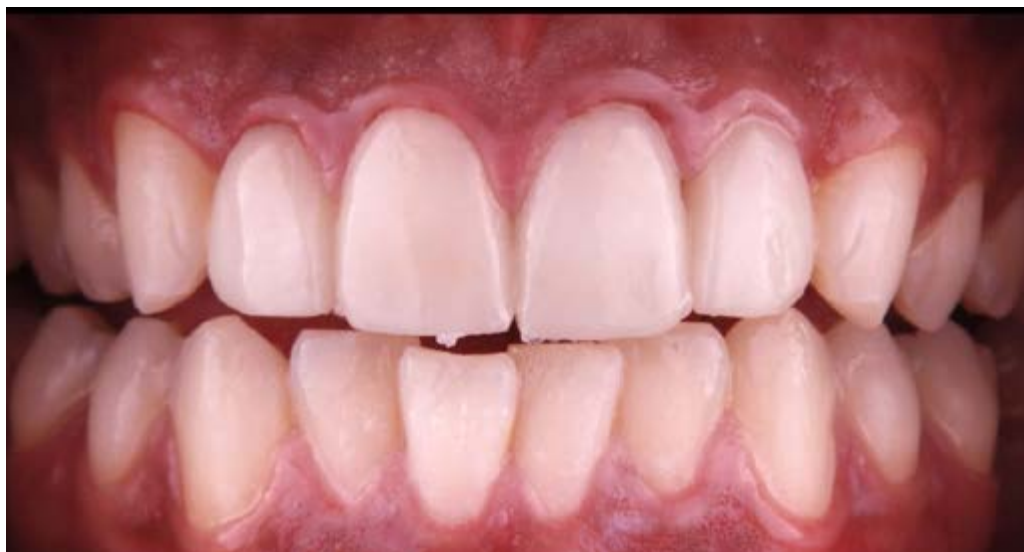PATIENT FEEDBACK

**“FINALLY MY EXPENSIVE VENEERS CAN BE SAVED
AND KEPT IN GOOD CONDITION.”**

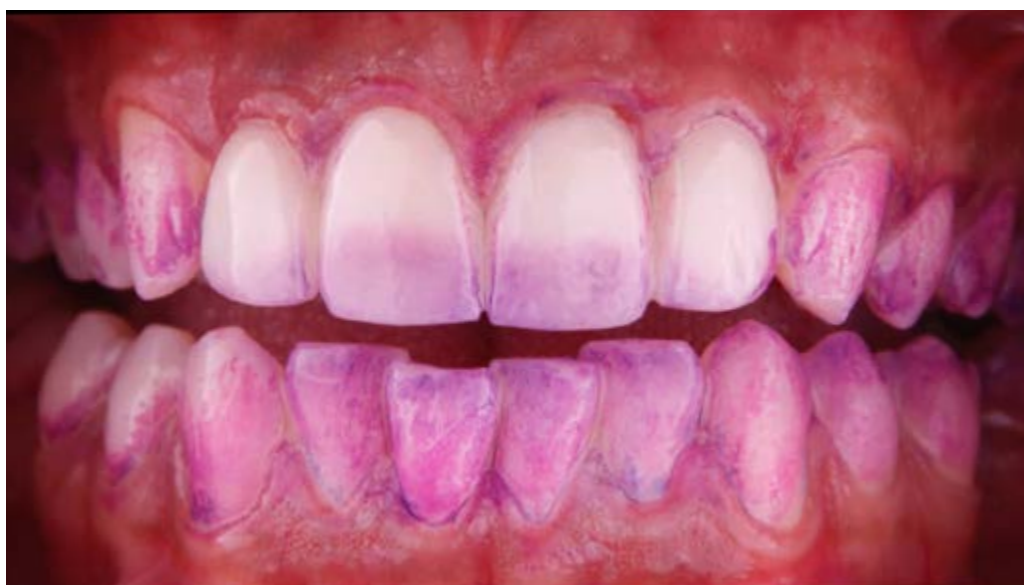PATIENT MOTIVATION



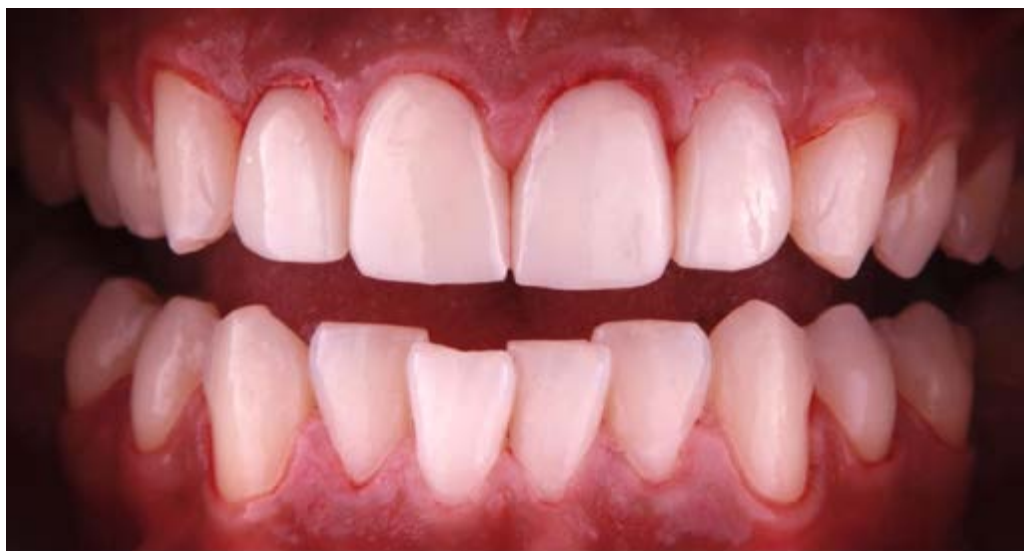BEFORE GBT



**AFTER
DISCLOSING**



AFTER GBT



MAINTENANCE - RECALL

CASE 48



CLINICIAN

Leyla Bakirova
Dentist
Azerbaijan

PATIENT INFORMATION

- ▶ Age 21, female.

BACKGROUND INFORMATION

- ▶ Poor oral hygiene. Underwent a gingivectomy, performed at two different clinics in the last few months, so she did not believe in success. Doesn't take any drugs. No relevant habits.

CLINICAL FINDINGS

- ▶ Spontaneous bleeding on probing present. Presence of gingival inflammation, supra- and subgingival calculus, stains.

TREATMENT

- ▶ Just one session GBT + 0.2% chlorhexidine mouthwash for 7 days was given. Patient put on regular recall (3 months).

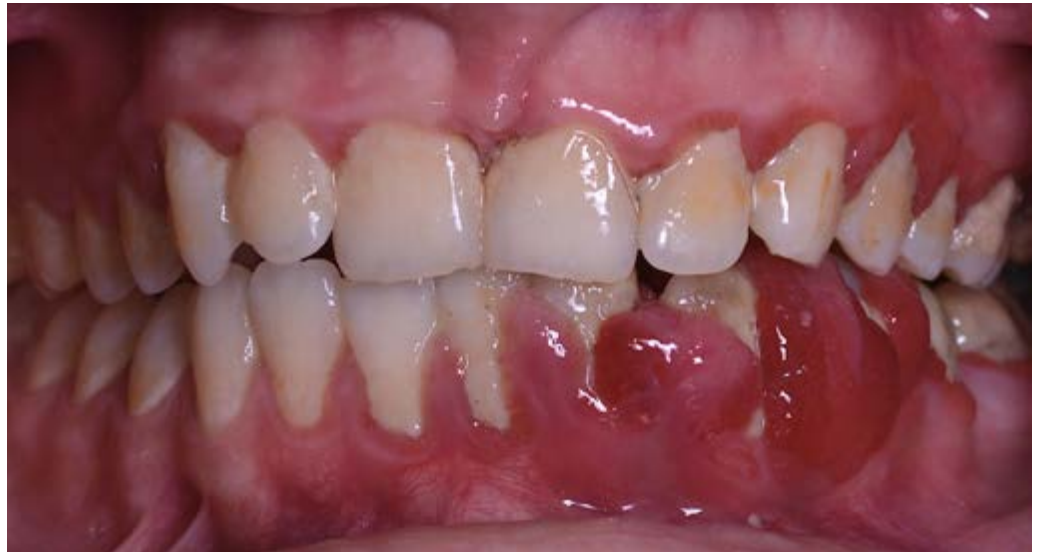PATIENT FEEDBACK

"IT'S A MIRACLE! I STILL CAN'T BELIEVE THAT EVERYTHING WILL RECOVER WITHOUT SURGERY."

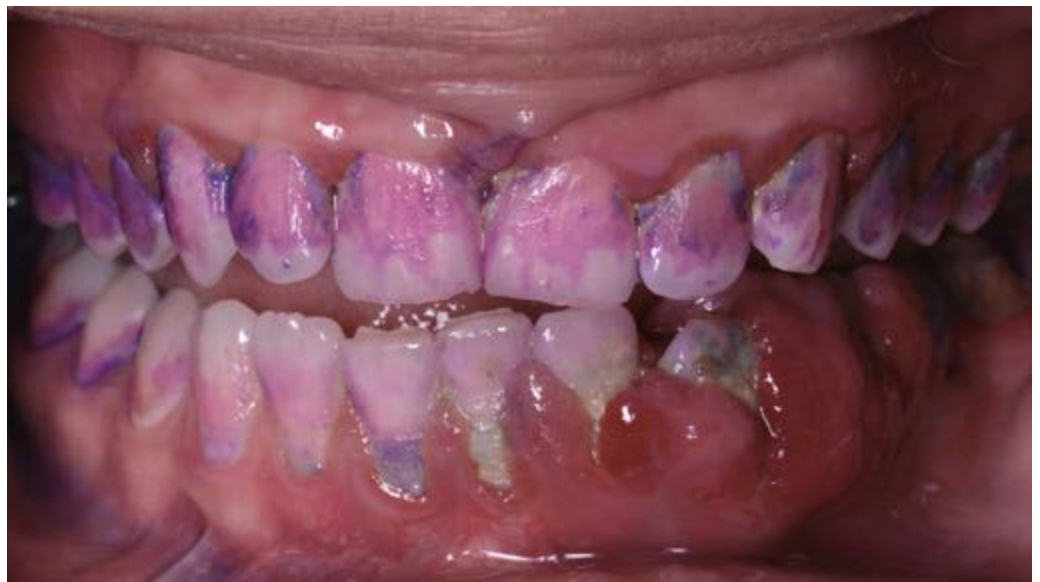PATIENT MOTIVATION



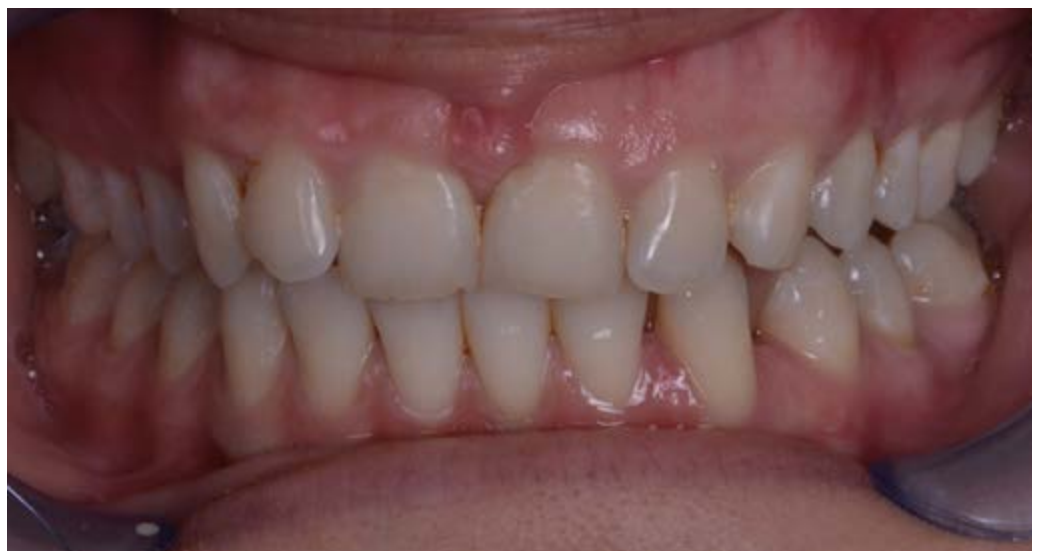BEFORE GBT



AFTER DISCLOSING



AFTER GBT



MAINTENANCE - RECALL

CASE 49



CLINICIAN

Marina Kamel
Periodontist
Australia

PATIENT INFORMATION

- ▶ Age 50, male.

BACKGROUND INFORMATION

- ▶ Non-smoker, no history of allergies, fit and healthy. He underwent periodontal debridement 3 months prior. Has come to Westside Perio and Implants for the management and ongoing maintenance of his periodontal disease for the past 6 months.

CLINICAL FINDINGS

- ▶ Generalized periodontitis stage III, grade B. Generalized plaque and supragingival calculus present. Periodontal charting revealed generalized 2-3mm PPD with 48.9% BOP. He was diagnosed to be a stable periodontitis patient with a case of gingival inflammation.

TREATMENT

- ▶ The Guided Biofilm Therapy (GBT) protocol was followed with focus on disclosing and motivation along with re-education. Using the AIRFLOW® MAX handpiece and AIRFLOW® PLUS Powder biofilm removal was done. Calculus was removed with PIEZON® PS Instrument at low power and max water. A periodontal risk assessment tool was used to determine his recall period.

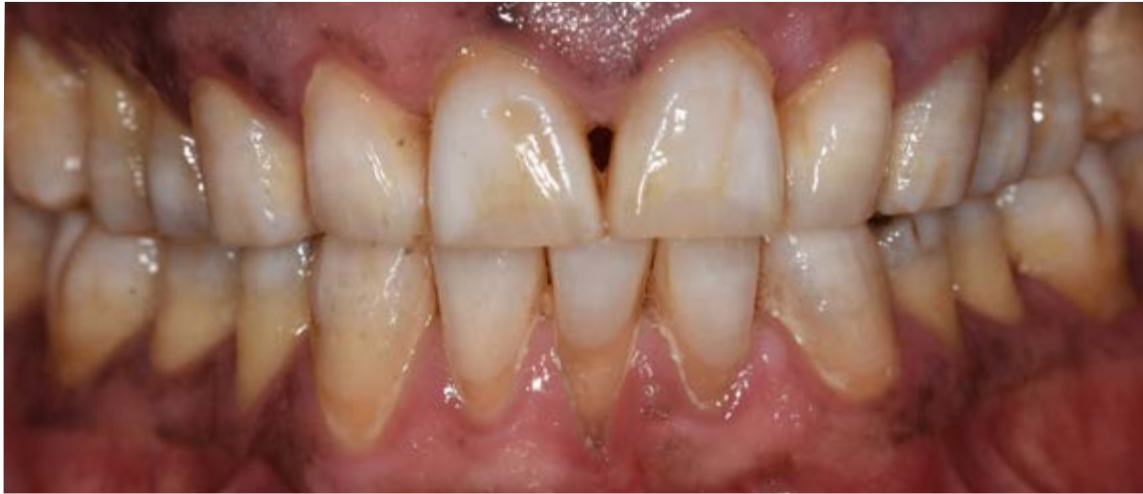PATIENT FEEDBACK

“IT IS VERY HELPFUL TO SEE THE AREAS THAT I AM MISSING WITH THE PINK AND PURPLE COLOURS. I WAS WORRIED THAT IT WILL BE SENSITIVE, BUT THE PLEASANT TREATMENT WITH WARM WATER REALLY HELPED.”

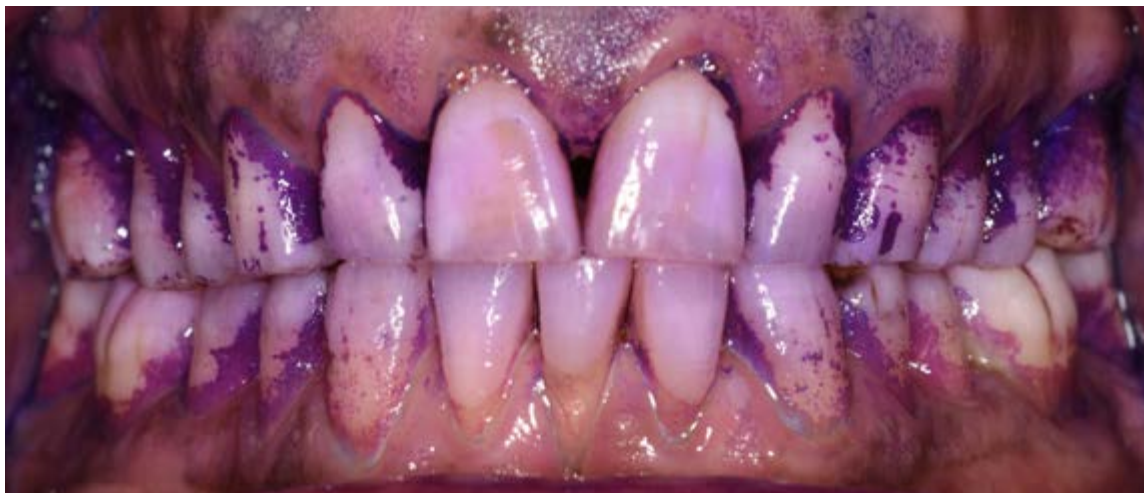PATIENT MOTIVATION



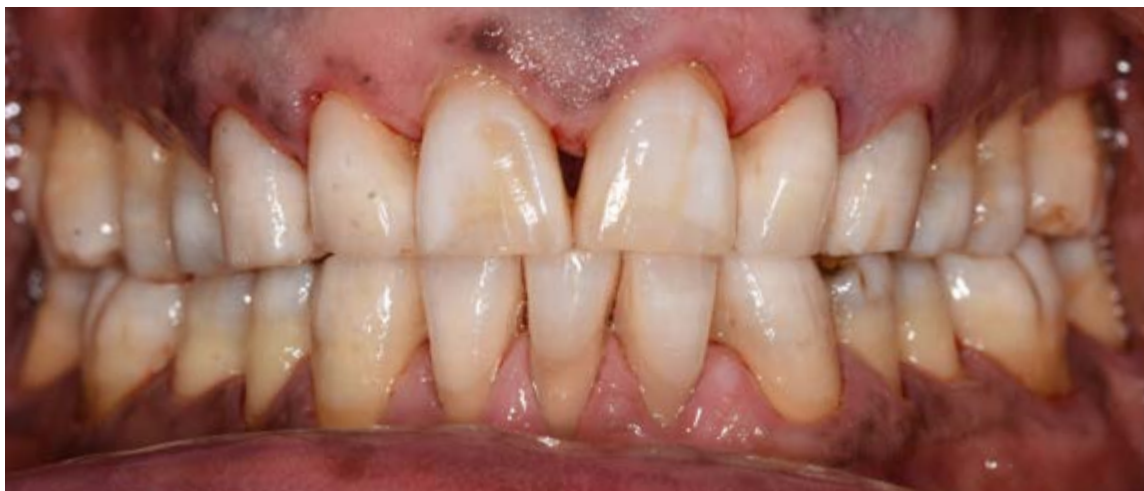BEFORE GBT



AFTER DISCLOSING



AFTER GBT



MAINTENANCE - RECALL

CASE 50



CLINICIAN

Marleen Goossen
Dental hygienist
Netherlands

PATIENT INFORMATION

- ▶ Age 53, female.

BACKGROUND INFORMATION

- ▶ Diet no details, Oral hygiene is reasonable, Always brushes with manual toothbrush, since 2021 electric toothbrush, last advice was to place toothbrush right against the gingival margin. Many composite restorations present in the front. Culture taken for candida, negative result. Healthy, no medicines, non-smoker.

CLINICAL FINDINGS

- ▶ Gingivitis; many visible stains; little or no calculus.

TREATMENT

- ▶ Just one GBT session. Patient put on regular recall (6 months).

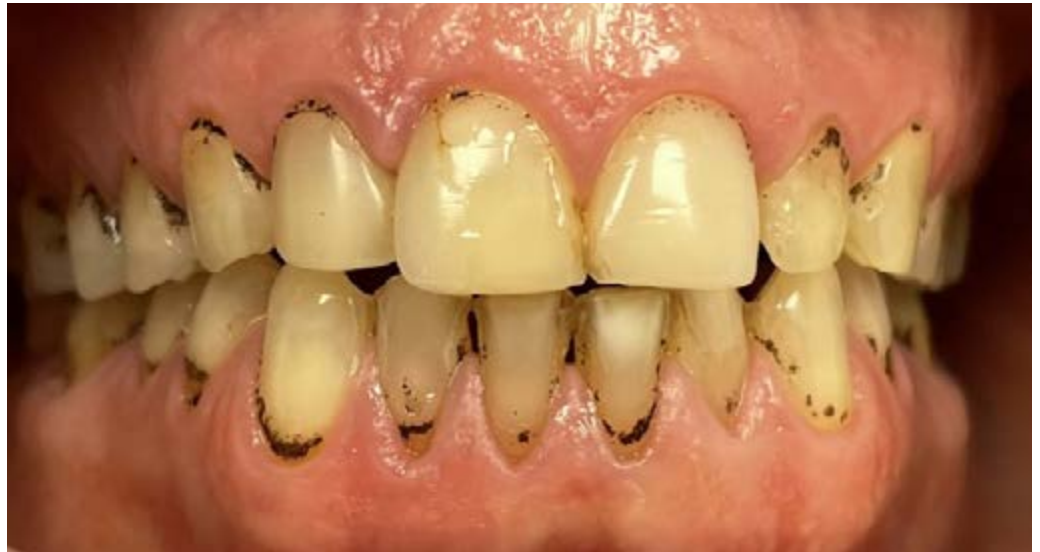PATIENT FEEDBACK

“I FEEL CLEAN. TREATMENT WAS GREAT. THANK YOU!”

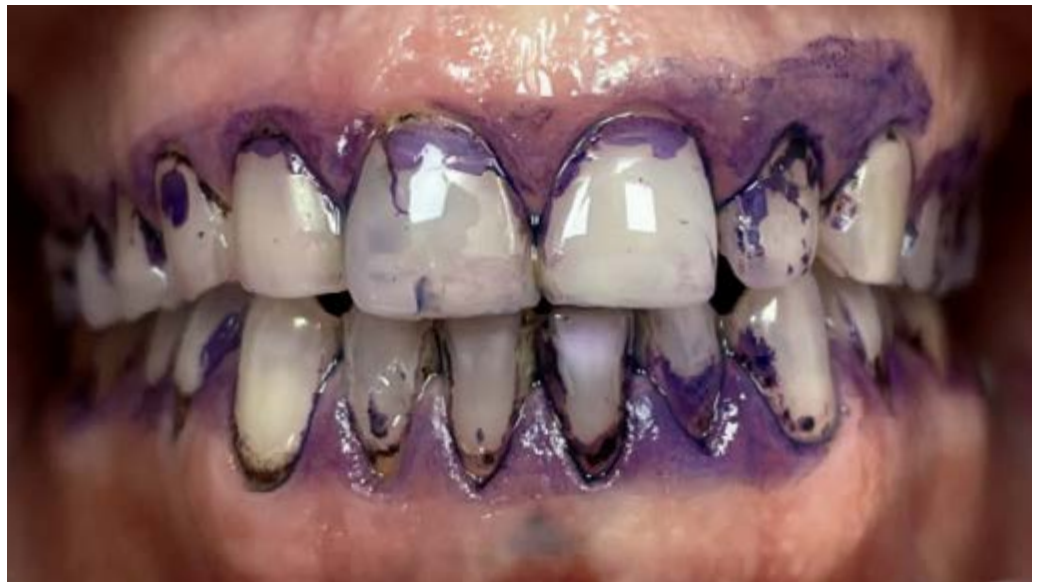PATIENT MOTIVATION



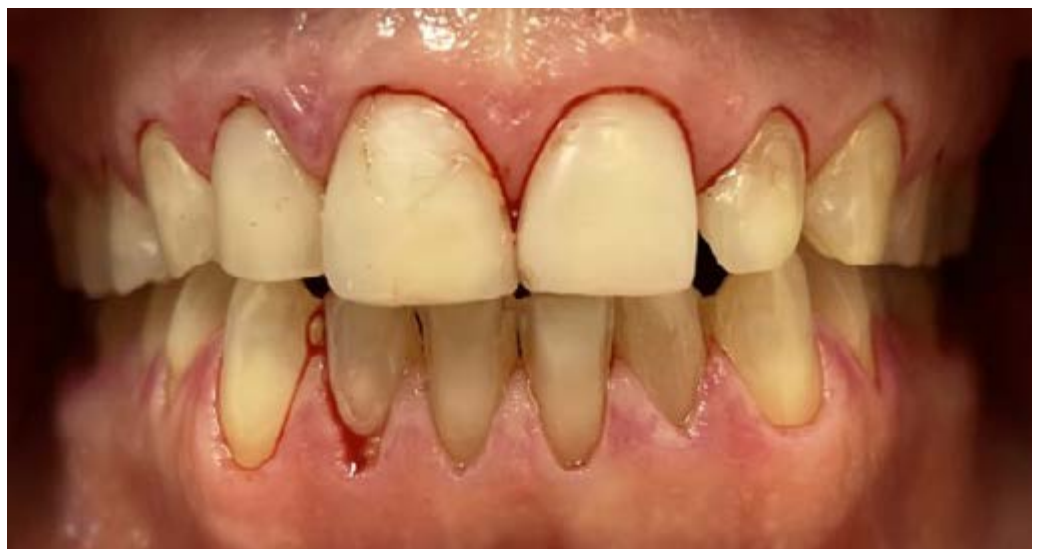BEFORE GBT



AFTER DISCLOSING



AFTER GBT



MAINTENANCE - RECALL

CASE 51



CLINICIAN

Michal Herzina
Dental hygienist
Czech Republic

PATIENT INFORMATION

- ▶ Age 43, female.

BACKGROUND INFORMATION

- ▶ The patient regularly undertakes dental hygiene, but never tried the GBT protocol. The patient is aware that due to unfavorable positioning of her teeth in the frontal area, her oral hygiene is not completely perfect. She is constantly considering the option of orthodontic treatment.

CLINICAL FINDINGS

- ▶ Gingival recession on left central incisor, no periodontal pockets, very small amounts of tartar present.

TREATMENT

- ▶ Plaque disclosing with GC Tri-plaque ID gel. Then the patient showed areas which she could not clean specifically the interdental areas. The patient was instructed with usage of dental aids. In addition to the classic dental aids that the patient already uses, the patient was also shown how to use an expanding floss, which helps the patient clean hard-to-reach places. AIRFLOW® PLUS Powder was used to remove stained deposits. PIEZON® PS Instruments were used to remove small deposits of tartar. In addition, recalls were recommended to the patient every 6 months hereafter.

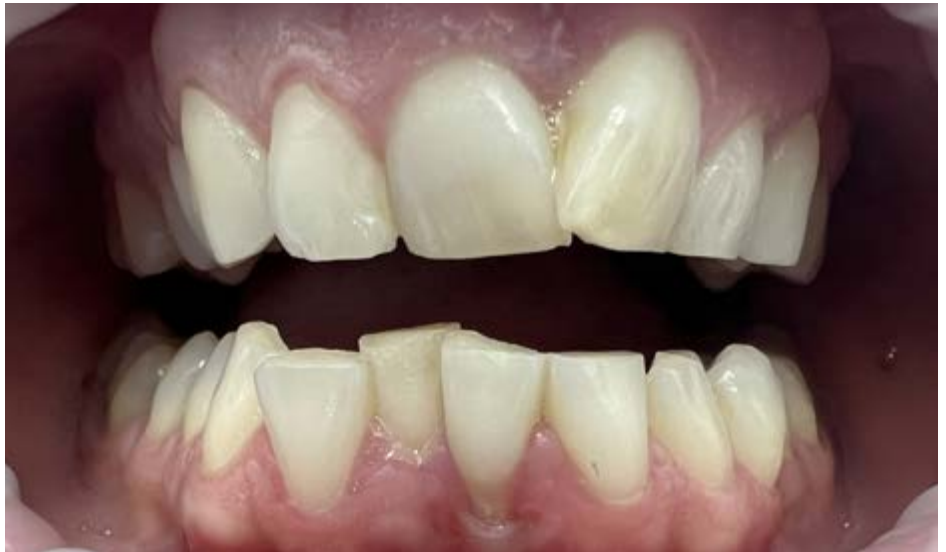PATIENT FEEDBACK

“DENTAL HYGIENE HAS TAKEN ON A WHOLE NEW MEANING FOR ME. I’M THRILLED. I THOUGHT I CLEANED BETTER THAN WHAT THE HYGIENE HAS ACTUALLY SHOWN. I HIGHLY RECOMMEND IT.”

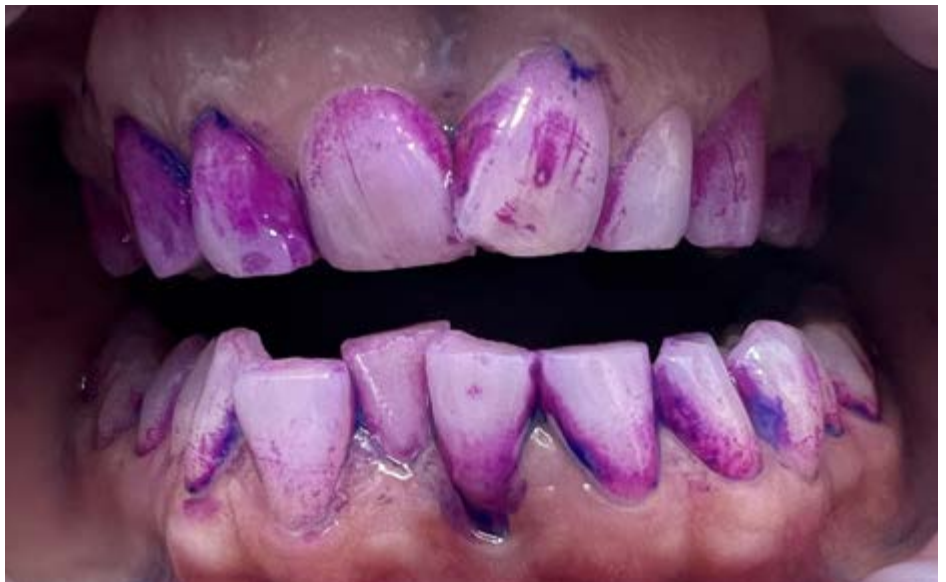PATIENT MOTIVATION



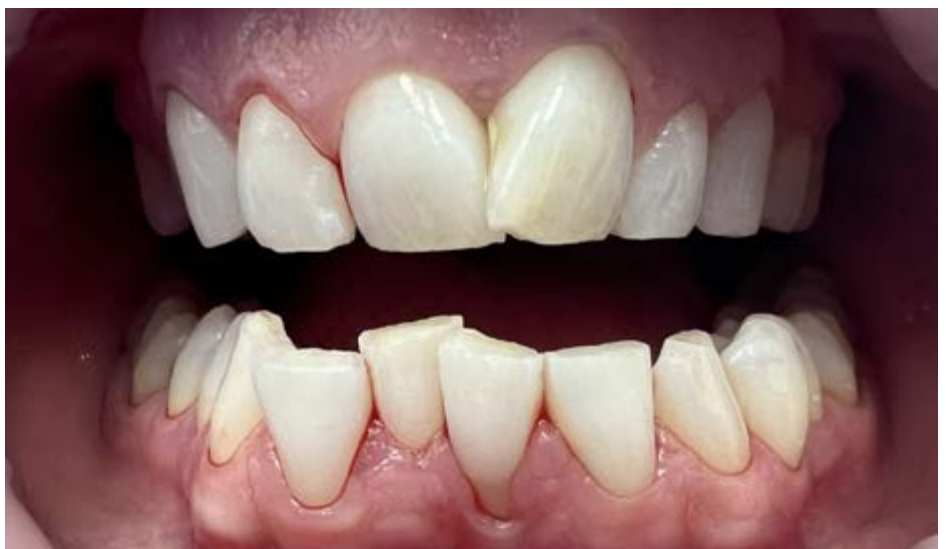BEFORE GBT



**AFTER
DISCLOSING**



AFTER GBT



MAINTENANCE - RECALL

CASE 52



CLINICIAN

Míriam Torrejón Ayala
Dental hygienist
Spain

PATIENT INFORMATION

- ▶ Age 35, male.

BACKGROUND INFORMATION

- ▶ Poor oral hygiene. Never visited a dental clinic in the last 4-5 years because past experiences have horrified him. He was scared with the place and noise of a dental clinic. No relevant habits present. Does not have dental hygiene habits.

CLINICAL FINDINGS

- ▶ Generalized gingivitis. BOP+ >30% (Bleeding on Probing) with few 4mm pockets. Supra- and subgingival calculus +++. Halitosis present. Inability to clean interproximal areas.

TREATMENT

- ▶ Start by rinsing with BacterX® Pro mouthwash. Plaque disclosing and evaluation was done using Discloser® and the patient was shown images of the teeth and the areas of poor plaque control. The patient was given additional instruction on the most appropriate techniques for removing the plaque and this was demonstrated in the surgery. AIRFLOW® MAX with the AIRFLOW® PLUS® Power removing biofilm, early calculus and stains. Removing remaining calculus supra- and subgingivally with PIEZON® PS Instrument. Do a final check for remaining biofilm and ensure calculus is fully removed. Applied protection layer with fluoride. The patient will return every 6 months. I will ask him if he liked the treatment.

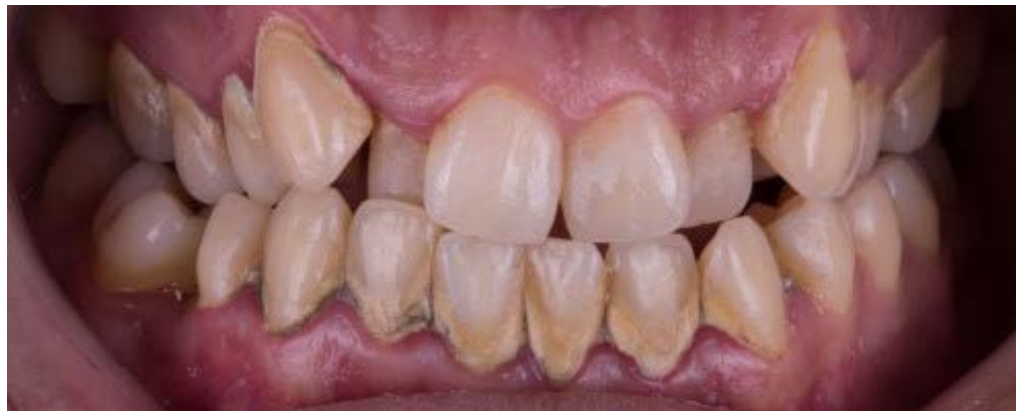PATIENT FEEDBACK

“IT IS THE BEST TREATMENT I HAVE RECEIVED IN MY LIFE. IT IS VERY COMFORTABLE AND PLEASANT. I WILL NEVER GO BACK TO AN OLD SYSTEM.”

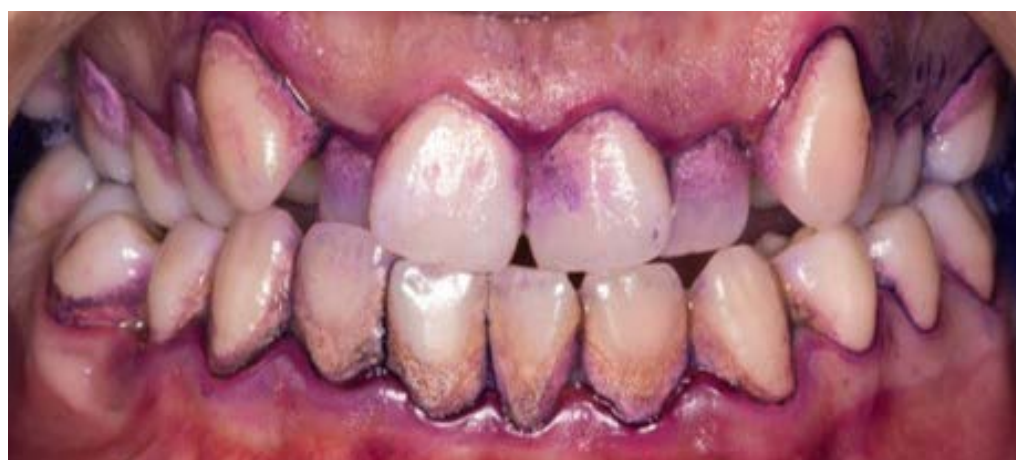PATIENT MOTIVATION



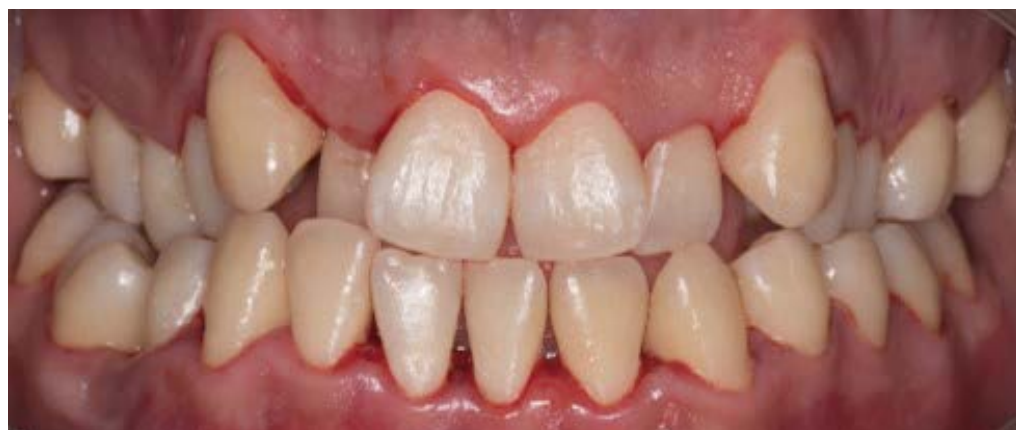BEFORE GBT



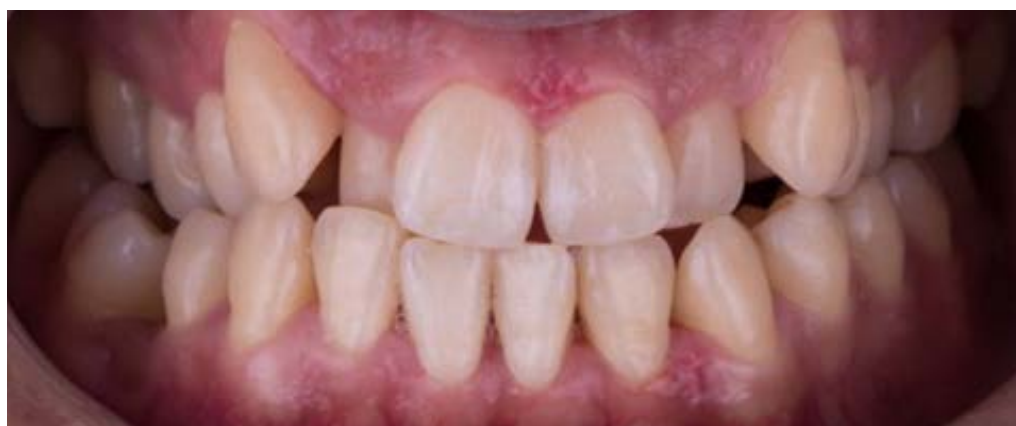**AFTER
DISCLOSING**



AFTER GBT



**6-MONTH
RECALL**



MAINTENANCE - RECALL

CASE 53



CLINICIAN

Neha Dixit
Periodontist
Switzerland

PATIENT INFORMATION

- ▶ Age 65, male.

BACKGROUND INFORMATION

- ▶ History of poor oral hygiene, lack of motivation, no time to brush.

CLINICAL FINDINGS

- ▶ Bleeding on probing +. Presence of calculus. Lots of biofilm on disclosing.

TREATMENT

- ▶ GBT was performed with emphasis on each step. Patient was instructed, motivated, re-educated on oral hygiene. Recall showed drastic improvement in the plaque score.

PATIENT FEEDBACK

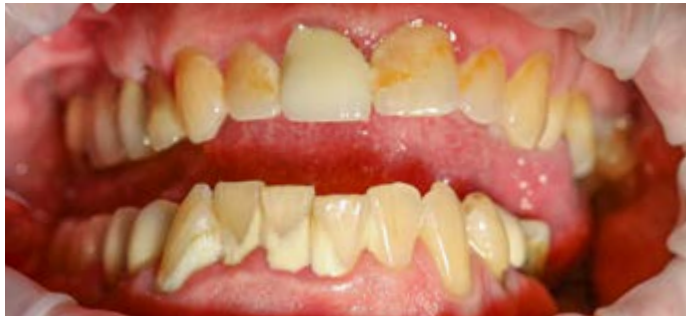“THANK YOU FOR THE TIME WITH ALL THE EXPLANATION. IT’S ONLY BECAUSE OF THE TREATMENT YOU GAVE ME WHICH WAS SO COMFORTABLE THAT I FEEL MOTIVATED TO BRUSH AND MAINTAIN MY ORAL HYGIENE. WILL SEE YOU VERY SOON.”

PATIENT MOTIVATION

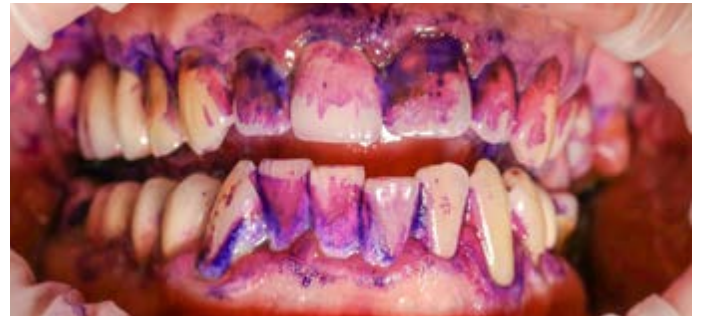

FIRST APPOINTMENT

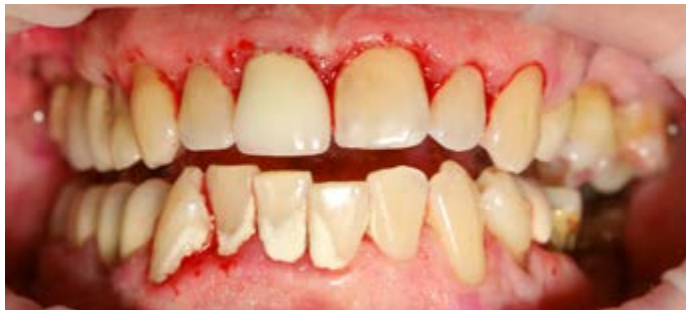BEFORE GBT



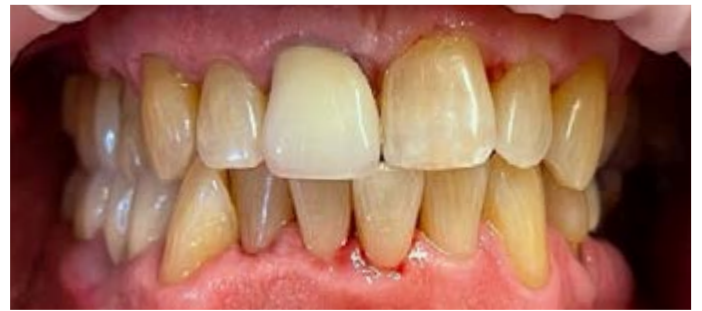AFTER DISCLOSING



AFTER AIRFLOW®

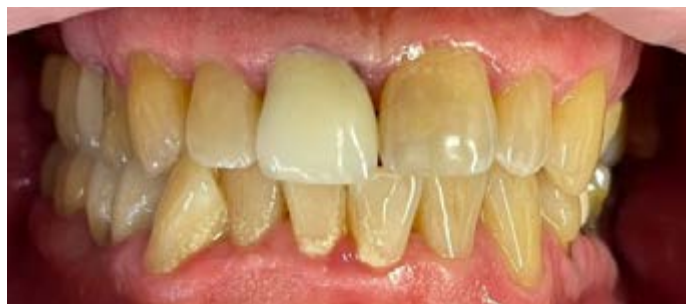

AFTER GBT

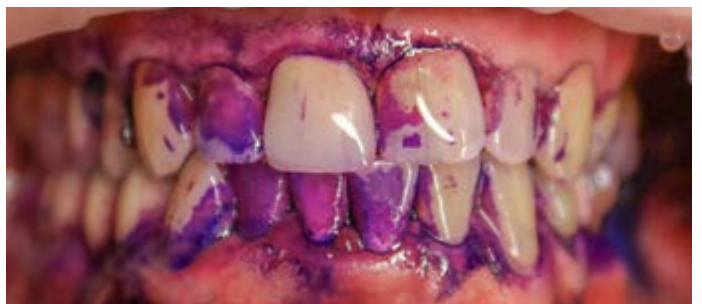

RECALL AFTER 1 YEAR

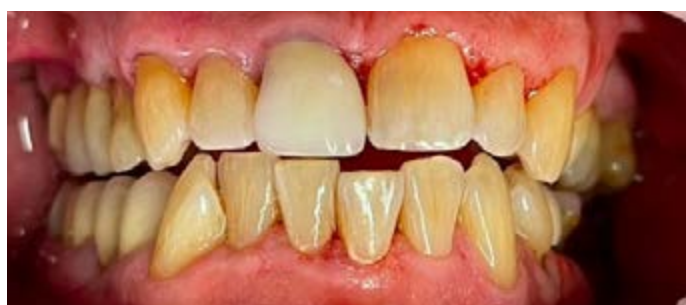BEFORE GBT



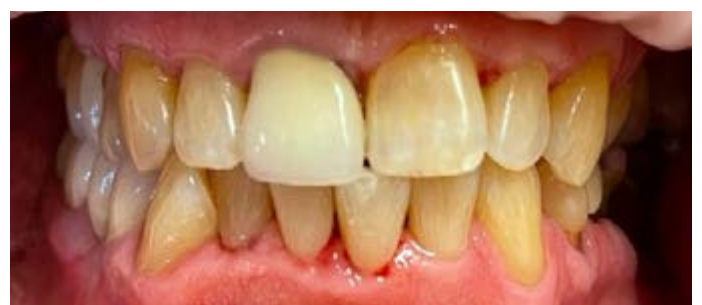AFTER DISCLOSING



AFTER AIRFLOW®



AFTER GBT



MAINTENANCE - RECALL

CASE 54



CLINICIAN

Nicole Stevanello
Dental hygienist
Italy

PATIENT INFORMATION

- ▶ Age 32, male.

BACKGROUND INFORMATION

- ▶ Poor oral hygiene. Patient on a regular GBT recall every 3 months.
No relevant habits.

CLINICAL FINDINGS

- ▶ Presence of light stains, plaque and calculus mostly in the lower anteriors.

TREATMENT

- ▶ GBT was done with AIRFLOW® PLUS Powder to remove all biofilm and stains followed by PIEZON® PS Instrument to remove calculus.

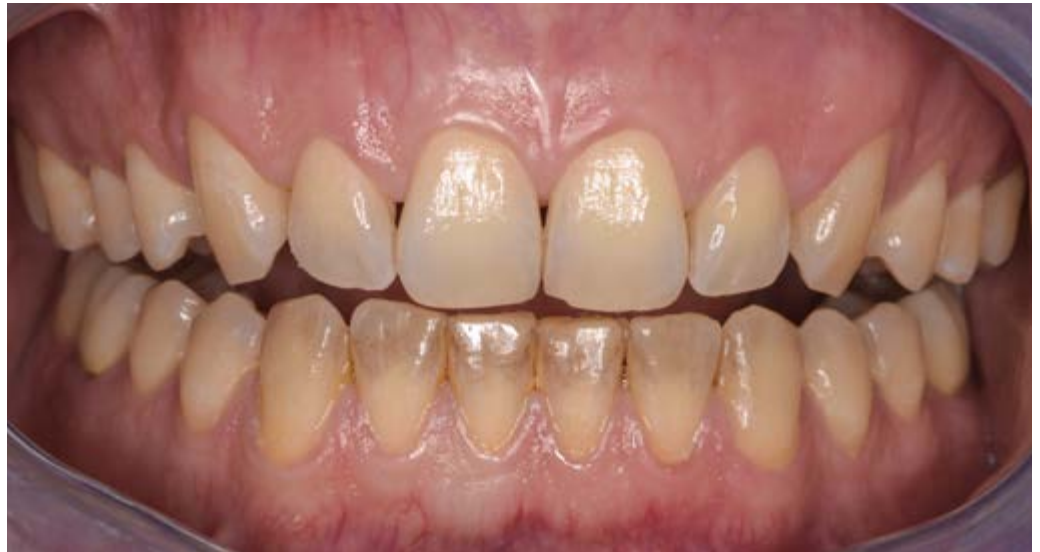PATIENT FEEDBACK

“NO PAIN, HAPPY AND READY TO SMILE!!”

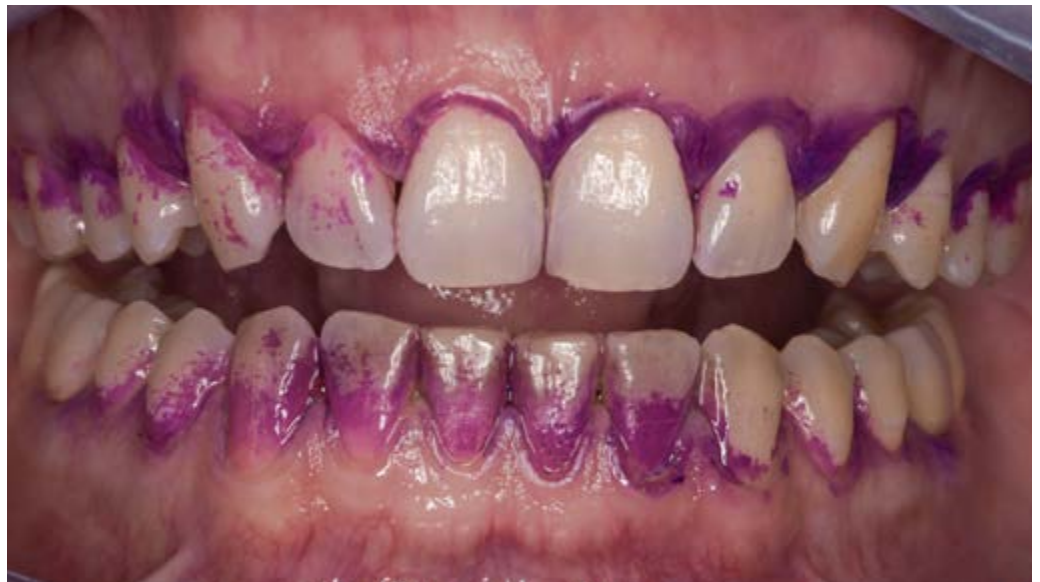PATIENT MOTIVATION



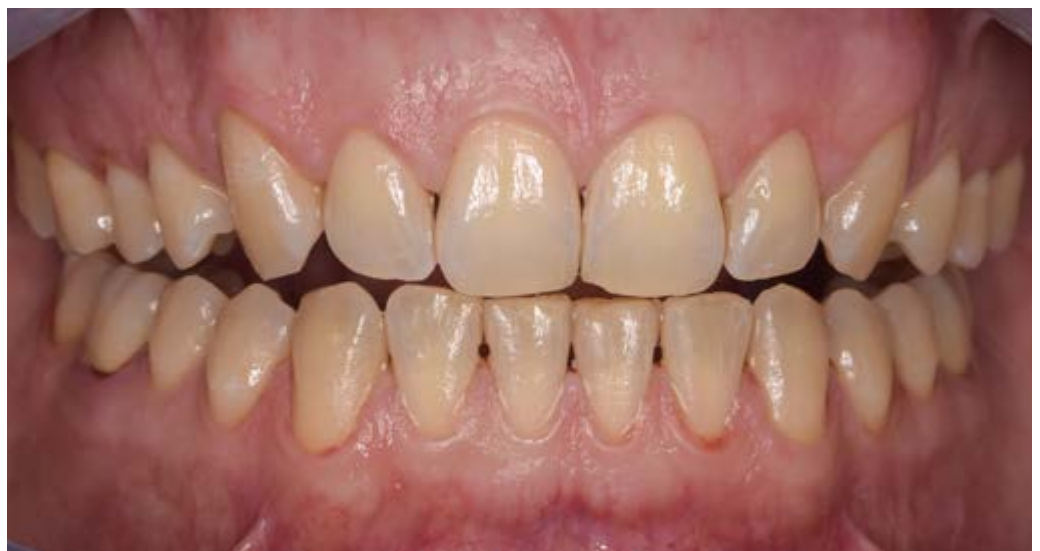BEFORE GBT



AFTER DISCLOSING



AFTER GBT



MAINTENANCE - RECALL

CASE 55



CLINICIAN

Olga Grabowska
Dental hygienist
Poland

PATIENT INFORMATION

- ▶ Age 49, male.

BACKGROUND INFORMATION

- ▶ Patient has hypothyroidism, open bite, mouth breather. Tense facial muscles with a large tongue. The patient drinks large quantities of carbonated drinks and sweetened fruit juices.

CLINICAL FINDINGS

- ▶ Inflammation of the gums, supragingival calculus, lack of subgingival calculus and pockets more than 4 mm, moderate bleeding when probing. Numerous decalcifications on the cervical surfaces, resulting from insufficient home hygiene and incorrect eating habits.

TREATMENT

- ▶ GBT protocol, using only AIRFLOW® PLUS Powder. The patient was instructed on the correct brushing technique (manual brush, soft alternating with an electric toothbrush on a gentle mode). Another recall visit was scheduled in 4 months.

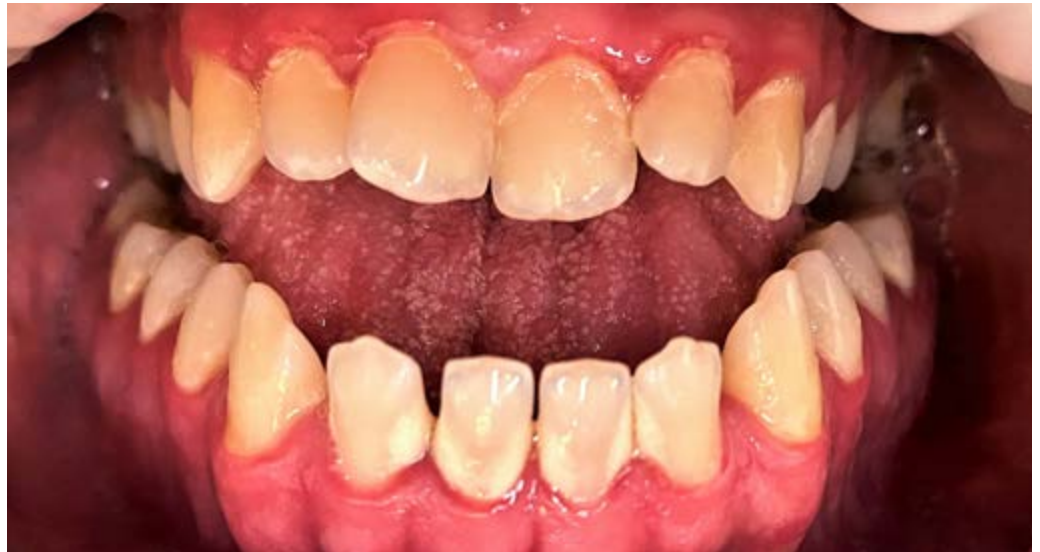PATIENT FEEDBACK

“GBT MADE ME REALIZE AREAS WHERE I NEED TO CLEAN BETTER. THE WATER DURING THE PROCEDURE IS WARM, MAKING IT A PLEASANT FEELING. I AM HAPPY TO RETURN TO THE DATES SET BY THE HYGIENIST. THE CONDITION OF MY GUMS AND TEETH HAS IMPROVED A LOT.”

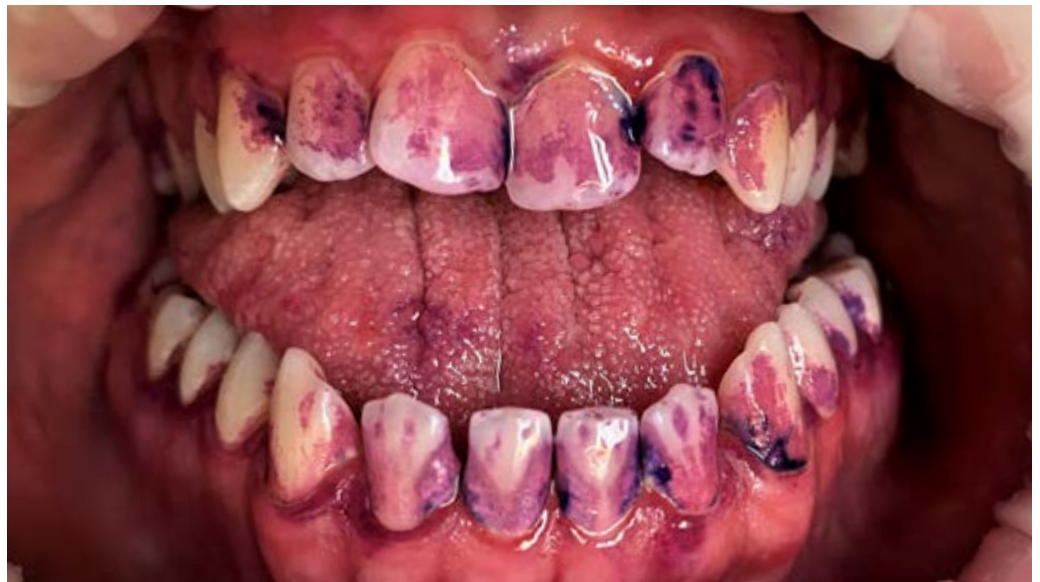PATIENT MOTIVATION



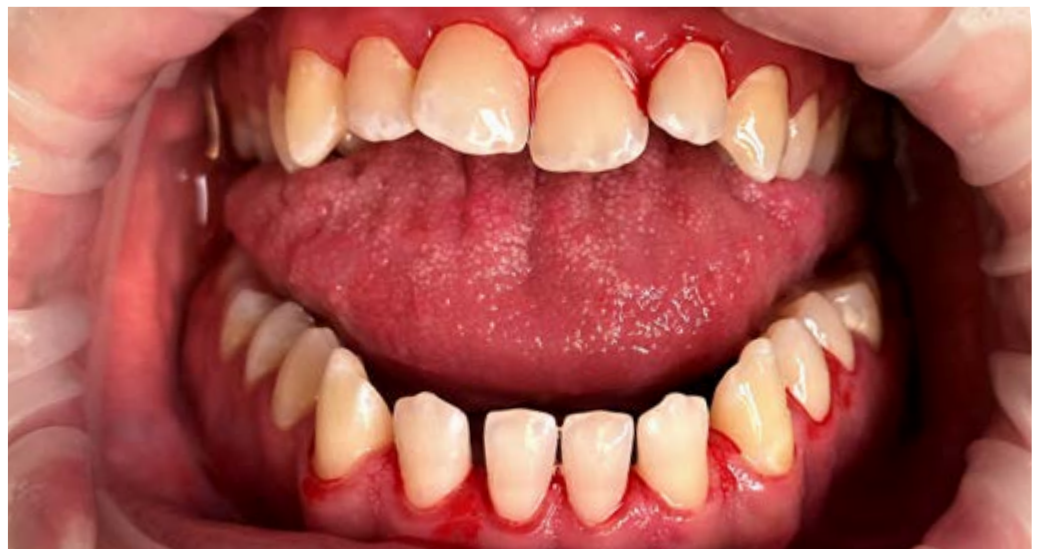BEFORE GBT



AFTER DISCLOSING



AFTER GBT



MAINTENANCE - RECALL

CASE 56



CLINICIAN

Rosario Maria Rodriguez Pichardo
Dental hygienist
Spain

PATIENT INFORMATION

- ▶ Age 37, female.

BACKGROUND INFORMATION

- ▶ Patient with gingivitis, she presents both subgingival and supragingival plaque. Does not maintain good oral hygiene, does not use interproximal brushes or dental tape. The patient has gingival overgrowth in the upper incisors but does not want to undergo a gingivectomy. She lost molars a few years ago. She smokes and has cardiovascular disease, in addition to being overweight. She visits the dentist every 3 or 4 years. Bleeding gums and halitosis.

CLINICAL FINDINGS

- ▶ No deep periodontal pockets. Heavy bleeding only when applying air. Generalized supragingival and subgingival calculus.

TREATMENT

- ▶ GBT performed with AIRFLOW® PLUS Powder and PIEZON® PS Instrument to remove all biofilm and stains. After 1-month recall, excellent healing in the upper and lower incisors.

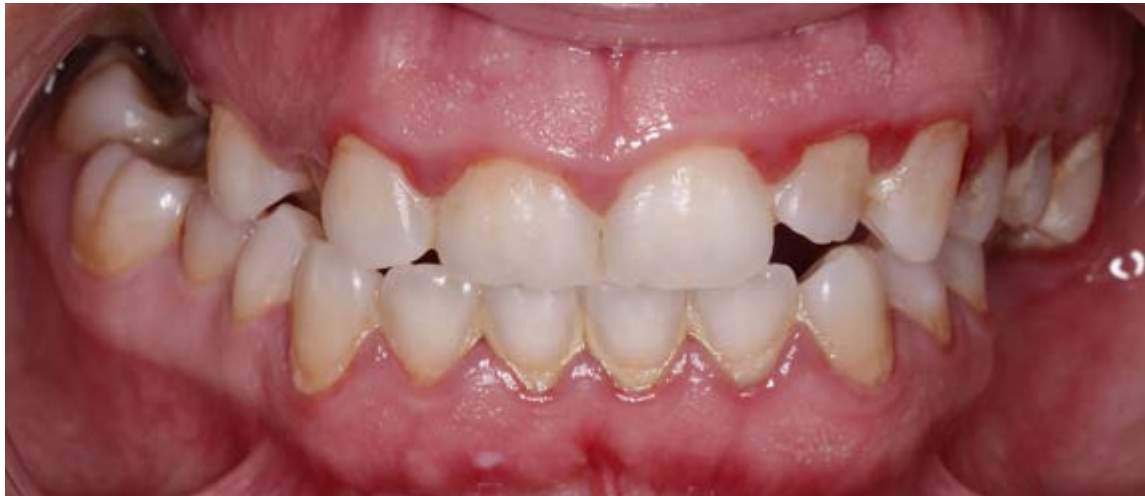PATIENT FEEDBACK

**“THIS IS THE DENTAL CLEANING THAT HAS BOTHERED ME THE LEAST,
I AM DELIGHTED!”**

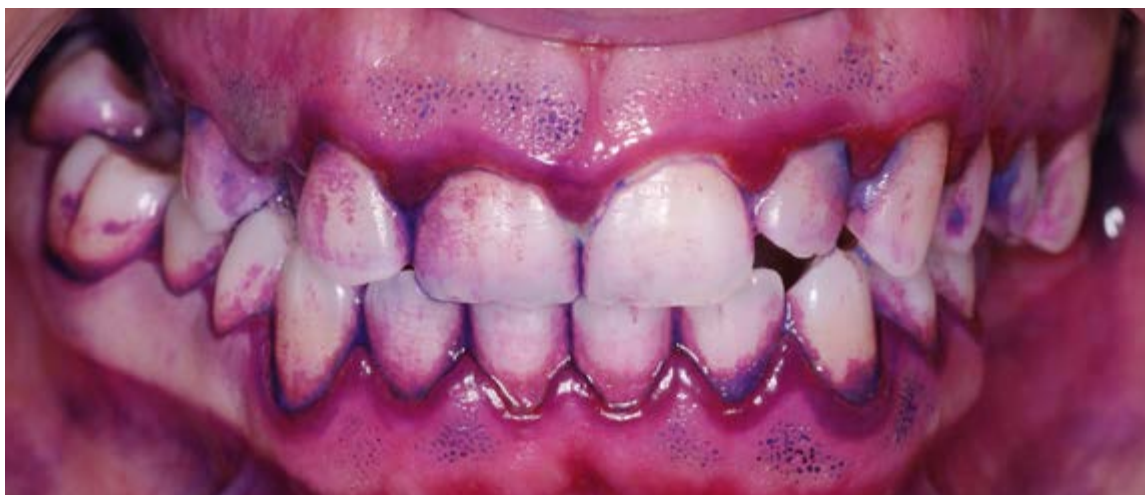PATIENT MOTIVATION



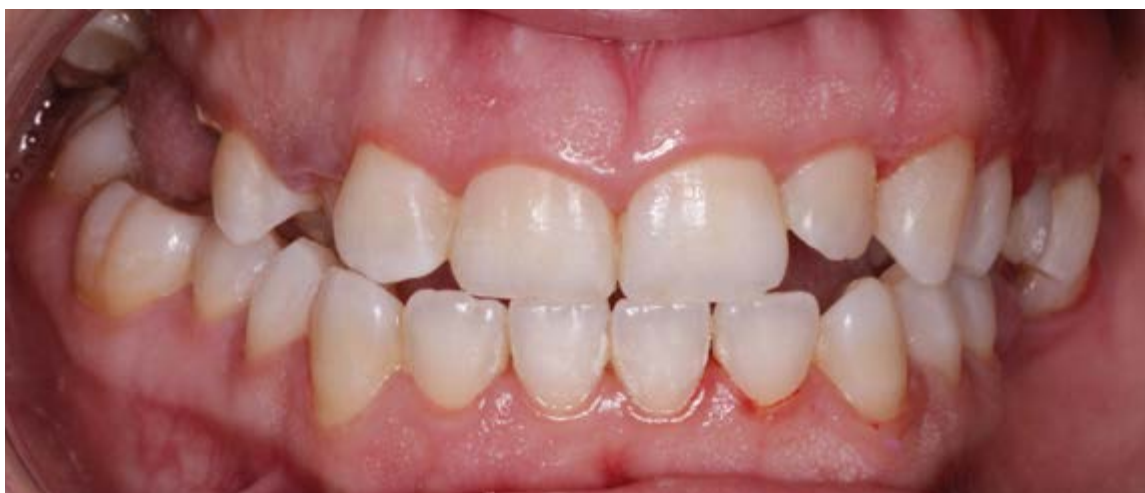BEFORE GBT



AFTER DISCLOSING



AFTER GBT



MAINTENANCE - RECALL

CASE 57



CLINICIAN

Sarah Heuving
Dental hygienist
Germany

PATIENT INFORMATION

- ▶ Age 42, male.

BACKGROUND INFORMATION

- ▶ Periodontal treatment in 2021 under antibiotics. Recall at intervals of 12 weeks. Currently smokes 15 cigarettes a day, works out.

CLINICAL FINDINGS

- ▶ Probing depths generally at 4-5mm, BOP +, visible plaque in the cervical area, tartar and extrinsic discoloration from smoking.

TREATMENT

- ▶ Renewed detailed oral hygiene instruction with emphasis on the use of the appropriate interdental brush. Educational discussion about the negative effects of smoking on periodontal and holistic health. Professional teeth cleaning according to the GBT® concept. Application of the AIRFLOW® MAX with AIRFLOW® PLUS Powder. Periodontal pockets treated with PERIOFLOW®. Tartar removal with PIEZON® PS and PI Instrument. Fluoridation and feedback discussion.

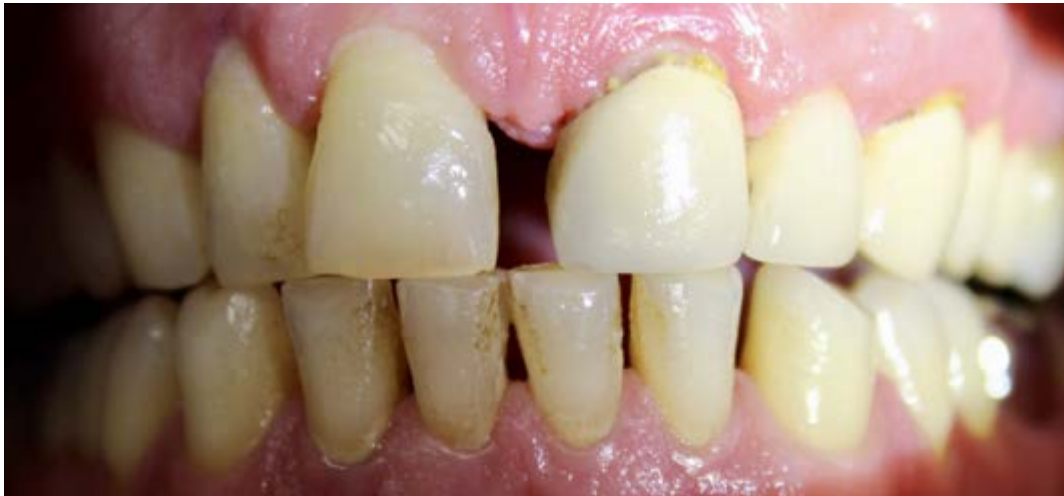PATIENT FEEDBACK

“I TOTALLY ENJOYED GBT AND WILL PLAN MY DATE SOON FOR THE NEXT RECALL. I TAKE RESPONSIBILITY FOR ORAL HYGIENE AND MY OVERALL HEALTH.”

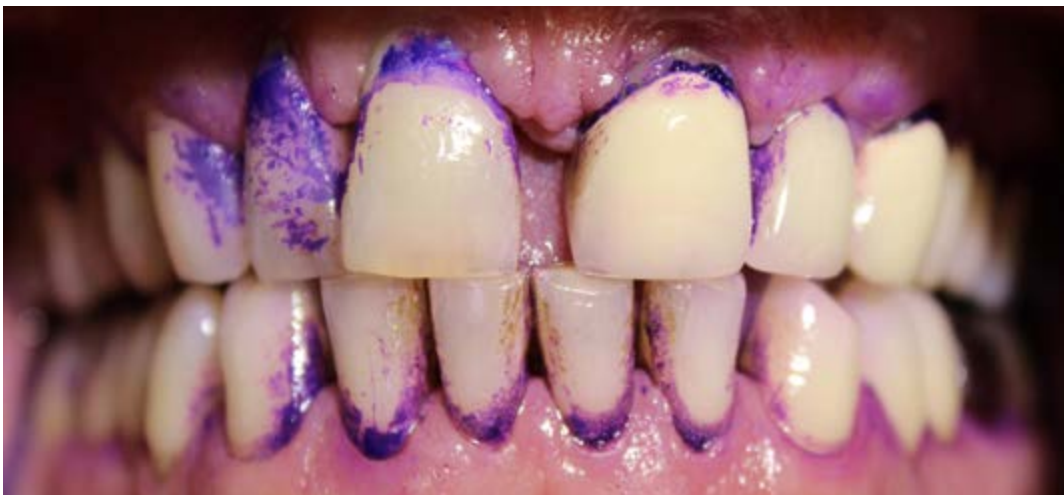PATIENT MOTIVATION



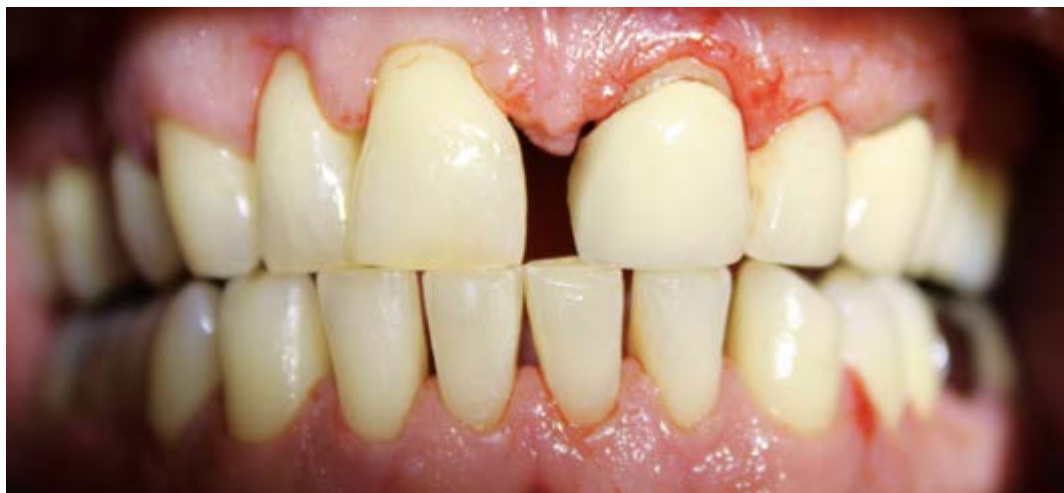BEFORE GBT



AFTER DISCLOSING



AFTER GBT



MAINTENANCE - RECALL

CASE 58



CLINICIAN

Simone Schwenke
Dental hygienist
Germany

PATIENT INFORMATION

- ▶ Age 48, female.

BACKGROUND INFORMATION

- ▶ Nothing relevant. The patient comes for a regular recall every 6 months. Her oral hygiene is good. She uses a Philips Sonicare and dental floss. No relevant habits.

CLINICAL FINDINGS

- ▶ Probing readings 1-3mm. No bleeding on probing. Recessions of 1-3mm by “scrubbing” with the manual toothbrush in the past. No calculus.

TREATMENT

- ▶ Removal of existing biofilm with the AIRFLOW® MAX handpiece and AIRFLOW® PLUS Powder.

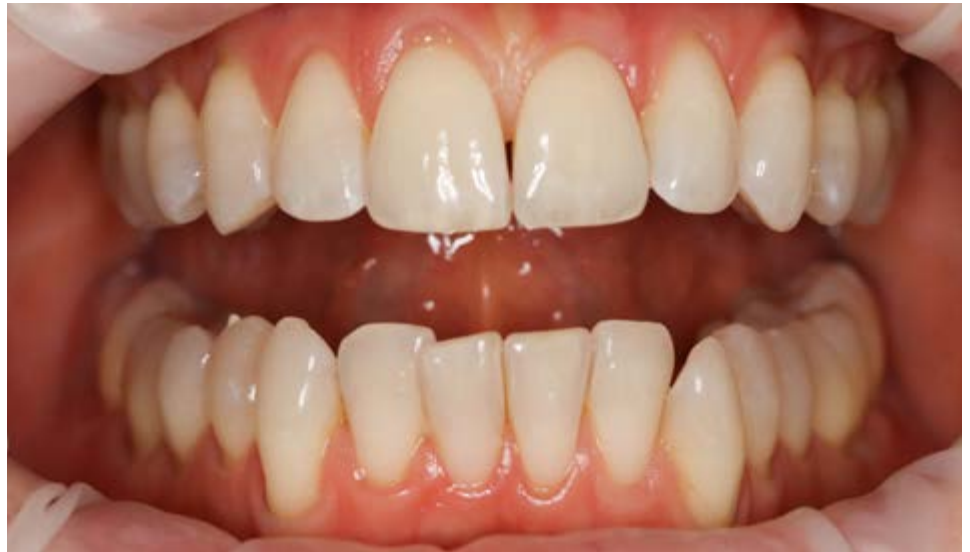PATIENT FEEDBACK

“I LOVE THAT FRESH, CLEAN AND SMOOTH FEELING.”

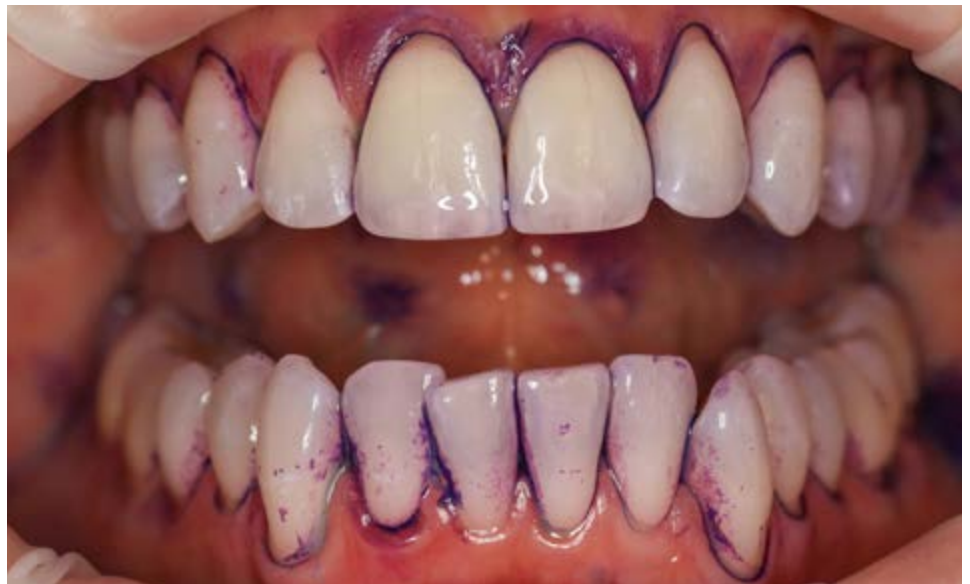PATIENT MOTIVATION



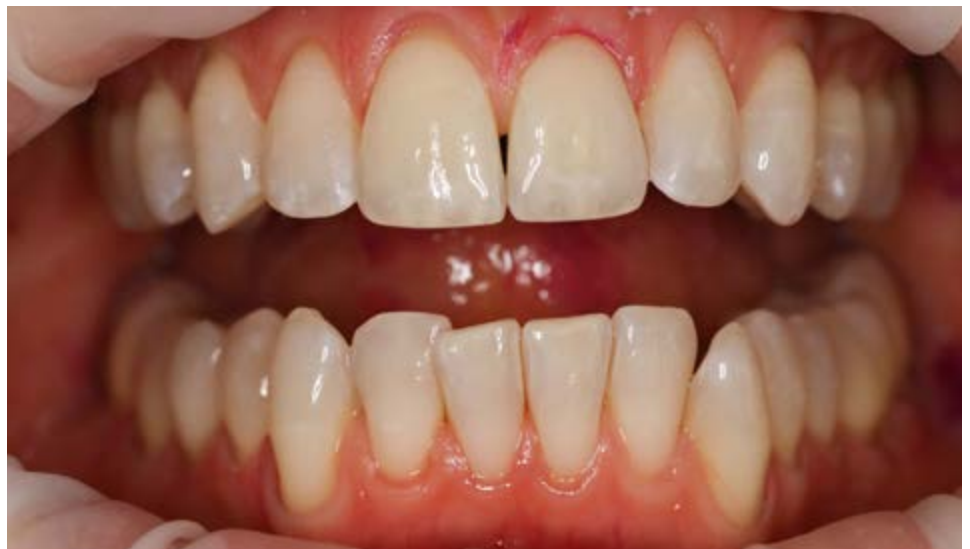BEFORE GBT



AFTER DISCLOSING



AFTER GBT



MAINTENANCE - RECALL

CASE 59



CLINICIAN

Stephanie Günther
Dental hygienist
South Africa

PATIENT INFORMATION

- ▶ Age 48, female.

BACKGROUND INFORMATION

- ▶ The patient has been seeing me every 6 months since 2012 (10 years) for prophylaxis. Her main concern is generalised gingival recession and sensitivity (especially during hygiene visits) at the exposed tooth necks. This patient remembers the days of the “old fashioned, scale and polish” treatment and, though dedicated to her 6 monthly visits, always came with a sense of dread in her heart due to the unpleasant scaling sessions. I made the switch to GBT in 2017 and we have never looked back. Non-smoker, nothing exceptional in the medical history, patient appears in good health.

CLINICAL FINDINGS

- ▶ Generalised, yet stable, gingival recession with moderate plaque (the interdental areas being the patient’s weak spot) and calculus build-up mainly around the lower anteriors.

TREATMENT

- ▶ After disclosing, the AIRFLOW® MAX handpiece was used with AIRFLOW® PLUS Powder for supra- and subgingival biofilm removal. Calculus was removed with the PIEZON® PS Instrument. All tooth necks treated with Cervitec F varnish.

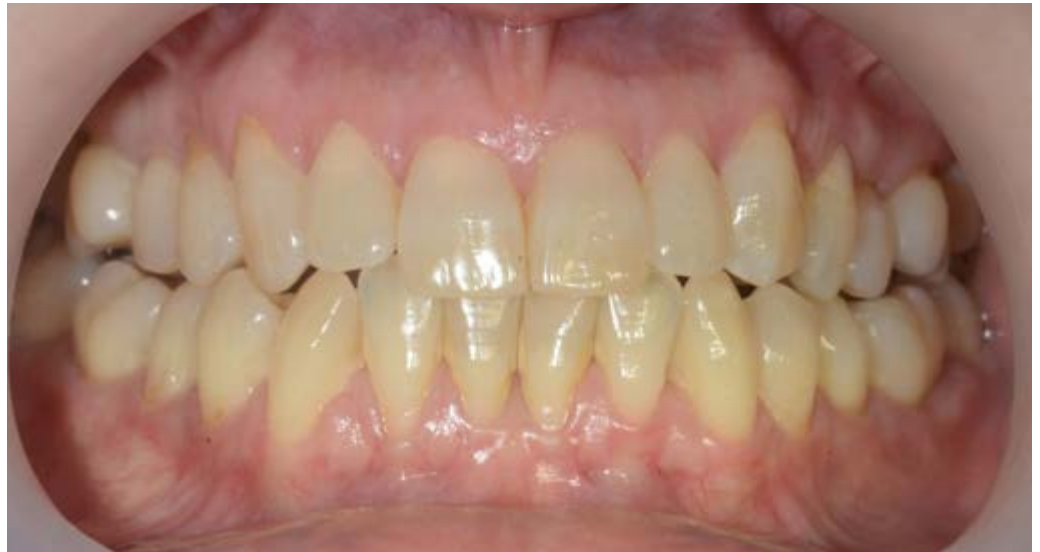PATIENT FEEDBACK

“HAVING MY TEETH CLEANED IS NOW AS EASY AS GOING TO THE
HAIRDRESSER... ALMOST!”

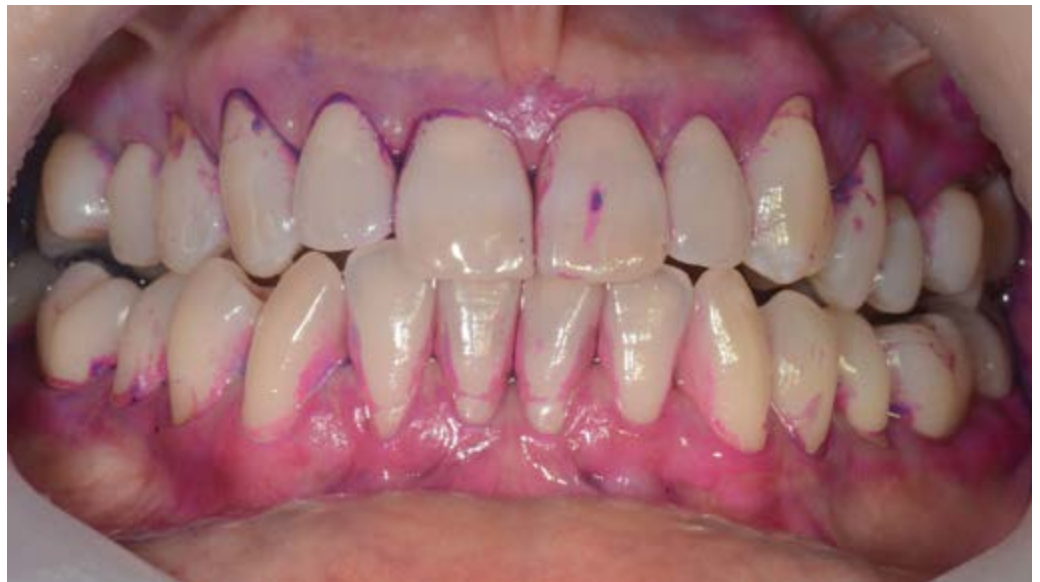PATIENT MOTIVATION



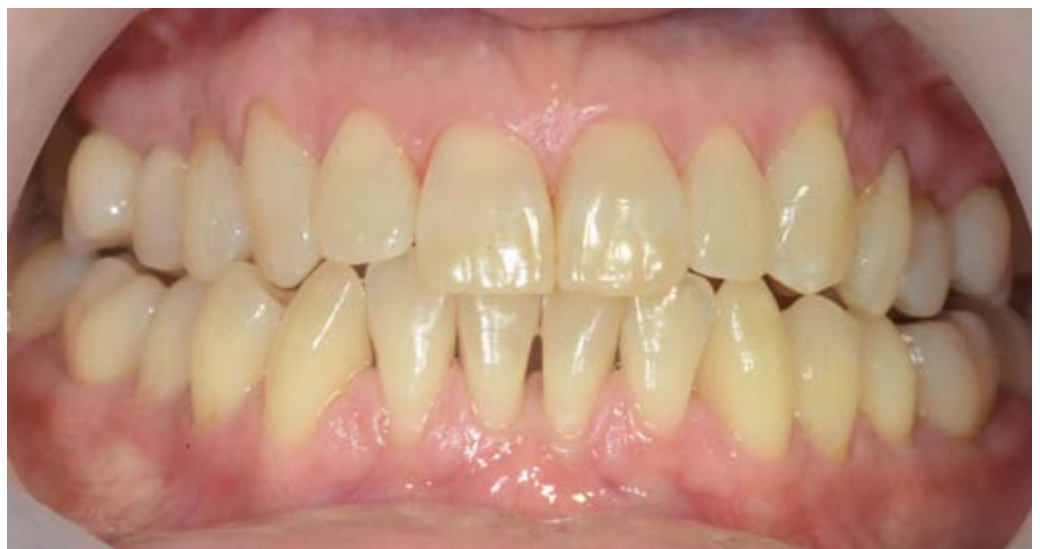BEFORE GBT



**AFTER
DISCLOSING**



AFTER GBT



MAINTENANCE - RECALL

CASE 60



CLINICIAN

Vanessa Borken
Dental hygienist
Germany

PATIENT INFORMATION

- ▶ Age 27, female.

BACKGROUND INFORMATION

- ▶ Bad experience in other dental office. Two weeks unpleasantness afterwards. Overall good oral hygiene. Past of intensive home bleaching with over-the-counter products. Since then, sensitivity problems. Bleaching toothpaste and Sonicare. Her level of motivation is very high. White and good-looking teeth are very important for her.

CLINICAL FINDINGS

- ▶ Generalized sensitivity. First incisors partially transparent. Interdental plaque/mandibular incisors have calculus.

TREATMENT

- ▶ Reeducation about bleaching and handling sensitivity problems. The goal is to get the patient back to a healthy relationship between oral health and having the stress of a perfect look. GBT was done with AIRFLOW® PLUS Powder, minimal PIEZON® NO PAIN, fluoride application.

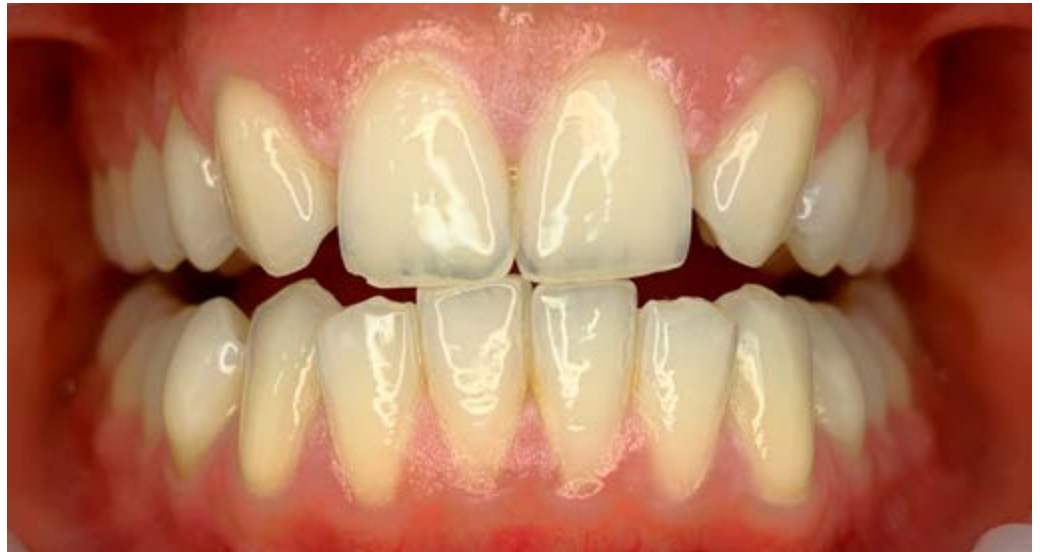PATIENT FEEDBACK

“I NEVER EXPERIENCED A TEETH CLEANING AS COMFORTABLE AND PLEASANT. BUT WITH GBT I HAD NO INCONVENIENCE. FOR THE FIRST TIME, IT FELT LIKE I DID SOMETHING GOOD FOR MY TEETH.”

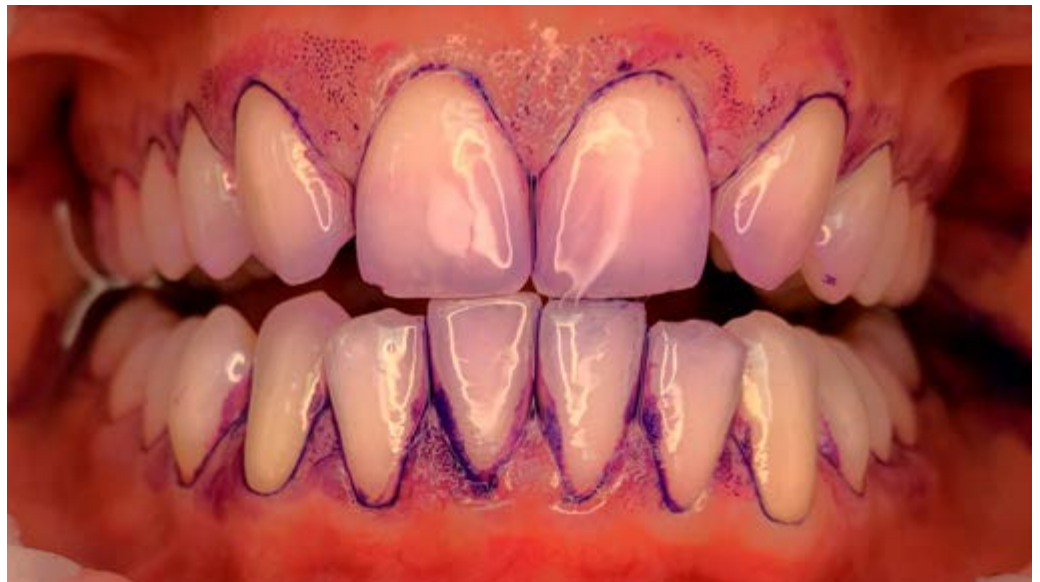PATIENT MOTIVATION



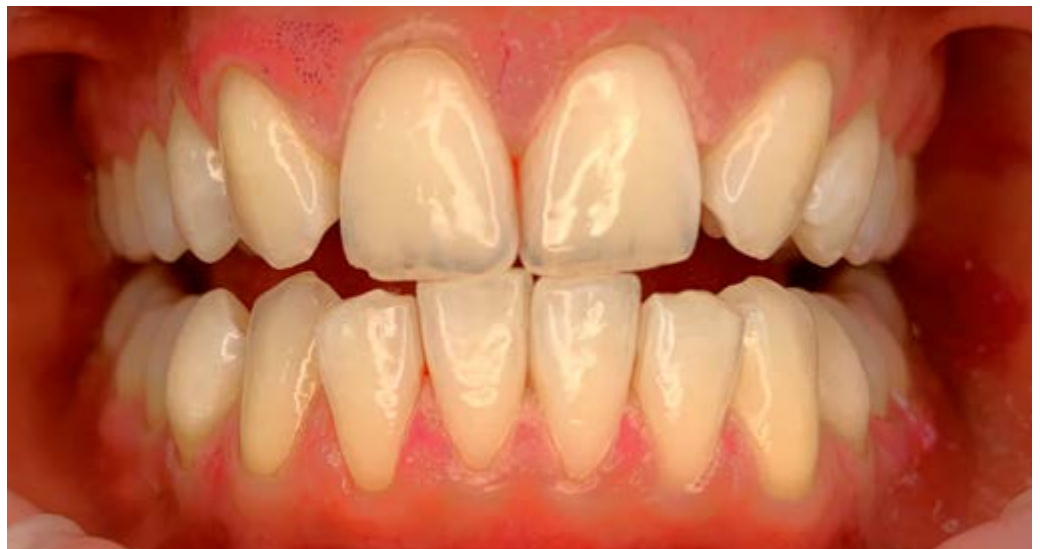BEFORE GBT



AFTER DISCLOSING



AFTER GBT



MAINTENANCE - RECALL

CASE 61



CLINICIAN

Zeng Cuiying
Periodontist
China

PATIENT INFORMATION

- ▶ Age 42, female.

BACKGROUND INFORMATION

- ▶ Brushes teeth twice a day, 2min/ time, uses dental floss daily. Bleeding when brushing, loose teeth and bad breath for half a year. No smoking.

CLINICAL FINDINGS

- ▶ Oral hygiene is ok. Soft deposit index: 2, dental calculus index: 2. Bleeding on probing, bleeding index: 4. Gingival recession was moderate and severe, 17, 16, 46, 47 loss of attachment, PD 6-8mm in individual sites.

TREATMENT

- ▶ GBT combined with local medication. Focus on OHI.

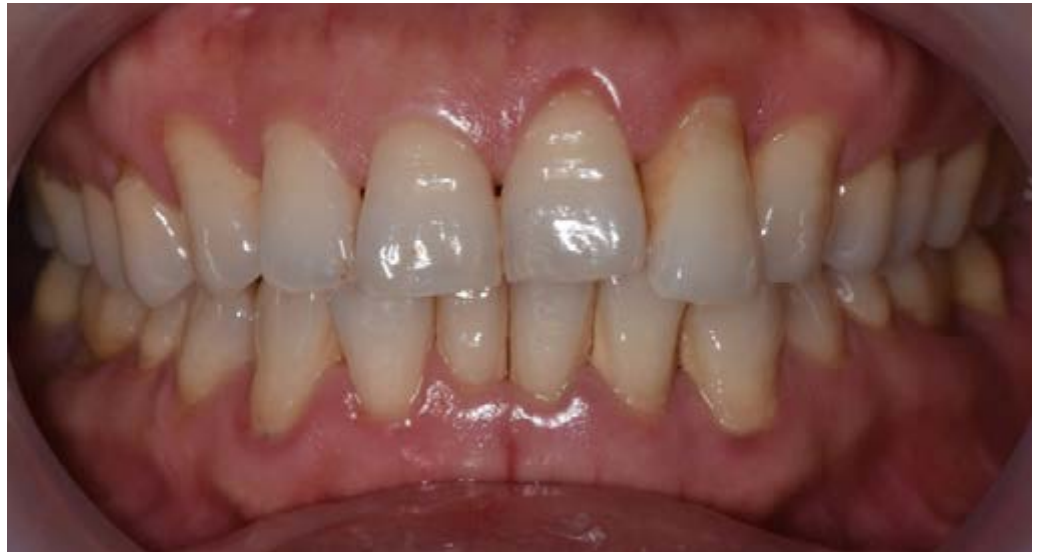PATIENT FEEDBACK

“GBT IS AMAZING ! I THINK I NEED TO ASK ALL MY FAMILY MEMBERS TO DO GBT AT LEAST ONCE A YEAR !”

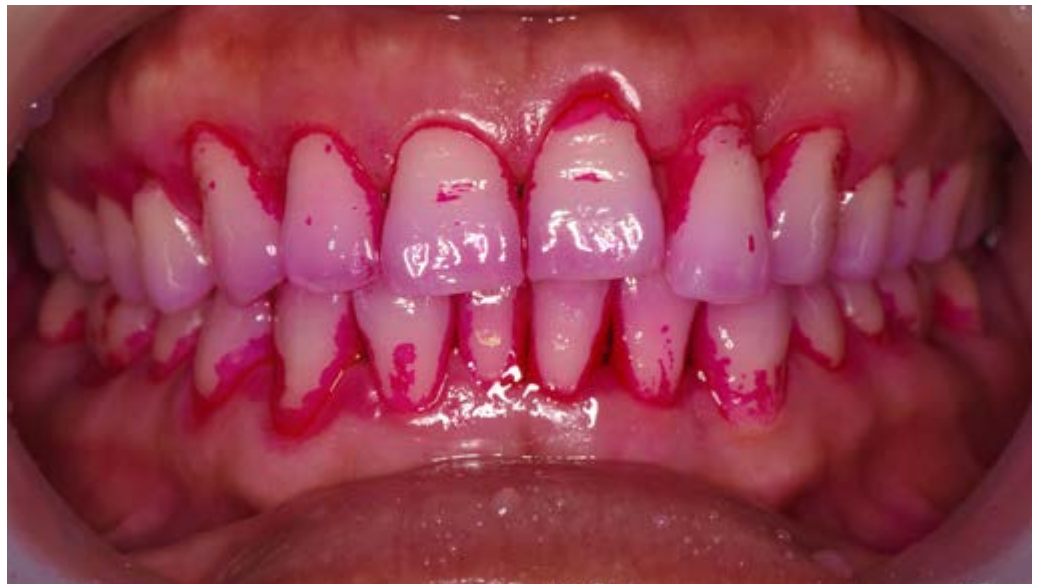PATIENT MOTIVATION



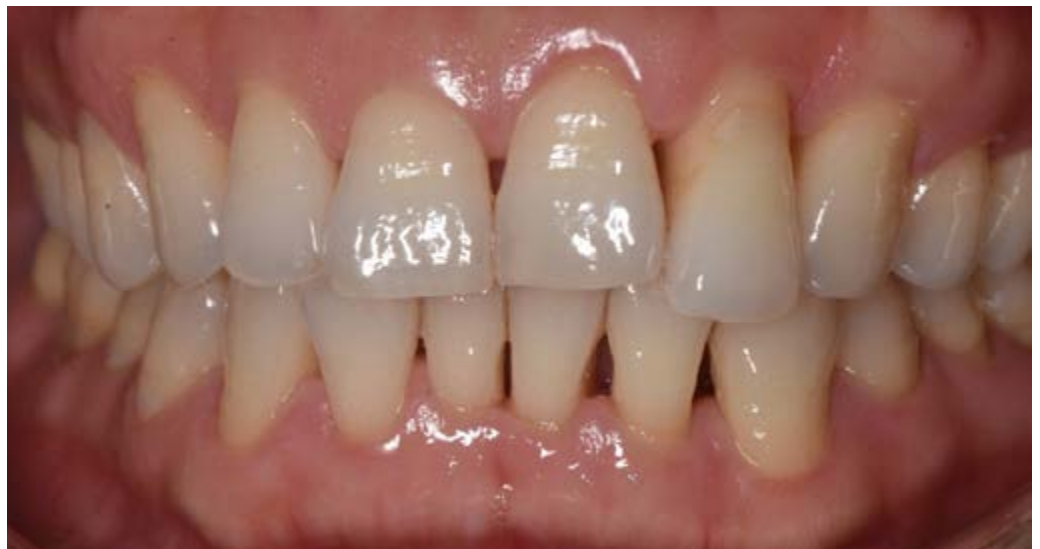BEFORE GBT



**AFTER
DISCLOSING**



AFTER GBT



ORTHODONTICS

CASE 62



CLINICIAN

Adina Mauder
Dental hygienist
Germany

PATIENT INFORMATION

- ▶ Age 37, female.

BACKGROUND INFORMATION

- ▶ Poor oral hygiene. Orthodontic treatment since 1 year. The use of a mouth rinse caused many stains.

CLINICAL FINDINGS

- ▶ No periodontal pockets, BOP -, calculus ++, Difficulty in maintaining oral hygiene, especially interdental care. After 3 months, patient shows good oral hygiene.

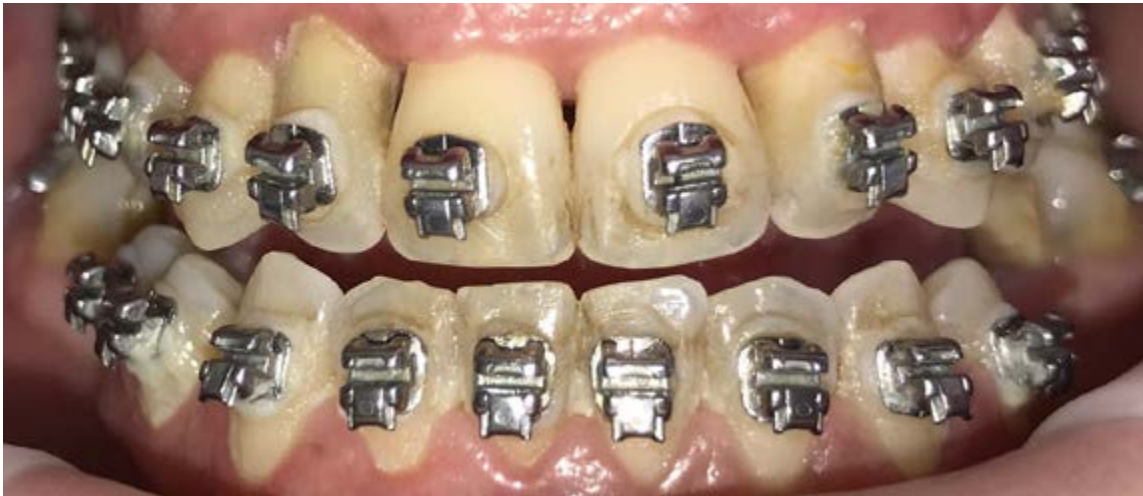TREATMENT

- ▶ GBT performed using AIRFLOW® PLUS Powder. Time spent on patient motivation and cleaning orthodontic brackets together with the patient. Spoke about challenges in keeping the areas clean. Calculus removed with PIEZON® PS Instrument without touching the brackets.

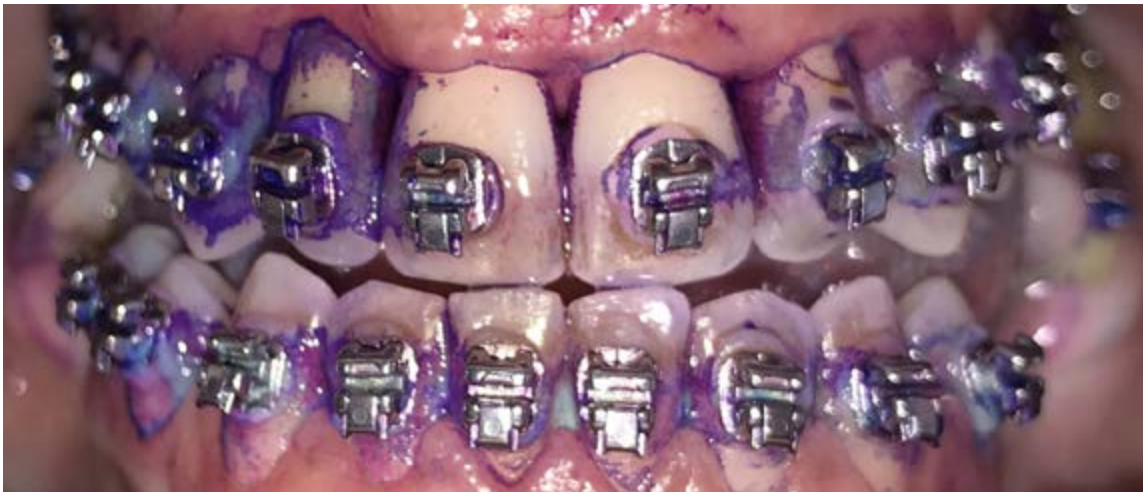PATIENT FEEDBACK

“NEVER HAVE I EXPERIENCED PROPHYLAXIS TO BE SO THOROUGH, GENTLE AND WITH SUCH GOOD RESULTS. THANK YOU GBT!”

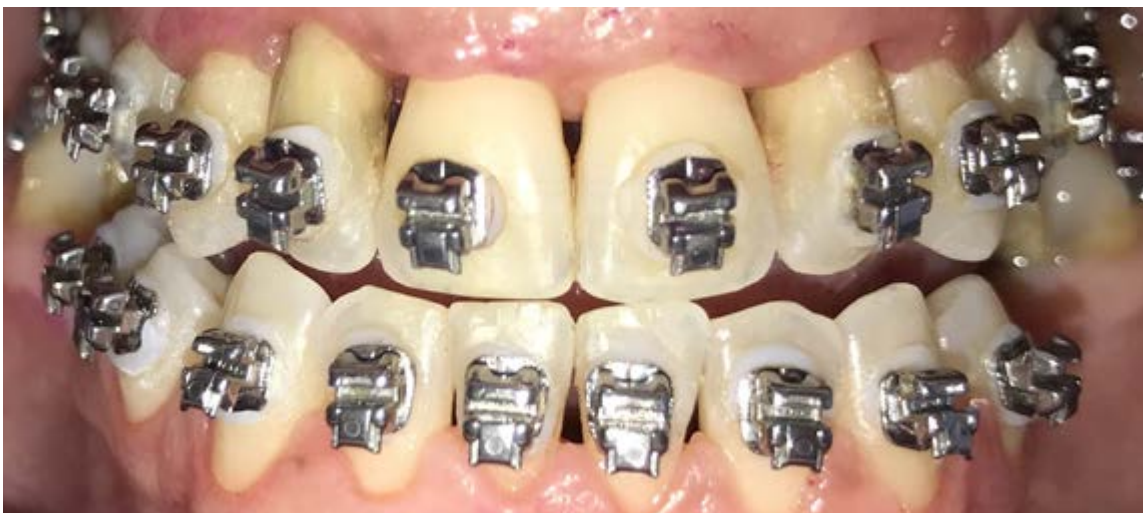BEFORE GBT



AFTER DISCLOSING



AFTER GBT



ORTHODONTICS

CASE 63



CLINICIAN

Andrii Voroshylov
Dental hygienist
Ukraine

PATIENT INFORMATION

- ▶ Age 13, male.

BACKGROUND INFORMATION

- ▶ The patient believed he was cleaning teeth adequately and could not see any plaque on the teeth. High sugar diet.

CLINICAL FINDINGS

- ▶ Despite previously being provided with oral hygiene advice, plaque control around the orthodontic brackets was not ideal.

TREATMENT

- ▶ Plaque disclosing and evaluation were done using biofilm discloser and the patient was shown images of the teeth and the areas of poor plaque control. Particular emphasis was placed on the presence of the light blue stained plaque indicating the acid-producing plaque which could potentially cause demineralization and white spot lesions on the teeth and thereby compromise the tooth structure and the final aesthetic result. The patient was given additional instructions on the most appropriate techniques for removing the plaque and this was demonstrated in the surgery. The residual plaque was then removed with AIRFLOW® Prophylaxis Master (AFPM) using AIRFLOW® PLUS Powder. The patient was advised to continue using a toothpaste twice a day and apply a remineralizing agent GC Tooth Mousse Plus after brushing.

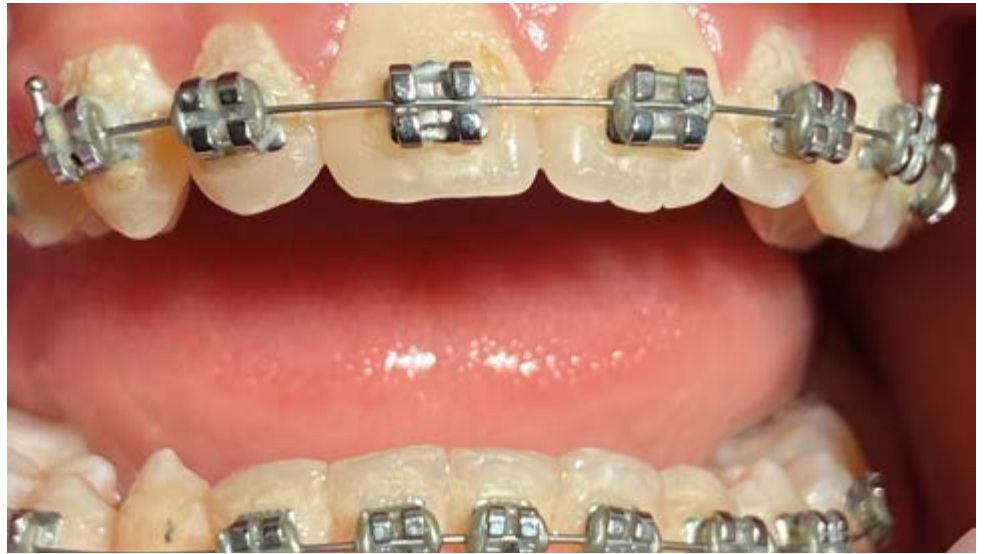PATIENT FEEDBACK

**“THANK YOU FOR SHOWING ME MY BIOFILM.
IT WAS NOT SCARY AND DID NOT CAUSE ANY PAIN.”**

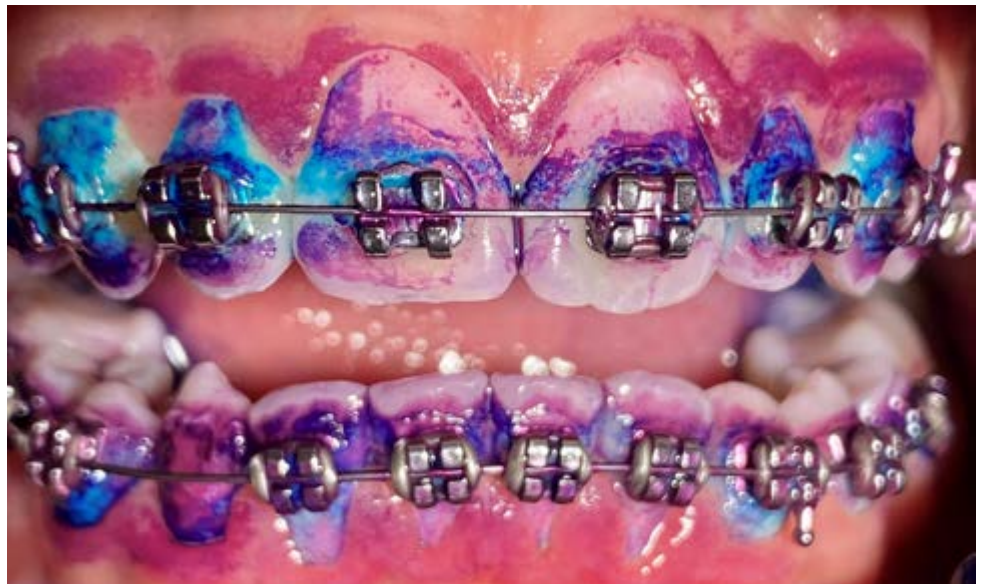& GBT



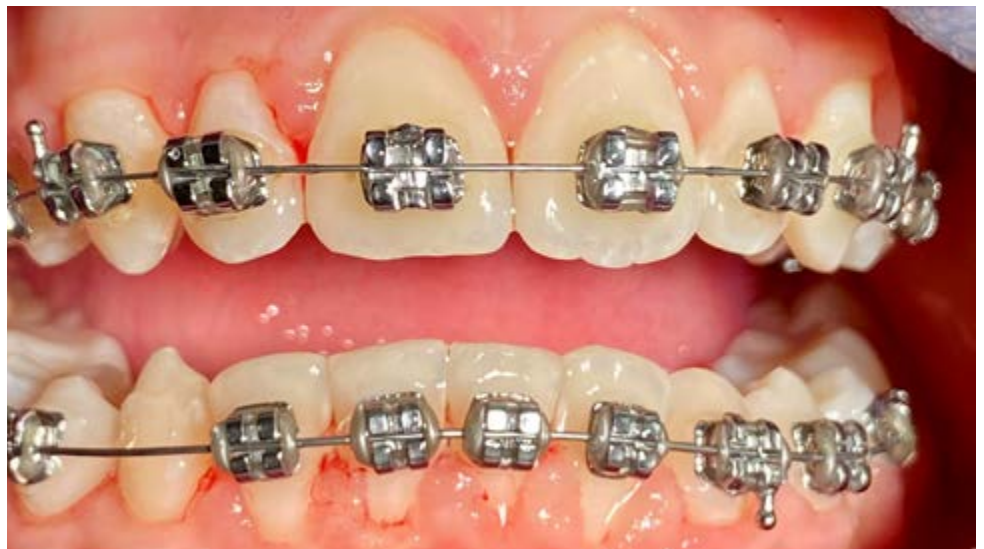BEFORE GBT



AFTER DISCLOSING



AFTER GBT



ORTHODONTICS

CASE 64



CLINICIAN

Beatrice Zvalčáková
Dental hygienist
Czech Republic

PATIENT INFORMATION

- ▶ Age 13, male.

BACKGROUND INFORMATION

- ▶ First visit to a dental hygienist, cleans only with toothbrush. Presence of orthodontic brackets 2 years, consumes a lot of sweet food.

CLINICAL FINDINGS

- ▶ Very poor oral hygiene, presence of a large amount of acidic dental plaque with the risk of demineralization, dental calculus around the orthodontic brackets in frontal part in lower jaw, bleeding on probing (BOP).

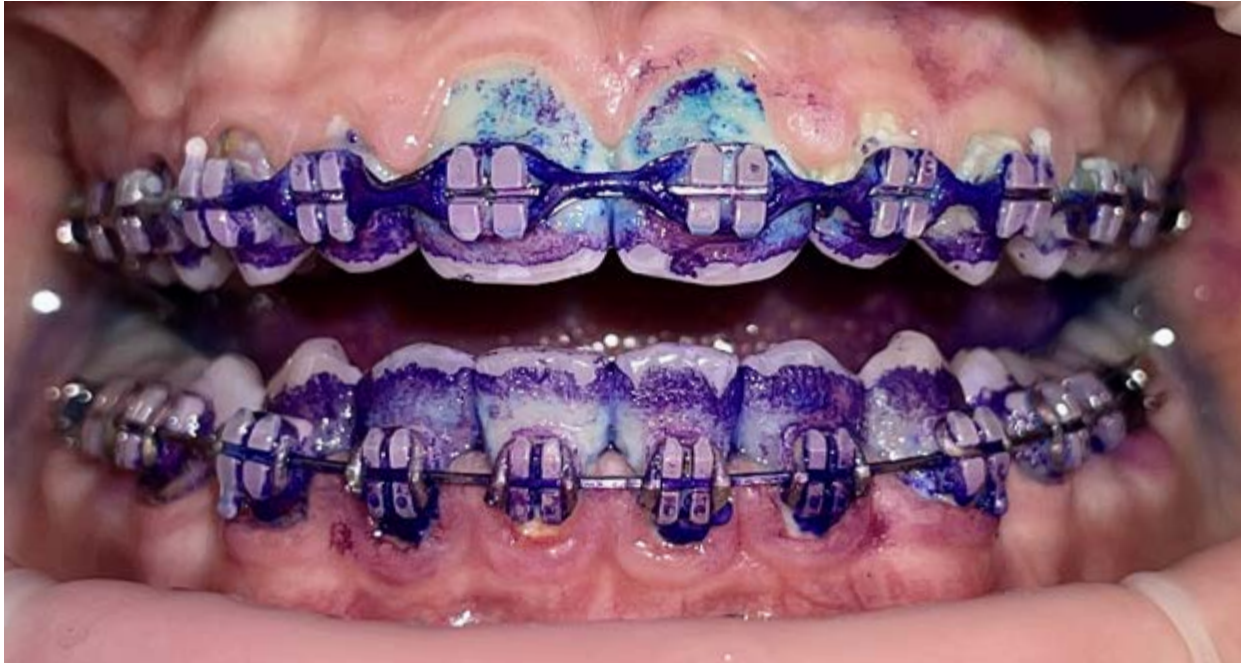TREATMENT

- ▶ GBT done with AIRFLOW® PLUS Powder, PIEZON® PS Instrument. Thorough motivation and practice of cleaning orthodontic brackets using toothbrush, interdental brushes and tufted toothbrush. Regular recall every 3 months.

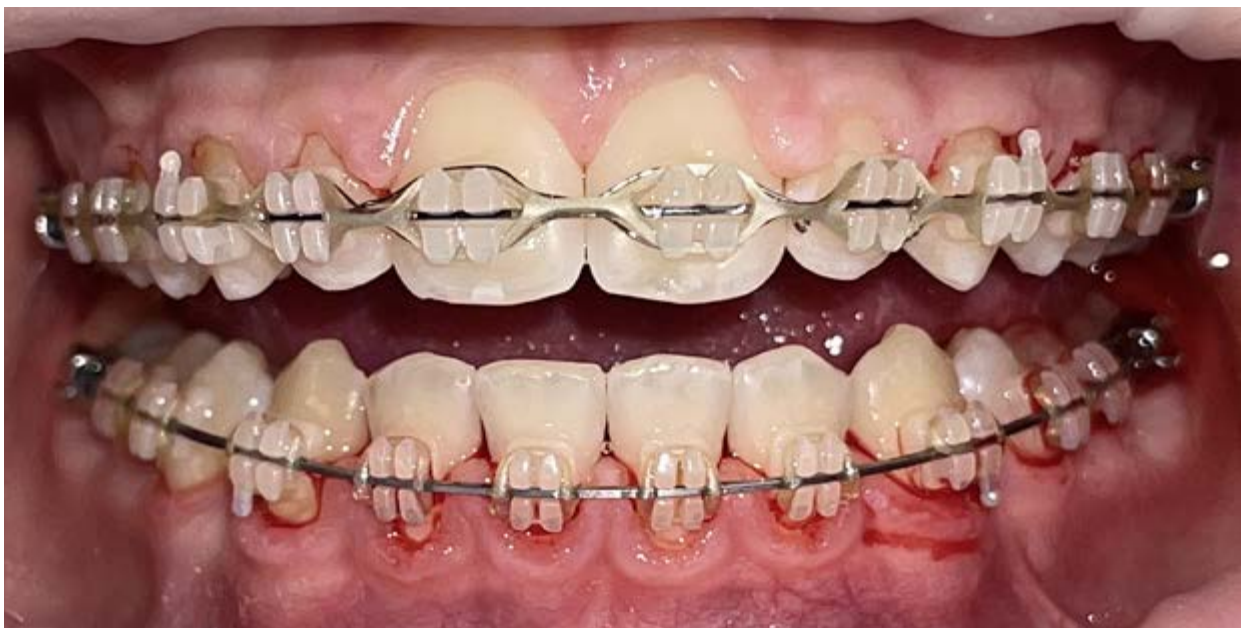PATIENT FEEDBACK

“I CANNOT BELIEVE THAT MY TEETH WERE THIS DIRTY. THE COLOR REALLY MADE ME REALIZE THAT I HAVE TO BRUSH BETTER.”

BEFORE GBT



AFTER GBT



ORTHODONTICS

CASE 65



CLINICIAN

Bianca Maria Messina
Dental hygienist
Italy

PATIENT INFORMATION

- ▶ Age 22, female.

BACKGROUND INFORMATION

- ▶ Invisible orthodontics, on 21 of 25 aligners. No relevant habits.

CLINICAL FINDINGS

- ▶ The patient presents no bleeding on probing and no supragingival calculus. Brushes her teeth three times a day (after every meal) with a manual toothbrush before putting on the aligners. Uses floss every day.

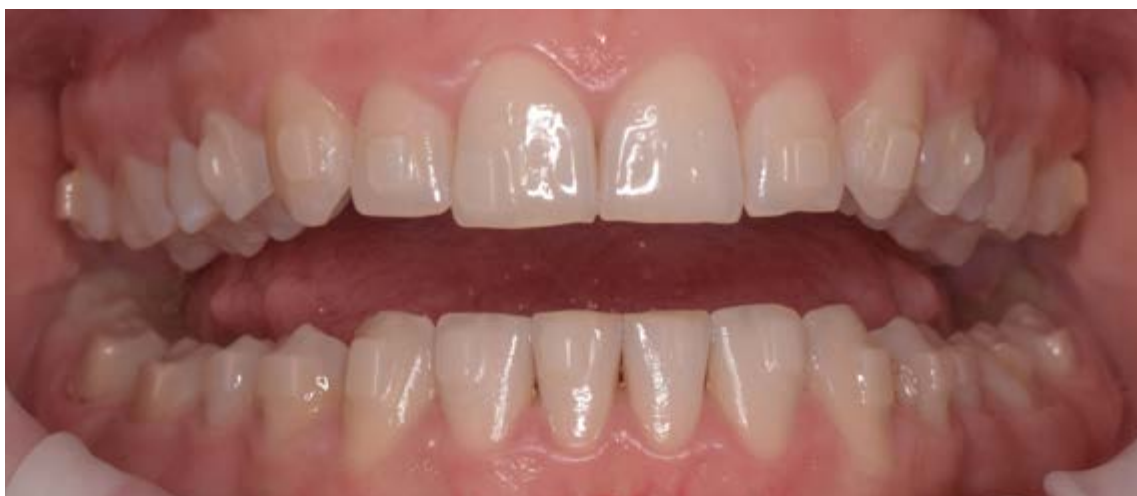TREATMENT

- ▶ Guided Biofilm Therapy (GBT) given to the patient using only AIRFLOW® PLUS Powder to remove biofilm.

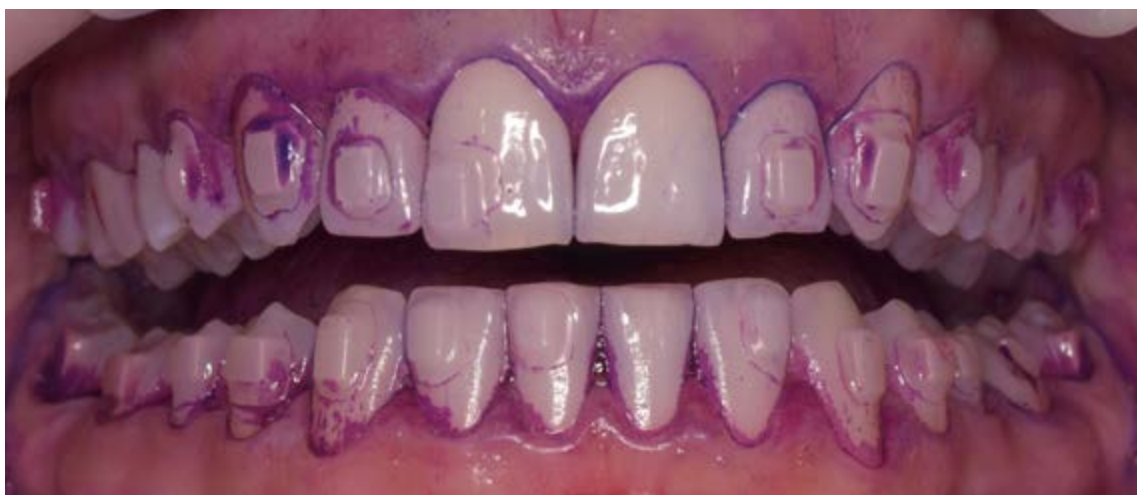PATIENT FEEDBACK

“I AM VERY HAPPY. IT WAS A GREAT EXPERIENCE.”

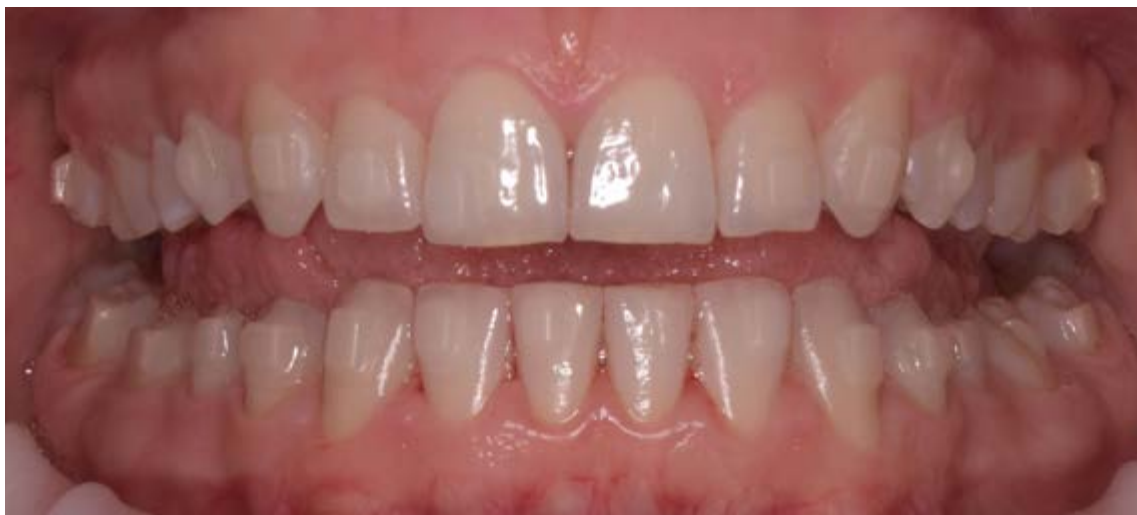BEFORE GBT



AFTER DISCLOSING



AFTER GBT



ORTHODONTICS

CASE 66



CLINICIAN

Wu Yuping
Dentist
China

PATIENT INFORMATION

- ▶ Age 17, female.

BACKGROUND INFORMATION

- ▶ High school student, no special eating habits. Poor oral hygiene, not very motivated to visit a dental office. High school student, no special eating habits.

CLINICAL FINDINGS

- ▶ With a large amount of soft deposits attached to the labial tooth surface, the edge of the attachment becomes yellow. Food residue accumulates between teeth.

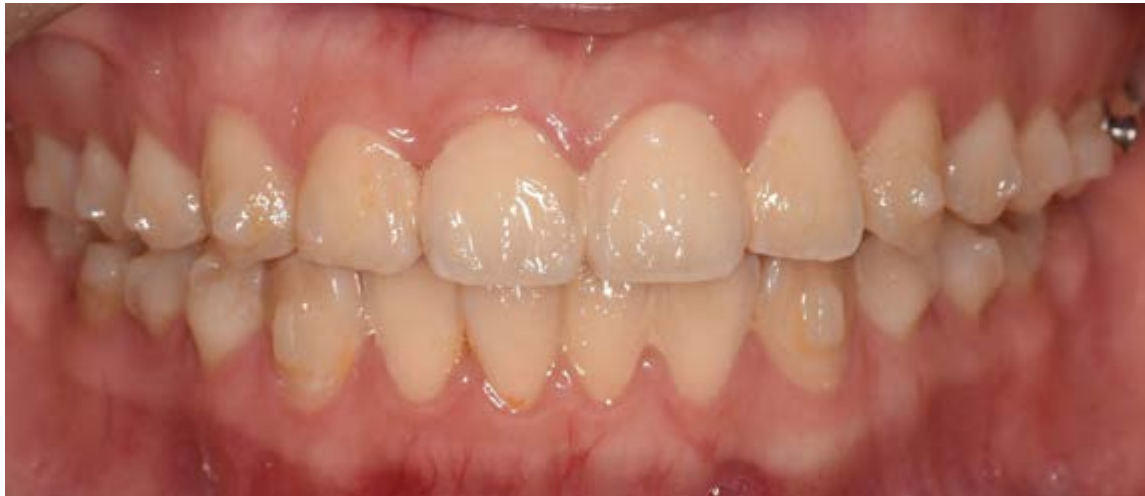TREATMENT

- ▶ Let the patient know the location of mature plaque and newly formed plaque and related reasons in order to strengthen her attention to oral health through GBT treatment.

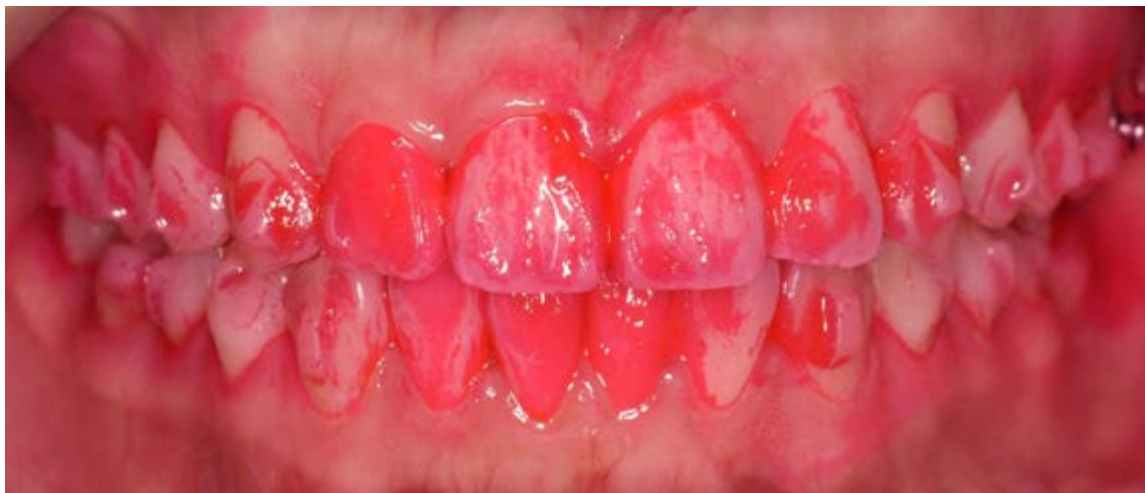PATIENT FEEDBACK

“FEEL VERY GOOD AFTER GBT TREATMENT. AS A SENIOR SCHOOL STUDENT I AM BUSY WITH STUDIES, I ALSO WORRIED ABOUT DENTAL CARIES CAUSED BY INADEQUATE BRUSHING. AFTER TODAY’S TREATMENT, MY UNDERSTANDING OF ORAL HEALTH CARE, ESPECIALLY THE PRECAUTIONS TAKEN TO SEE BIOFILM, WHICH IS INVISIBLE TO THE NAKED EYE, HAVE BEEN ENLIGHTENING.”

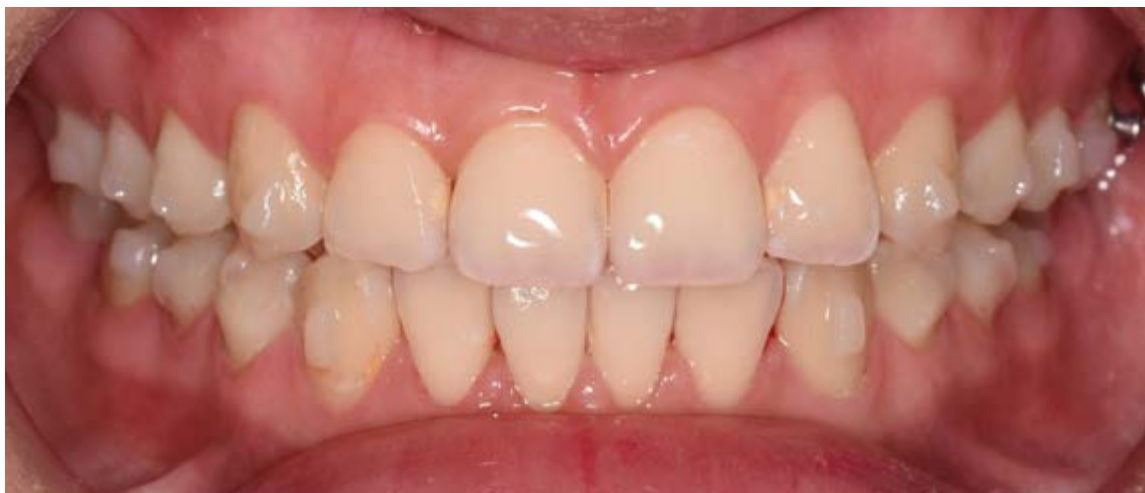BEFORE GBT



AFTER DISCLOSING



AFTER GBT



ORTHODONTICS

CASE 67



CLINICIAN

Chiara Deitos
Dental hygienist
Italy

PATIENT INFORMATION

- ▶ Age 16, female.

BACKGROUND INFORMATION

- ▶ The patient is in high school and 5 days a week she has lunch at school and she doesn't brush her teeth when she is at school. She uses manual toothbrush with soft bristles, she doesn't use interdental brushes and doesn't floss regularly. The patient has a regular diet and takes sport supplements. Non-smoker, no drinking habits.

CLINICAL FINDINGS

- ▶ Gingivitis with BOP +. Presence of calculus + in lower anteriors.

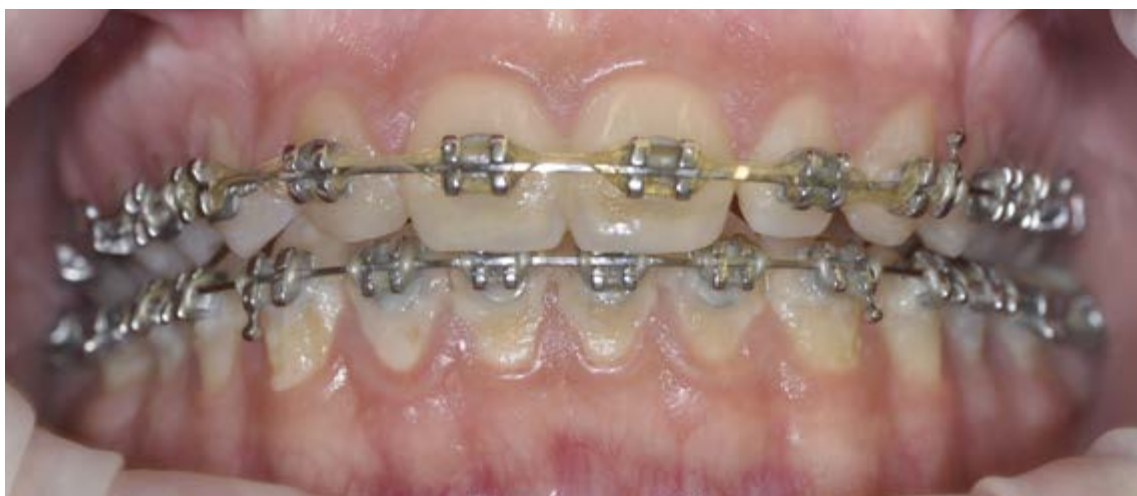TREATMENT

- ▶ The dental biofilm was exposed and the patient motivated. Then biofilm, stains and young calculus were removed with AIRFLOW® MAX and PLUS Powder. By using PIEZON® with PS Instrument the remaining calculus was removed. After a final check, a 3-month recall was scheduled.

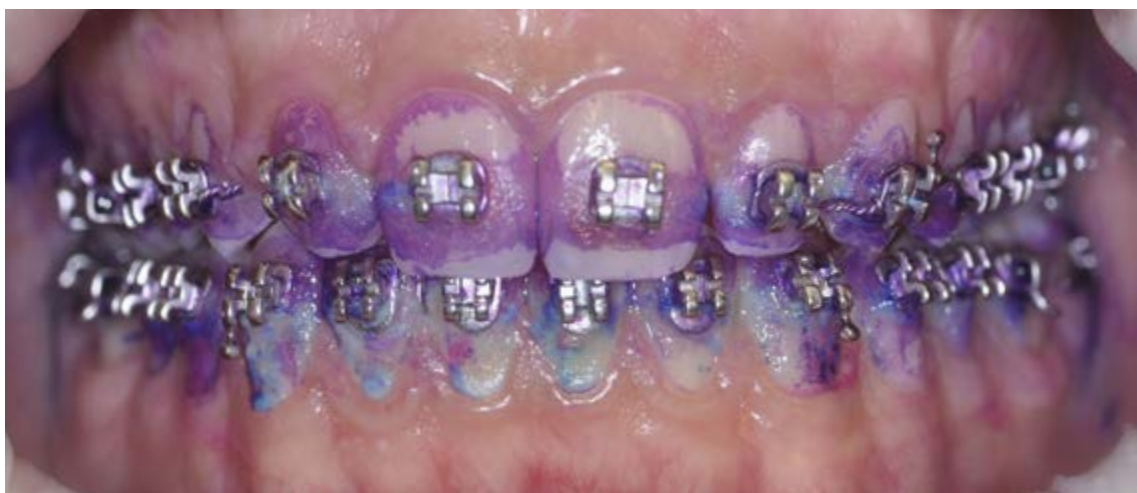PATIENT FEEDBACK

“THE TREATMENT WAS MORE DELICATE THAN LAST TIME AND BY SEEING THE COLORED AREAS I REALIZED THAT I NEED TO PAY MORE ATTENTION TO ORAL HYGIENE.”

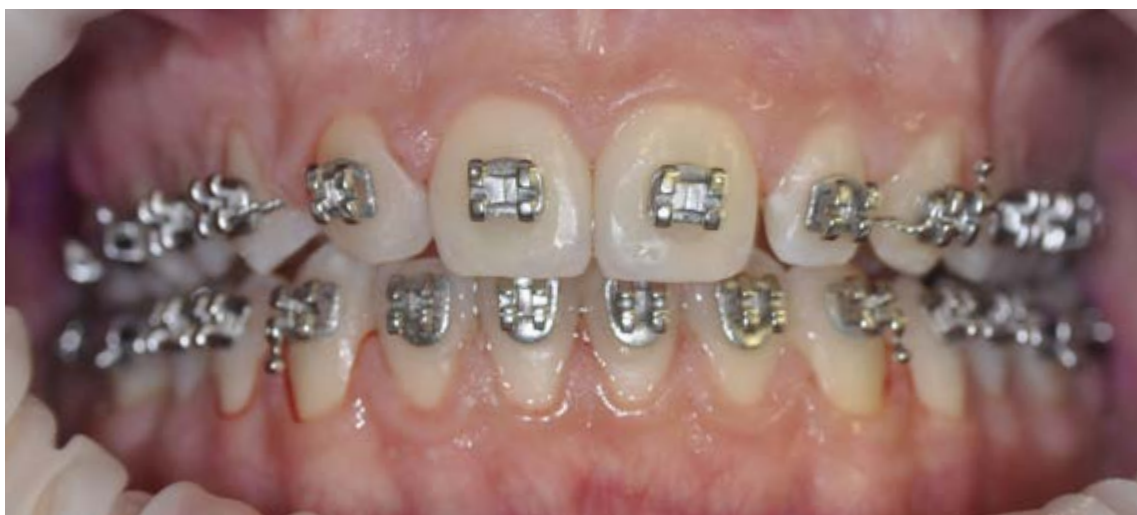BEFORE GBT



AFTER DISCLOSING



AFTER GBT



ORTHODONTICS

CASE 68



CLINICIAN

Cristina Pavan
Dental hygienist
Italy

PATIENT INFORMATION

- ▶ Age 31, male.

BACKGROUND INFORMATION

- ▶ Balanced diet, generally good oral hygiene. The patient is very motivated because, after 5 years of doubts and rethinking, has decided to follow the orthodontic way. First he put on MSE (Maxillary Skeletal Expander) and then underwent maxillofacial surgery to improve the palatine bone's fracture. Now he is in the expansion phase and is finishing root canal treatment in the tooth number 11. No relevant habits.

CLINICAL FINDINGS

- ▶ Presence of gingival inflammation, mild plaque deposits around the orthodontic bands and lower incisors. Presence also of many chlorhexidine stains. BOP -.

TREATMENT

- ▶ GBT done with exclusively AIRFLOW® PLUS Powder, all the chlorhexidine stains easily vanished. Perioflow was used around the MSE for the removal of non-visible biofilm. PIEZON® PS Instrument then was used to remove hard calculus. Now the patient will follow a limited recall every month.

PATIENT FEEDBACK

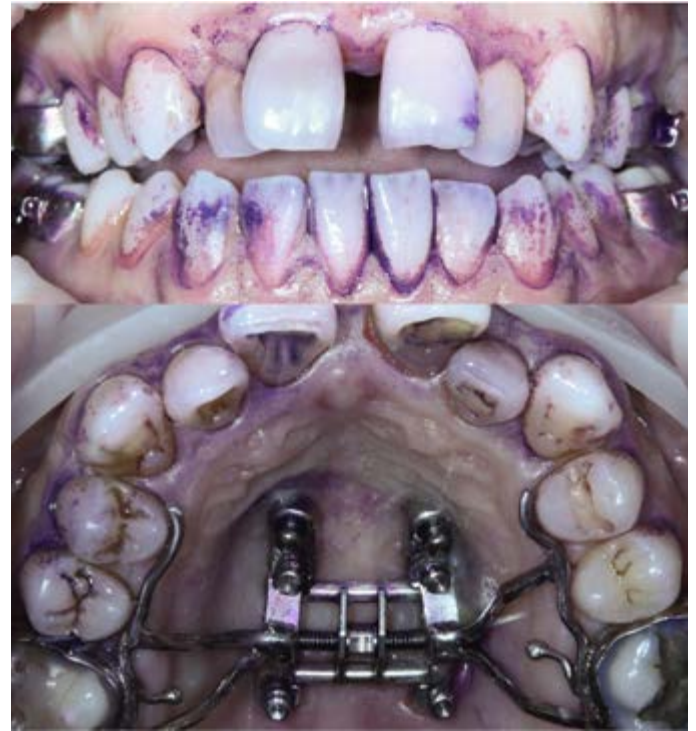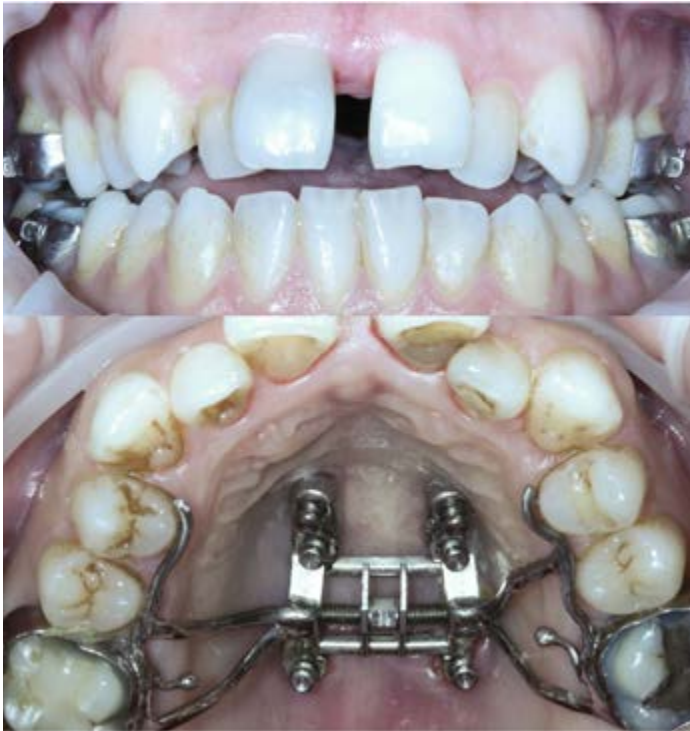“TOP TREATMENT! FINALLY I DON'T FEEL ANYMORE PAIN!”

& GBT

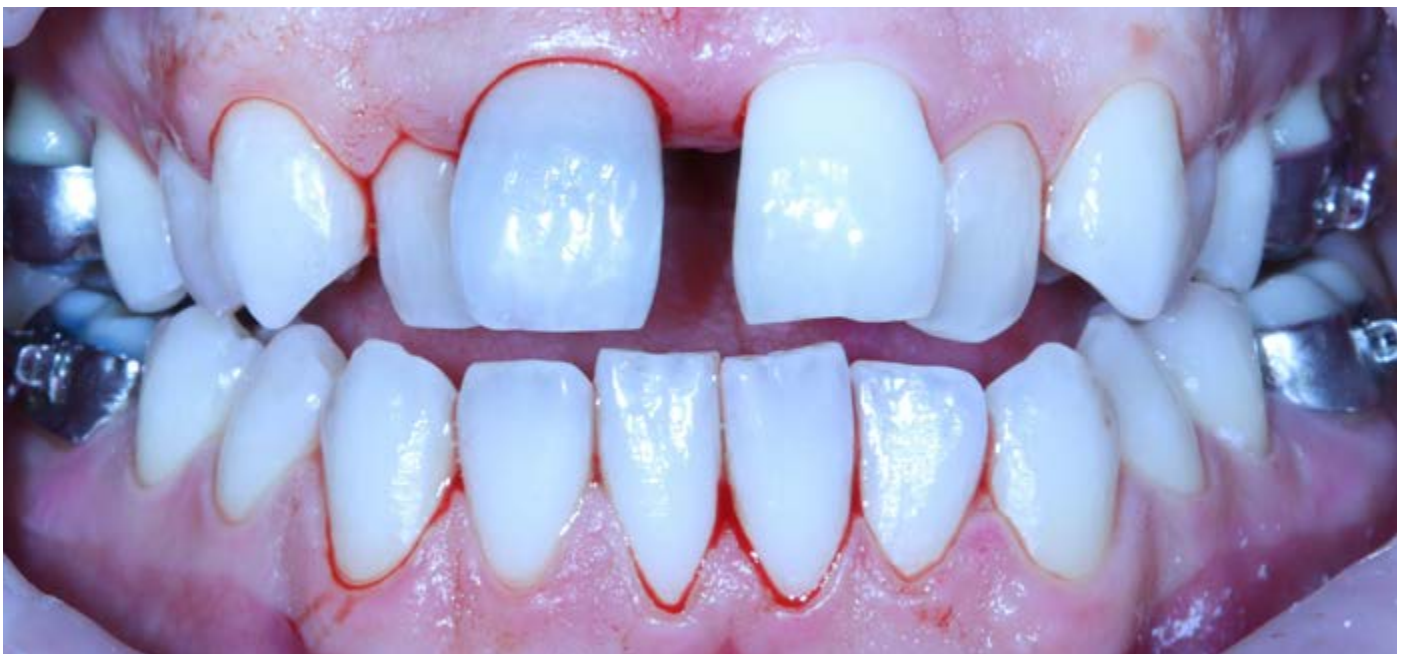

BEFORE GBT

AFTER DISCLOSING



AFTER GBT



ORTHODONTICS

CASE 69



CLINICIAN

Esther Rovira
Dental hygienist
Spain

PATIENT INFORMATION

- ▶ Age 22, female,

BACKGROUND INFORMATION

- ▶ The patient follows a Mediterranean diet, she shows motivation to improve her oral health. She has been in orthodontic treatment for two years. In this case the GBT treatment is the preparation for surgery. She is currently waiting to undergo bimaxillary orthognatic surgery. Uses manual brush twice a day. Does not use floss or dental sticks for interdental cleaning. Non-smoker; improper and incomplete oral hygiene.

CLINICAL FINDINGS

- ▶ No pockets present, BOP + particularly in the interdental anterior region. Supra- and subgingival calculus ++ in the lower mandibular posterior areas.

TREATMENT

- ▶ In step one, I administered BacterX PRO mouth rinse to reduce the viral and bacterial load of the patient's oral cavity. GBT protocol completed with emphasis on disclosing agent and oral hygiene instructions.

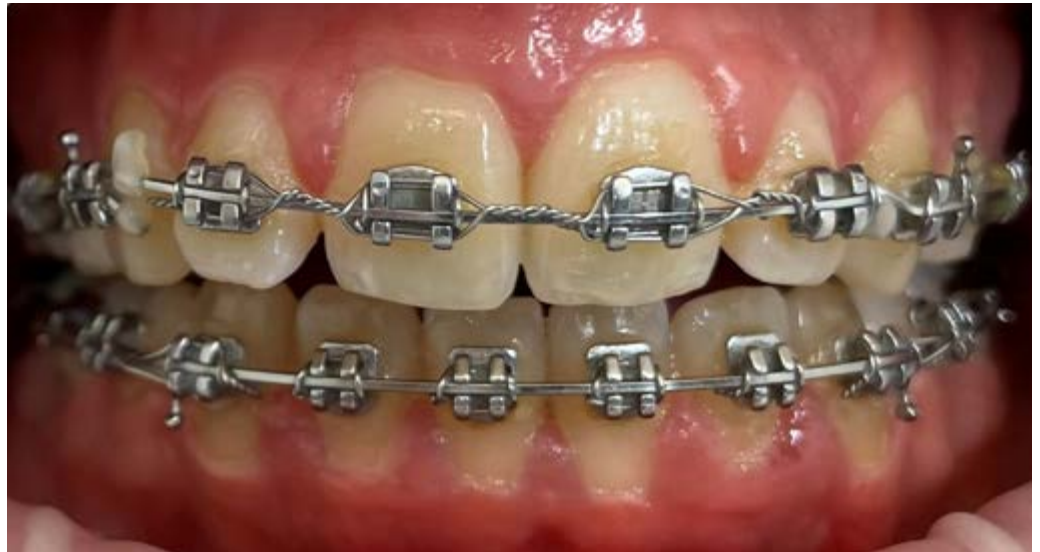PATIENT FEEDBACK

"I ENJOYED MY APPOINTMENT WITH ESTHER! IT'S BEEN RELAXING, GENTLE AND I NOW FEEL MY TEETH LIKE I'VE NEVER FELT THEM BEFORE! I FEEL GOOD!"

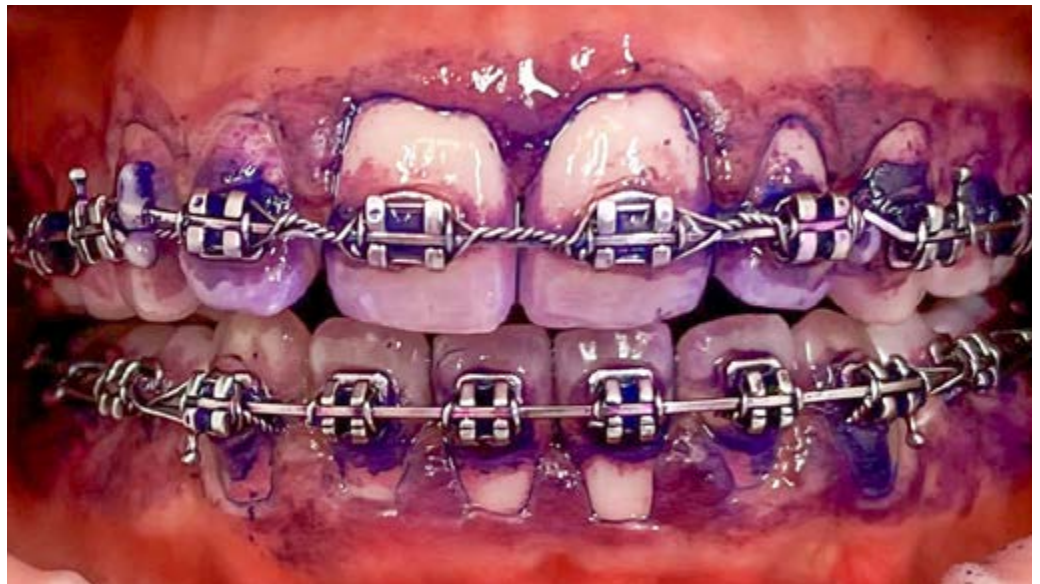& GBT



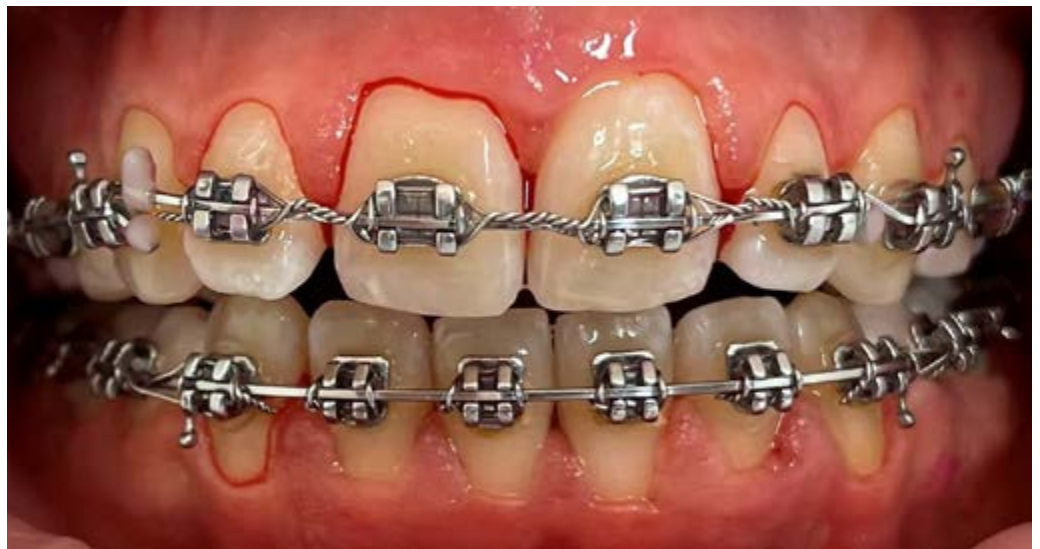BEFORE GBT



**AFTER
DISCLOSING**



AFTER GBT



ORTHODONTICS

CASE 70



CLINICIAN

Kim Eunae
Dental hygienist
South Korea

PATIENT INFORMATION

- ▶ Age 15, female.

BACKGROUND INFORMATION

- ▶ Poor oral hygiene. The patient was having difficulty in self-management due to irregular teeth alignment. Her parents made her visit the clinic, but oral health motivation was very low.

CLINICAL FINDINGS

- ▶ Generalized bleeding present. Swollen gingiva, presence of large amounts of supragingival calculus. After the bracket was installed, self-management was more difficult, and motivation and direct patient engagement were needed for improvement..

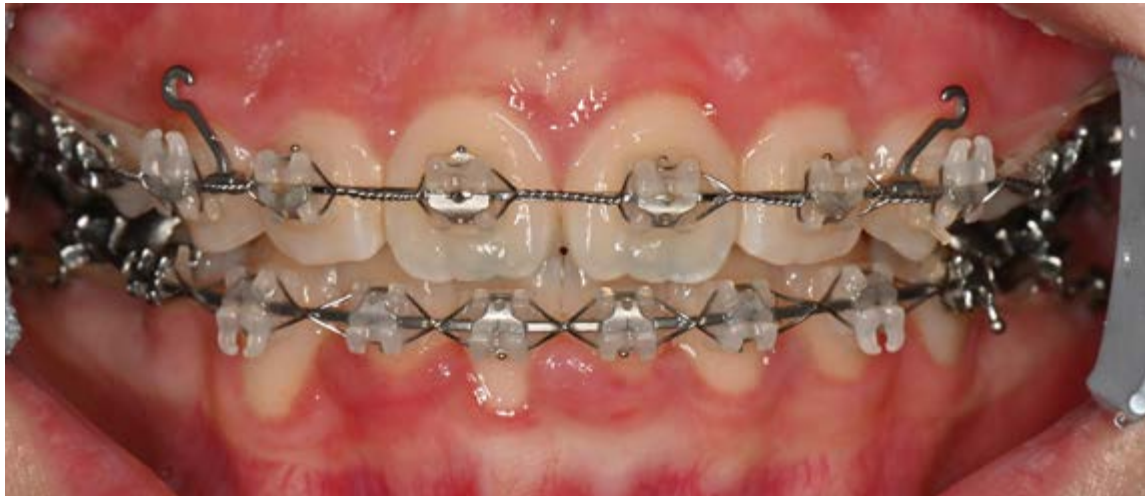TREATMENT

- ▶ The areas requiring self-care were shown after disclosing, and TBI was provided for brushing around the brackets and gingival area. The disclosed biofilm area was brushed by the patient and tooth brushing instructions. Used PS Instrument for removing calculus. The patient started to enjoy GBT. Currently, the recall interval has been extended from one or two months to three months.

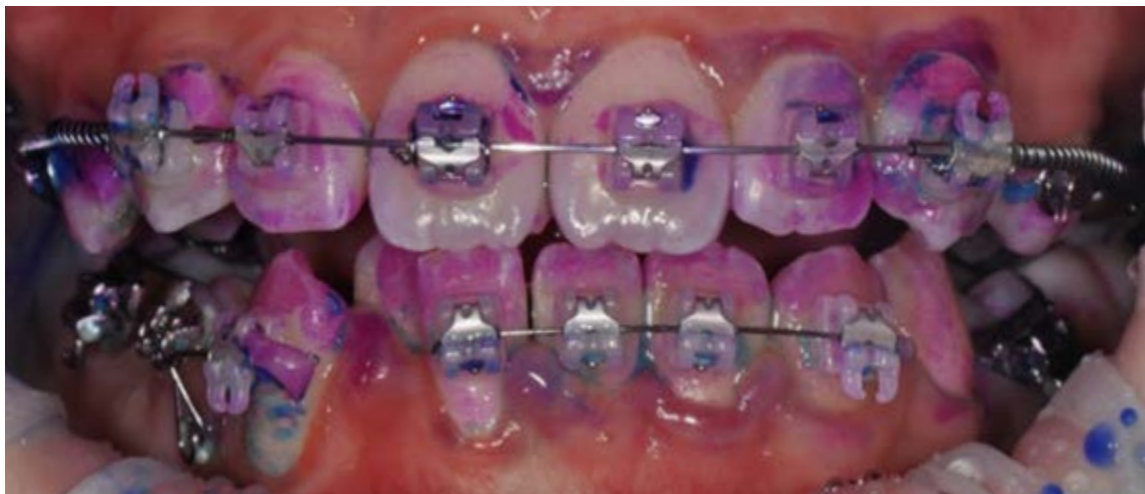PATIENT FEEDBACK

“THANK YOU FOR ALWAYS TAKING GOOD CARE OF MY DAUGHTER.”

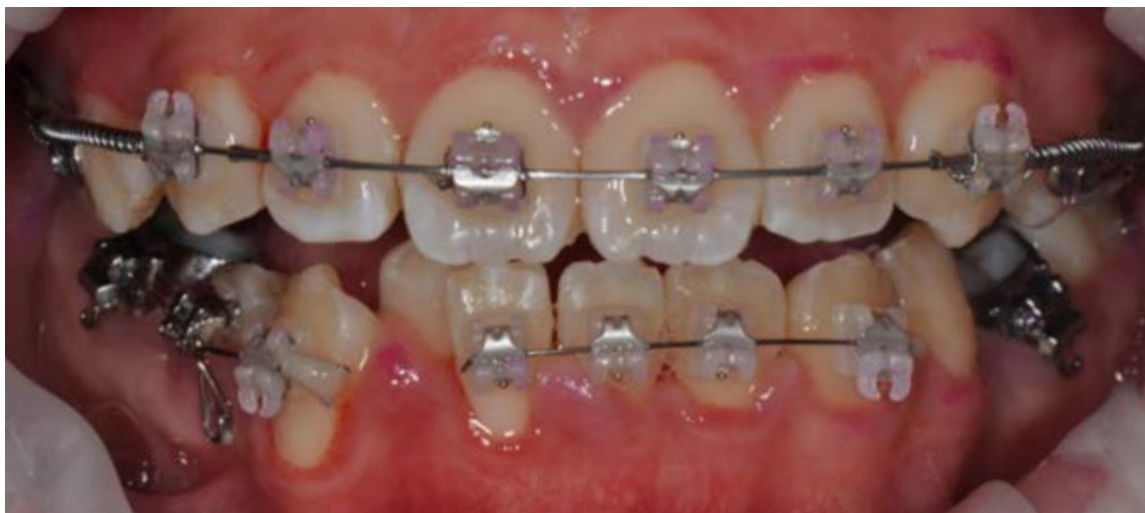BEFORE GBT



AFTER DISCLOSING



AFTER GBT



ORTHODONTICS

CASE 71



CLINICIAN

Francesca Gammino
Dental hygienist
Italy

PATIENT INFORMATION

- ▶ Age 13, male.

BACKGROUND INFORMATION

- ▶ The patient eats a lot of sweets during the day. I motivated him to use the toothbrush and the brush. The patient decided not to brush his teeth for fear that the appliance would become detached.

CLINICAL FINDINGS

- ▶ Gingivitis, biofilm ++, BOP +.

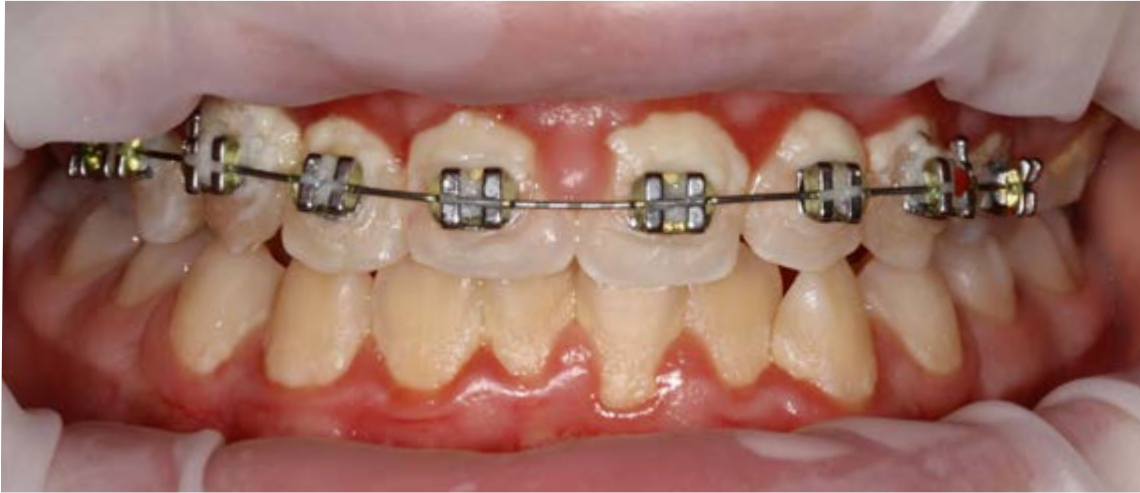TREATMENT

- ▶ A GBT session with AIRFLOW® MAX, AIRFLOW® PLUS Powder and PIEZON® PS Instrument.

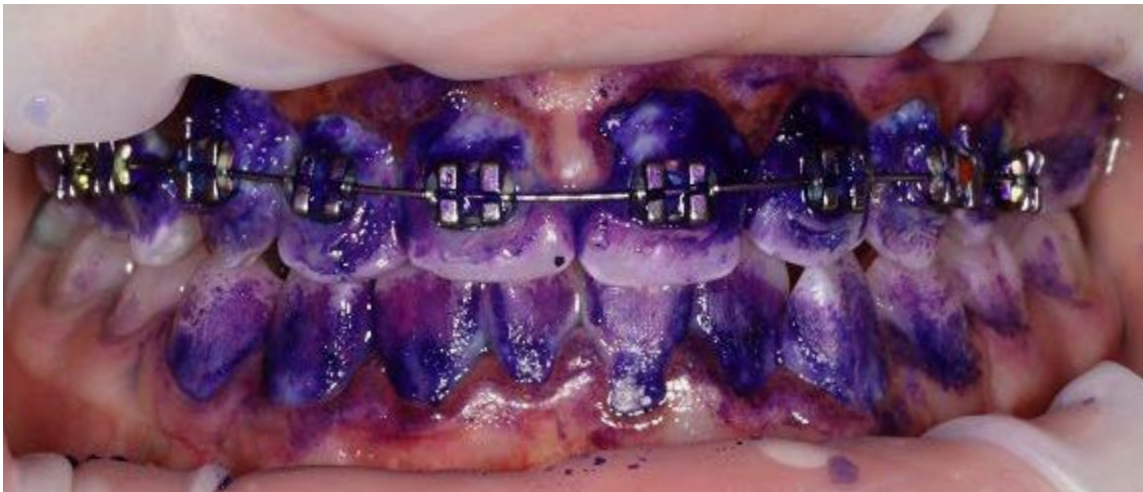PATIENT FEEDBACK

**“I AM HAPPY AND FINALLY UNDERSTOOD THE IMPORTANCE
OF ORAL HYGIENE.”**

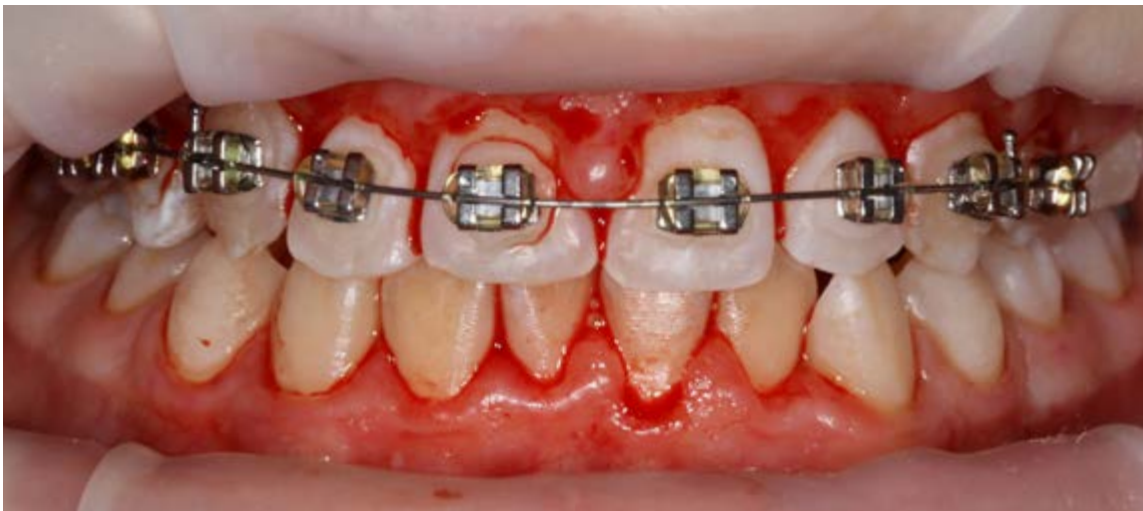
BEFORE GBT



AFTER DISCLOSING



AFTER GBT



ORTHODONTICS

CASE 72



CLINICIAN

Karolina Hrušová
Dental hygienist
Czech Republic

PATIENT INFORMATION

- ▶ Age 31, female.

BACKGROUND INFORMATION

- ▶ The patient came for dental hygiene one year ago. She has received Invisalign orthodontic therapy for 8 months. Aligners are removed before each meal and cleaned by patient properly and regularly. She is bothered by stains on her teeth, which she is not able to remove by herself at home. Smoker.

CLINICAL FINDINGS

- ▶ Presence of numerous stains, biofilm around attachments, inflammation in interdental areas, calculus behind front teeth in lower jaw.

TREATMENT

- ▶ Dental hygiene done according toGBT protocol. Biofilm disclosed. Biofilm and stains removed with AIRFLOW® PLUS Powder, calculus with PIEZON® PS. Motivated and instructed the patient (recommendation for single tooth brush and interdental brushes). Recall set up every 3 months. Aligners were also cleaned with AIRFLOW® PLUS Powder. Recall after 3 months: Significantly improved patient's dental hygiene. No inflammation, fewer stains.

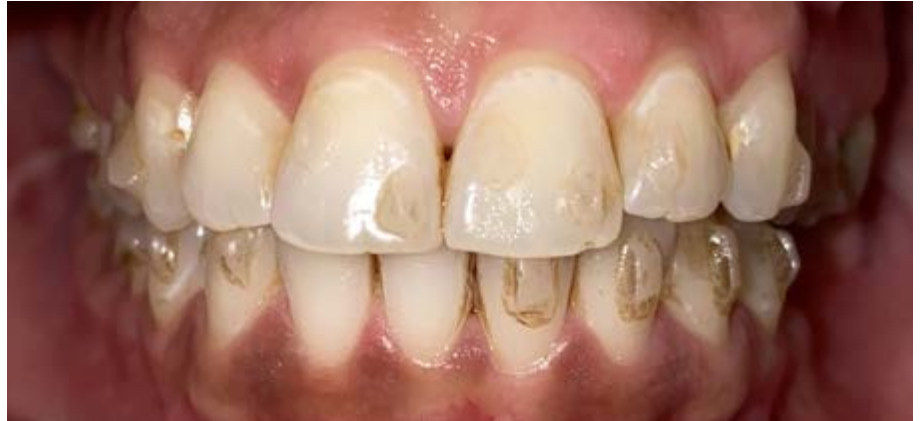PATIENT FEEDBACK

“AFTER TREATMENT MY TEETH LOOK BEAUTIFUL, ATTACHMENTS ARE NOT VISIBLE ANYMORE AND STAINS DO NOT FORM AS BEFORE!”

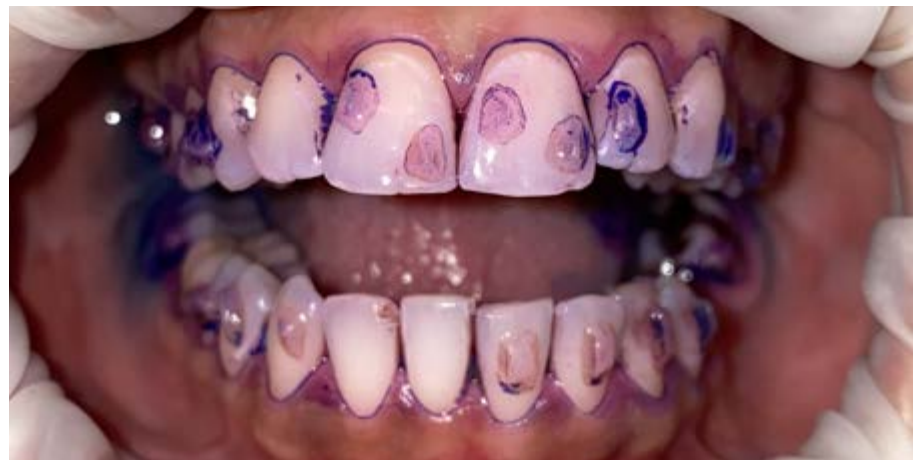& GBT



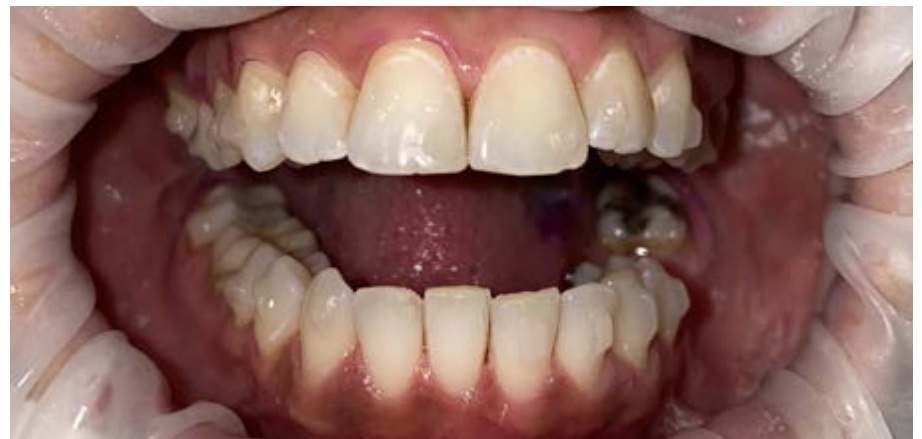BEFORE GBT



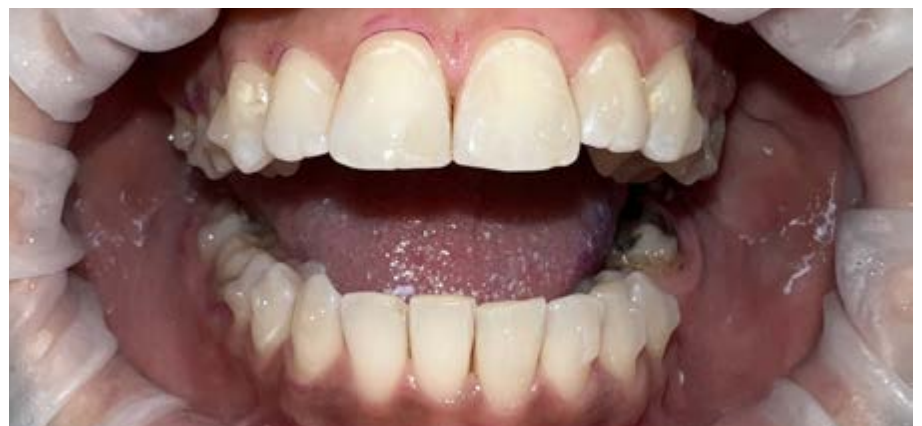AFTER DISCLOSING



AFTER GBT



3-MONTH RECALL



ORTHODONTICS

CASE 73



CLINICIAN

Monika Gałarczyk
Dental hygienist
Poland

PATIENT INFORMATION

- ▶ Age 27, male.

BACKGROUND INFORMATION

- ▶ A healthy patient, he has been wearing a fixed orthodontic appliance for 8 months. Inadequate oral hygiene.

CLINICAL FINDINGS

- ▶ Presence of supragingival calculus, deposits and visible biofilm. The patient only uses a manual toothbrush. He does not use interdental aids or an irrigator. The patient asks for advice on how to avoid the formation of plaque and interdental calculus.

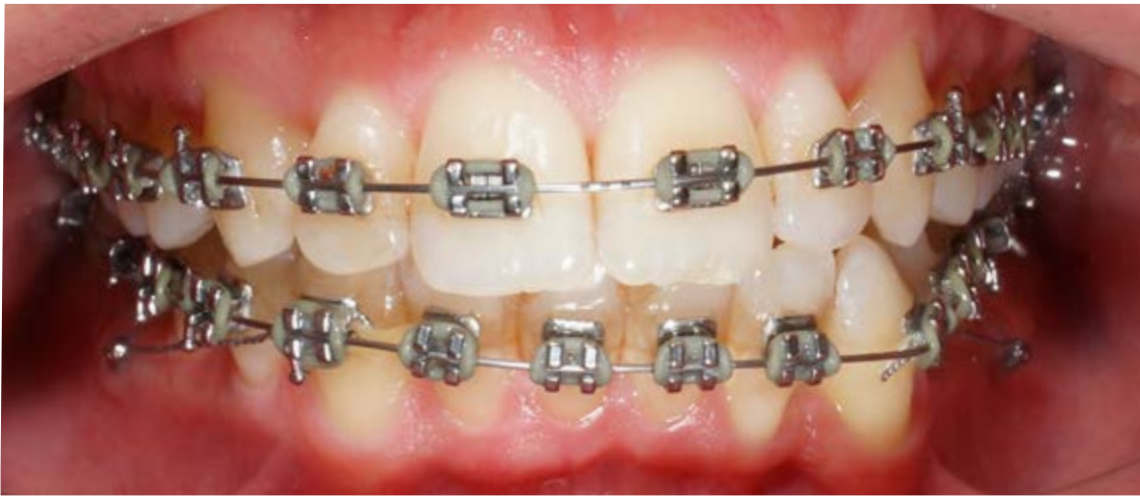TREATMENT

- ▶ GBT was performed with AIRFLOW® PLUS Powder and PIEZON® PS Instrument. The focus was on education. Another instruction on the use of additional aids in the form of interdental brushes was carried out. The use of an irrigator was recommended.

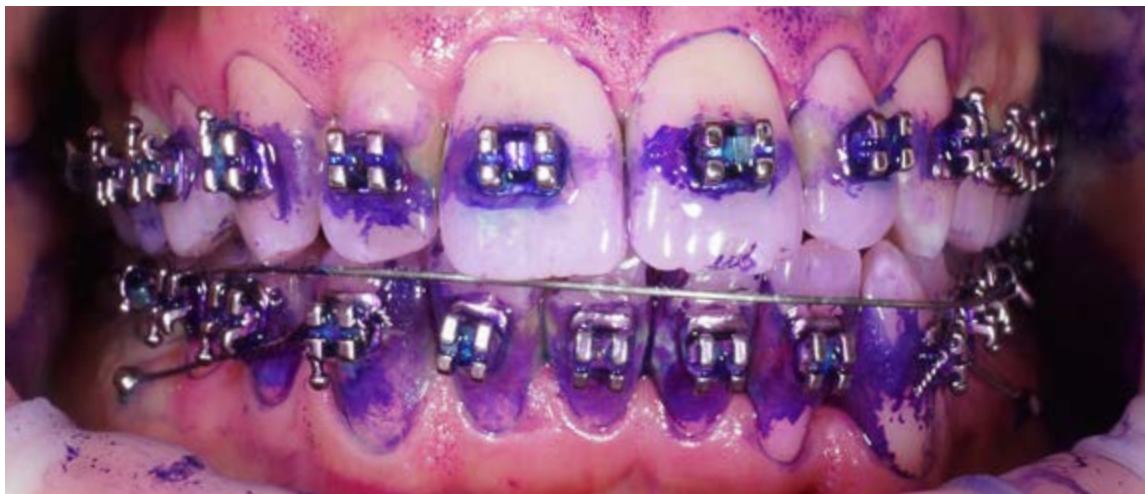PATIENT FEEDBACK

“I FEEL SO CLEAN. MY ORTHODONTIC APPLIANCE FEELS LIKE NEW.”

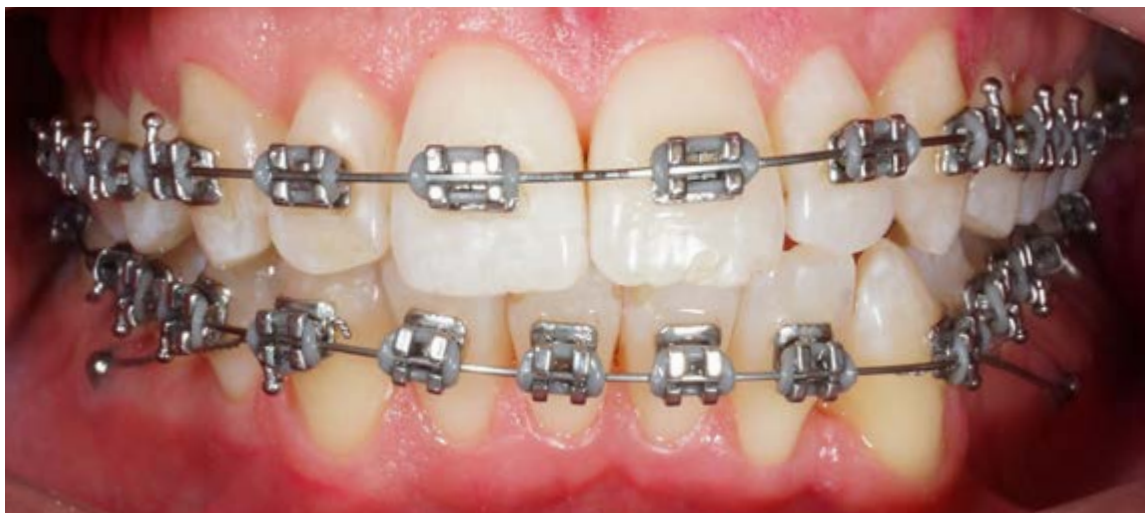BEFORE GBT



AFTER DISCLOSING



AFTER GBT



ORTHODONTICS

CASE 74



CLINICIAN

Ke Rongji
Dentist
China

PATIENT INFORMATION

- ▶ Age 20, female.

BACKGROUND INFORMATION

- ▶ Orthodontic referral for treatment due to poor oral hygiene and discoloration of anterior teeth.

CLINICAL FINDINGS

- ▶ Brackets and arch wires can be seen on the tooth surface, and tons of plaques and soft dirt accumulation can be seen on the adjacent surface of the anterior teeth.

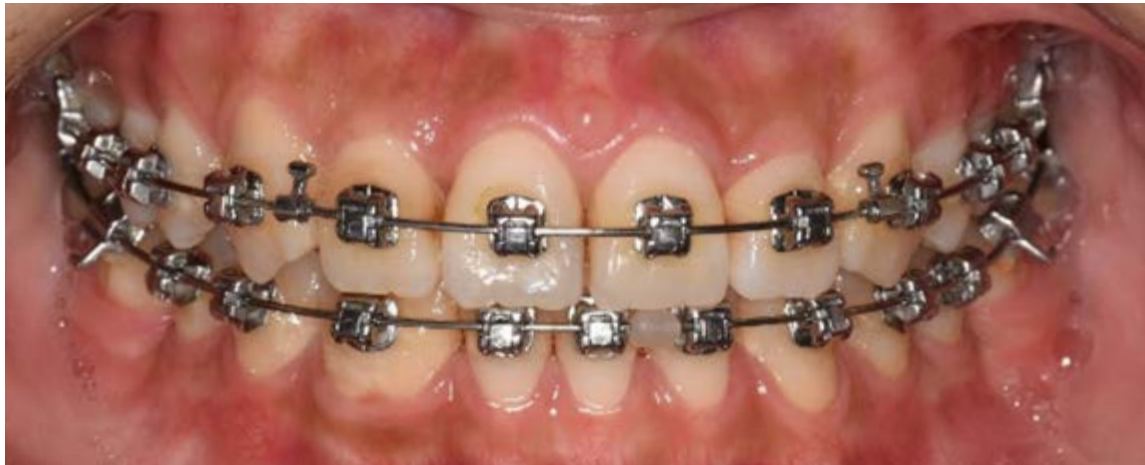TREATMENT

- ▶ Dental caries covered by plaque is difficult to find. Using the AIRFLOW® to remove biofilm is more convenient for dental exam. Choosing AIRFLOW® PLUS Powder to ensure the efficiency of cleaning while being minimally invasive.

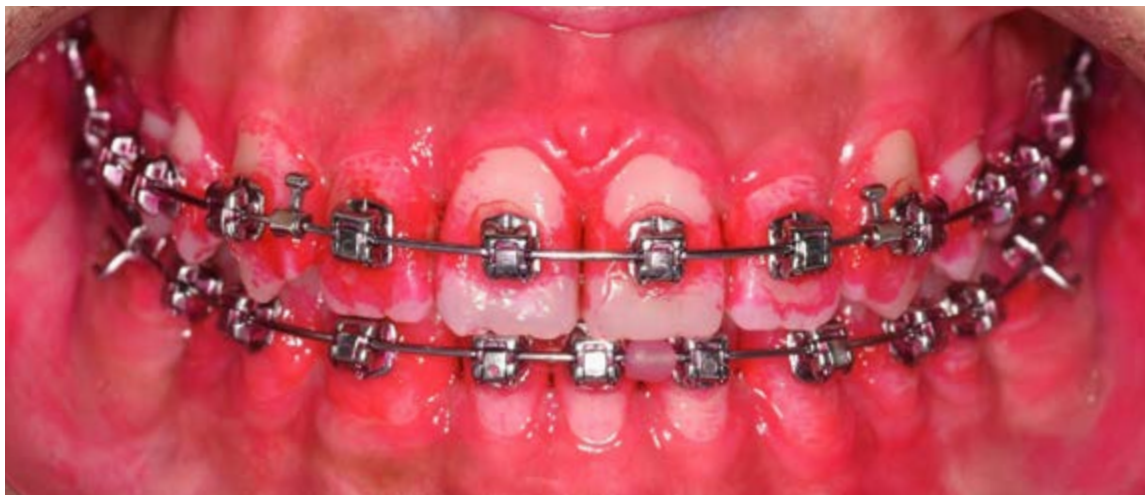
PATIENT FEEDBACK

“UNPARALLELED WONDERFUL EXPERIENCE ! LOVE GBT !”

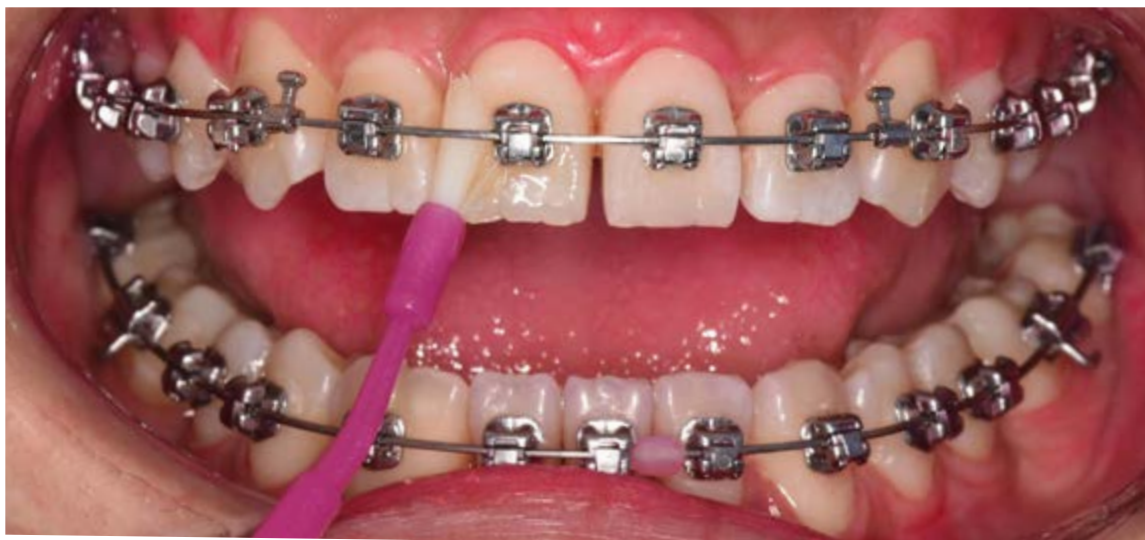BEFORE GBT



AFTER DISCLOSING



AFTER GBT



ORTHODONTICS

CASE 75



CLINICIAN

Khalid M Hannouneh
Dentist
UAE

PATIENT INFORMATION

► Age 33, female.

BACKGROUND INFORMATION

► Overall poor oral hygiene, With a history of orthodontic treatment. No relevant habits.

CLINICAL FINDINGS

► BOP -, supragingival calculus present. She has attachments on the teeth for the invisible aligner treatment. Doesn't brush her teeth regularly and doesn't use floss. Patient came mainly to improve the color of her teeth

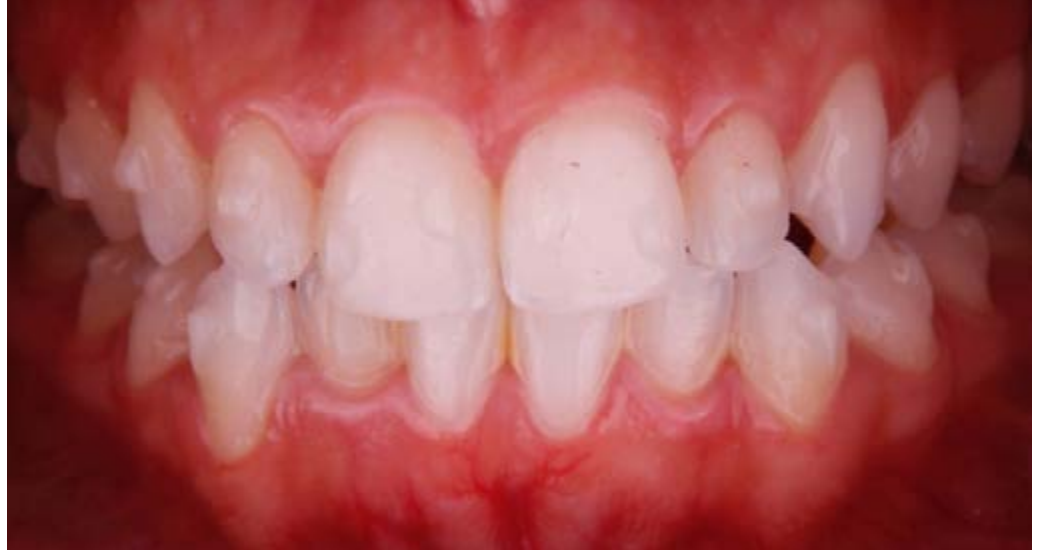TREATMENT

► Patient education about follow-up every 4 months. GBT was done with emphasis on disclosing agent and patient education. She saw the biofilm distribution and understood the importance of GBT and flossing. AIRFLOW® PLUS Powder was used to remove all biofilm followed by PIEZON® PS Instrument.

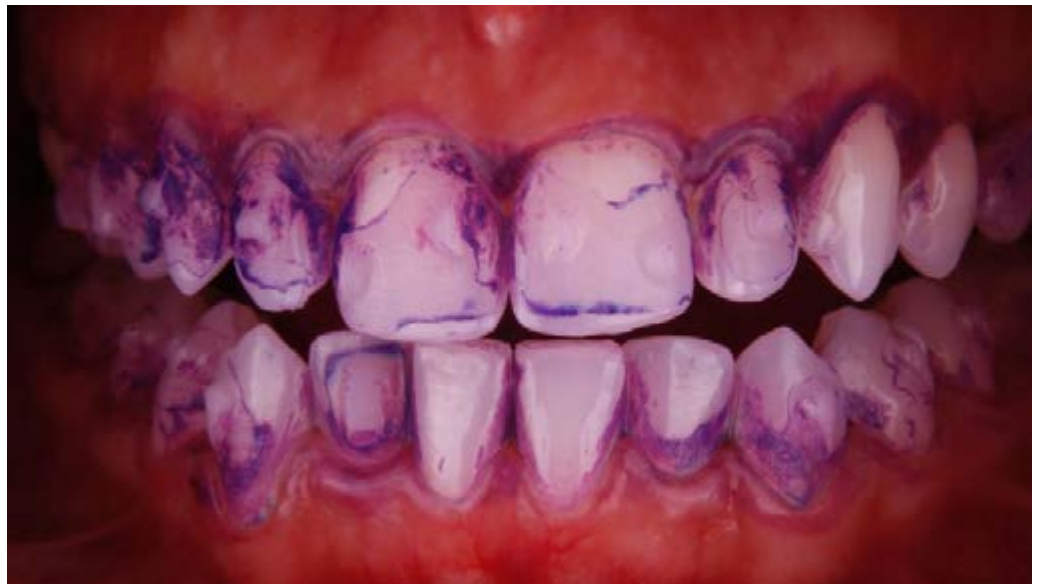PATIENT FEEDBACK

“I AM CONFIDENT THAT MY ATTACHMENTS HAVE BEEN CLEANED AND THAT MY PROPHYLAXIS TREATMENT WITH GBT WILL GIVE ME BETTER ORAL HEALTH.”

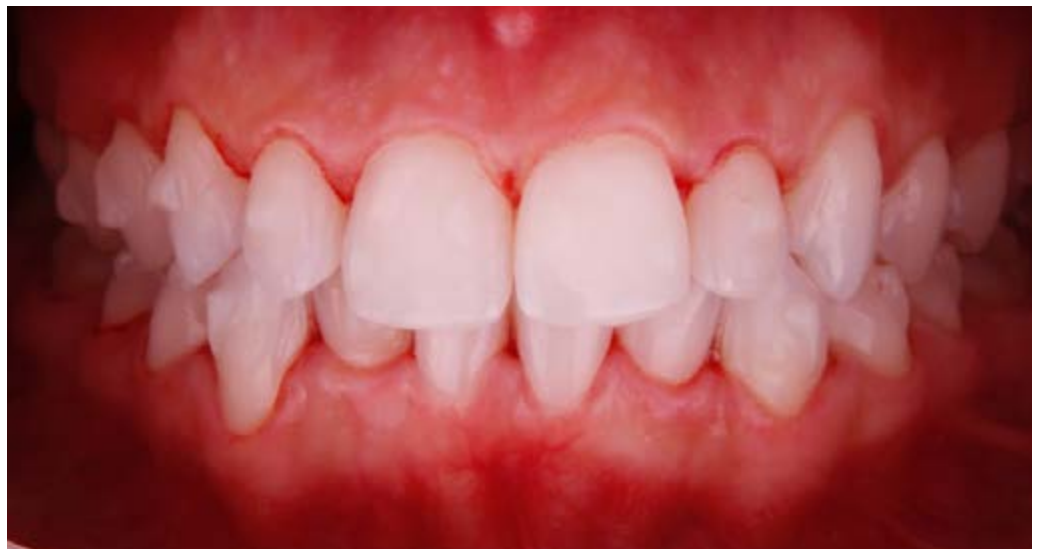BEFORE GBT



AFTER DISCLOSING



AFTER GBT



ORTHODONTICS

CASE 76



CLINICIAN

Leon Zhong Hong
Dentist
China

PATIENT INFORMATION

- ▶ Age 22, female.

BACKGROUND INFORMATION

- ▶ The patient started orthodontics a few months ago. It was inconvenient to brush her teeth during the period. Recently, she felt that her teeth were gradually yellowish, so she asked for professional cleaning. Has a history of tooth extraction but no history of systemic diseases.

CLINICAL FINDINGS

- ▶ Orthodontic routine follow-up, requiring teeth cleaning.

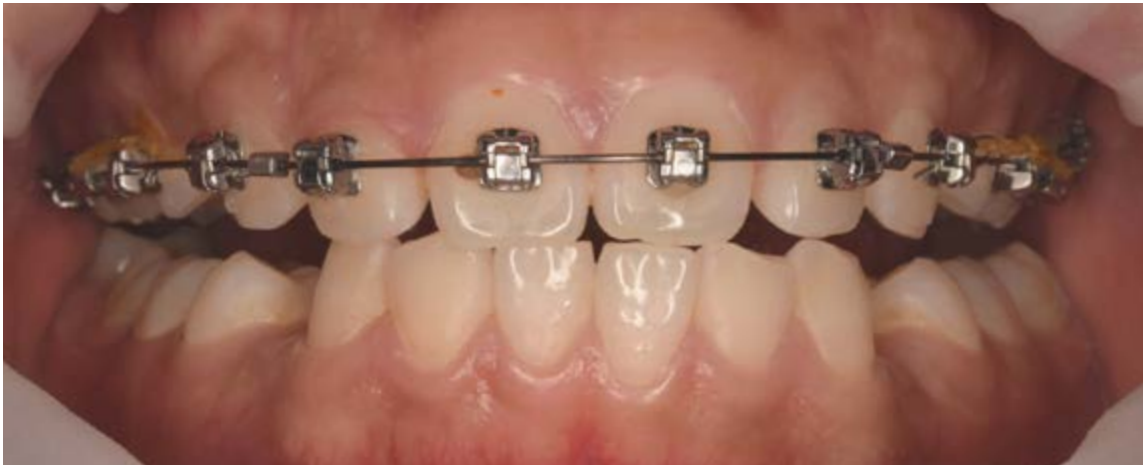TREATMENT

- ▶ GBT full mouth cleaning and orthodontic bracket cleaning. AIRFLOW® MAX was used with AIRFLOW® PLUS Powder.

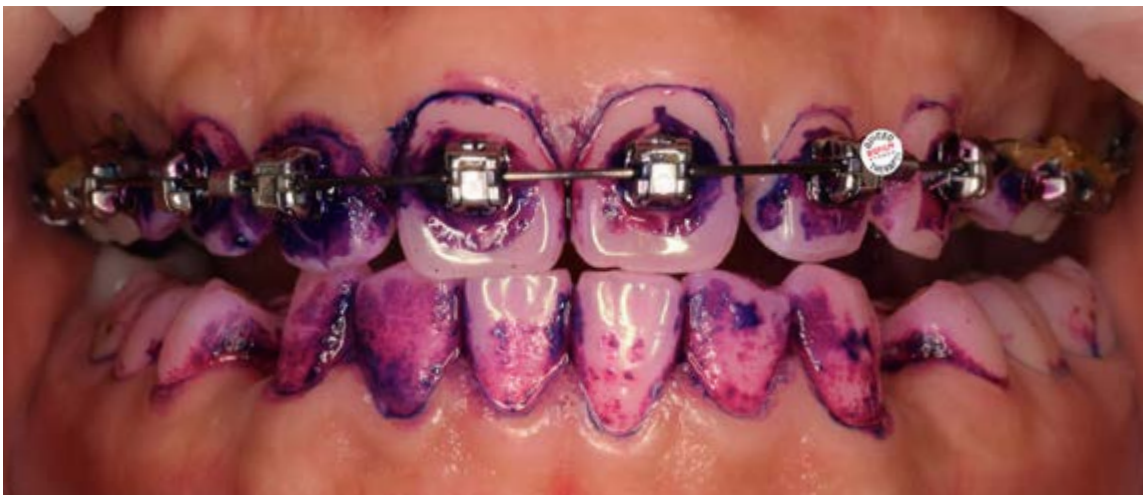PATIENT FEEDBACK

**“FEELING SUPER GOOD WHEN ORTHODONTIC BRACKET IS CLEAN!
I LOVE GBT!”**

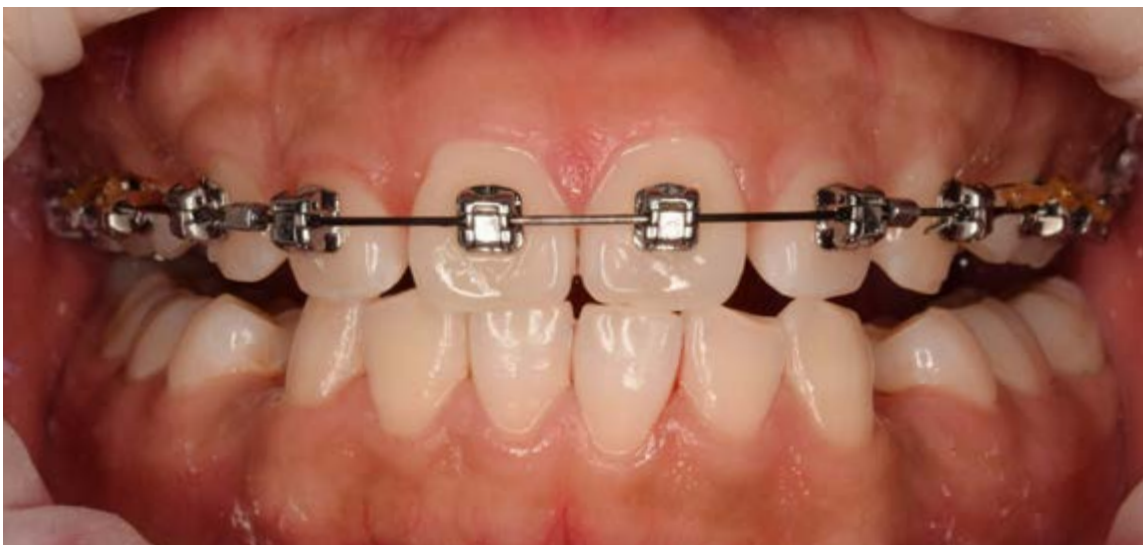BEFORE GBT



AFTER DISCLOSING



AFTER GBT



ORTHODONTICS

CASE 77



CLINICIAN

Liu Zheng
Dentist
China

PATIENT INFORMATION

- ▶ Age 21, female.

BACKGROUND INFORMATION

- ▶ Nurse, came for an orthodontic follow up. orthodontic treatment was started 1 year ago. GBT was performed every six months. Tooth extraction done because of orthodontic treatment. No systemic diseases.

CLINICAL FINDINGS

- ▶ Presence of gingivitis, BOP +. Average oral hygiene.

TREATMENT

- ▶ GBT with AIRFLOW® PLUS Powder. Lots of motivation including use of oral hygiene aids.

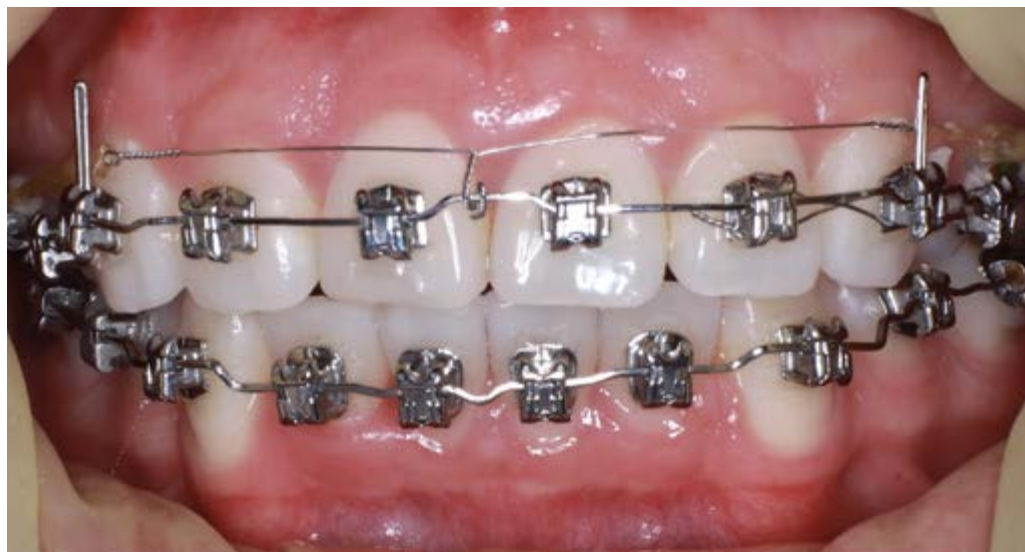PATIENT FEEDBACK

“BIOFILM DISCLOSING MAKES ME REALIZE THERE SO MUCH HORRIBLE BIOFILM AROUND THE BRACKET IN MY MOUTH. GBT CLEARED IT QUICKLY AND COMPLETELY !”

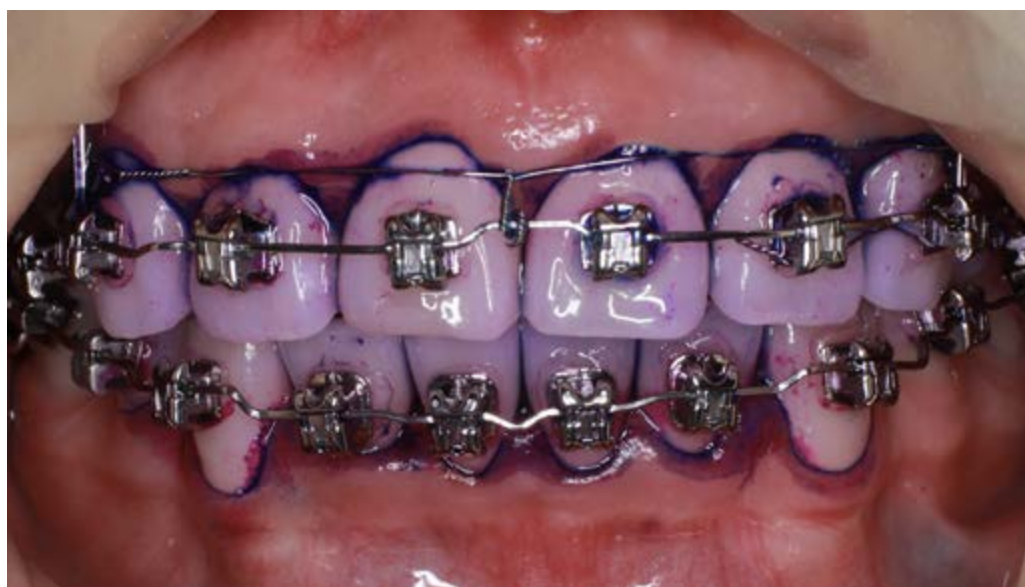& GBT



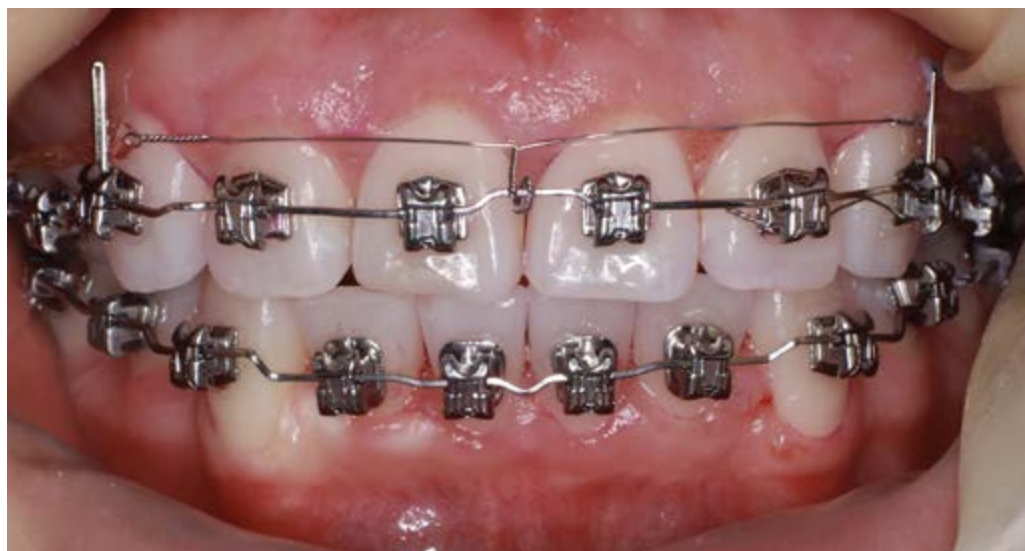BEFORE GBT



AFTER DISCLOSING



AFTER GBT



ORTHODONTICS

CASE 78



CLINICIAN

Magdalena Michałowska
Dental hygienist
Poland

PATIENT INFORMATION

- ▶ Age 28, female.

BACKGROUND INFORMATION

- ▶ The patient has been treated with Invisalign appliance for a year. There are attachments bonded to the teeth. Very poor oral hygiene. Professional hygiene has never been performed while wearing the appliance. No relevant habits.

CLINICAL FINDINGS

- ▶ Generalized gingival inflammation. Massive biofilm, supragingival calculus. BOP ++. Numerous, extensive enamel decalcifications.

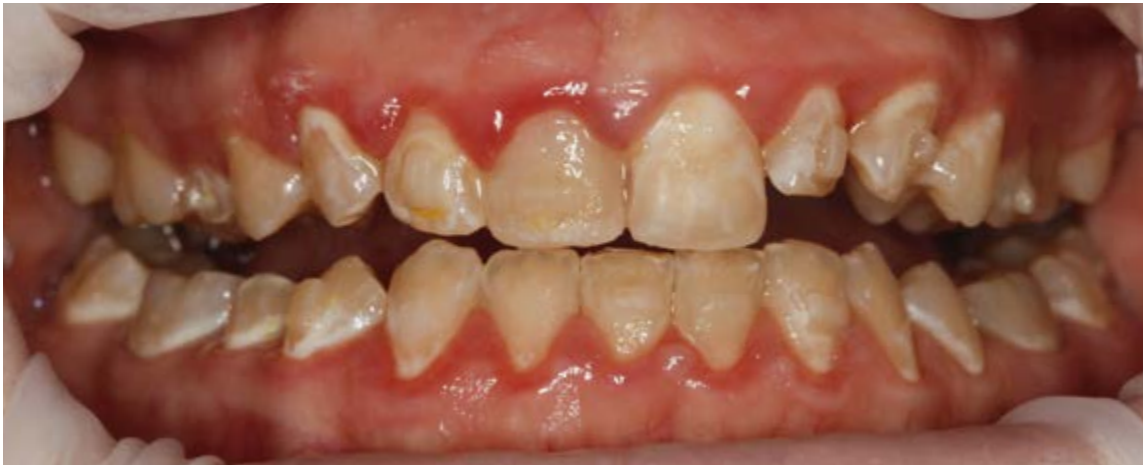TREATMENT

- ▶ The GBT procedure was performed, the next control visit was scheduled for 1 month later. Subsequent visits take place every 3 months. Thorough oral hygiene instructions were carried out along with motivation. It was recommended to use a soft brush at the beginning, then switch to an electric OralB toothbrush. It is necessary for a patient to use dental floss.

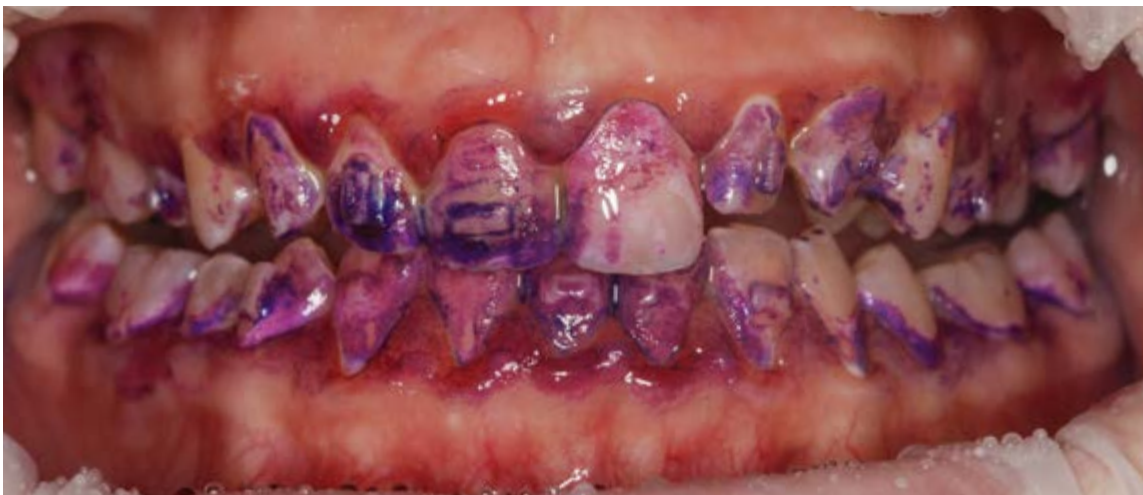PATIENT FEEDBACK

**“NEVER REALIZED THAT MY ATTACHMENTS NEEDED TO BE CLEANED.
GBT ASSURES ME THERE IS NO DAMAGE. THANK YOU!”**

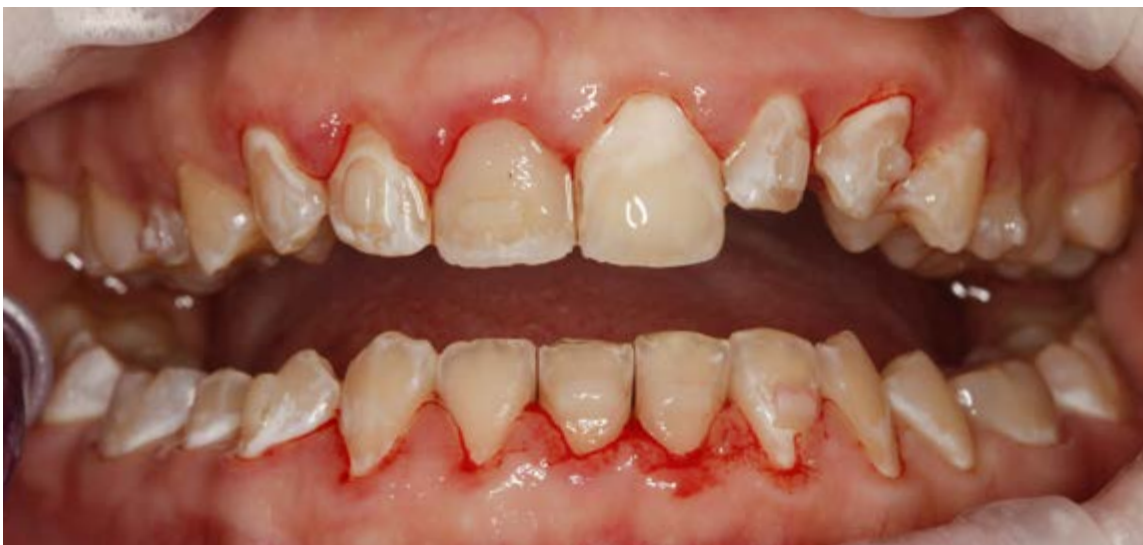BEFORE GBT



AFTER DISCLOSING



AFTER GBT



ORTHODONTICS

CASE 79



CLINICIAN

Maria Fernanda Kolbe
Dental hygienist
Brazil

PATIENT INFORMATION

- ▶ Age 26, male.

BACKGROUND INFORMATION

- ▶ He works in the financial market, is a sportsman, has a healthy and slightly acidic diet. He doesn't smoke, he drinks 3 coffees a day and occasionally red wine. Patient reports brushing his teeth 3 times a day and flossing "almost every night". Came to the office for prophylaxis and check-up, complaining of "bleeding gums".

CLINICAL FINDINGS

- ▶ On clinical examination, he was diagnosed with generalized gingivitis, bleeding on probing in more than 50% of the sites and gingival hyperplasia in the lower anterior teeth.

TREATMENT

- ▶ Used GBT protocol on patient. He had no idea how poor his hygiene was. Subsequently, he was instructed on the technique of flossing, brushing and interdental brushing. Despite the bleeding, patient reported not feeling any pain or even discomfort during AIRFLOWING with AIRFLOW® PLUS. As there were no pockets larger than 4mm, the PERIOFLOW® step was skipped. After removing all biofilm, a PIEZON® PS Instrument was used to remove calculus from lower anterior teeth.

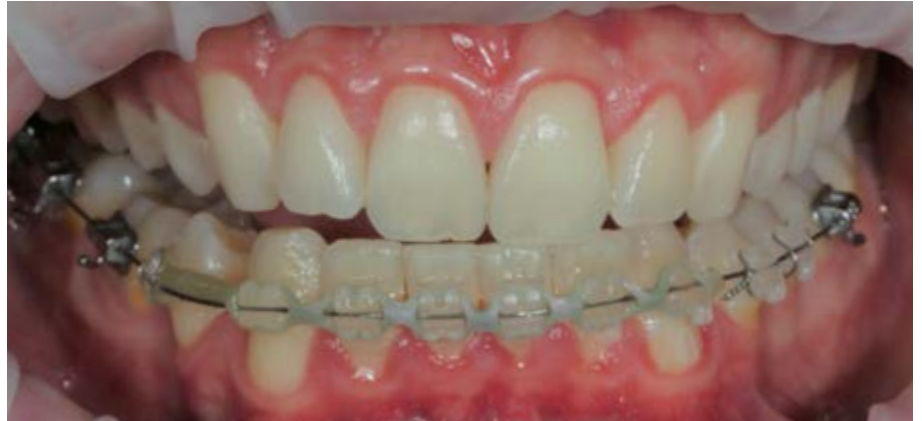PATIENT FEEDBACK

"I WANT TO DO THIS PROPHYLAXIS EVERY 4 MONTHS AND NEVER LEAVE MY MOUTH LIKE THIS AGAIN! I DON'T WANT TO KNOW ABOUT ANY OTHER KIND OF CLEANING..."

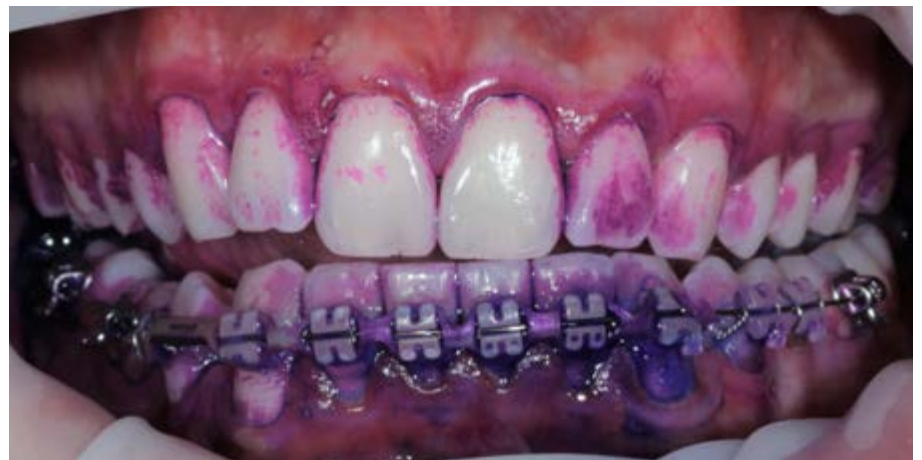& GBT



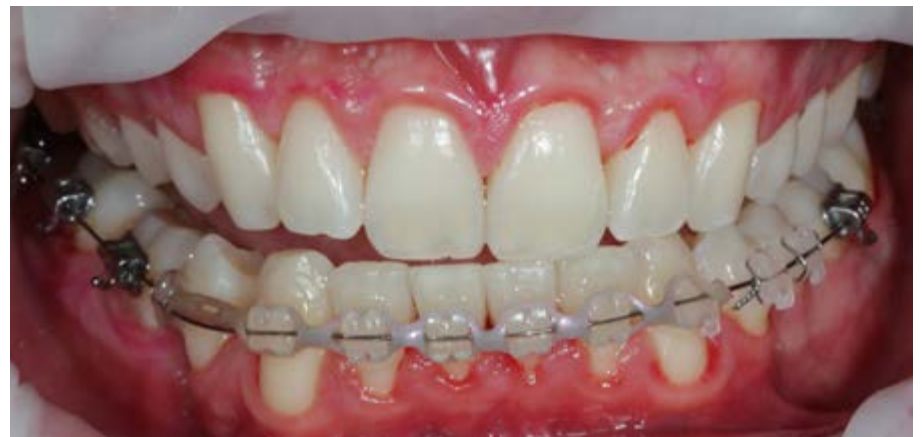BEFORE GBT



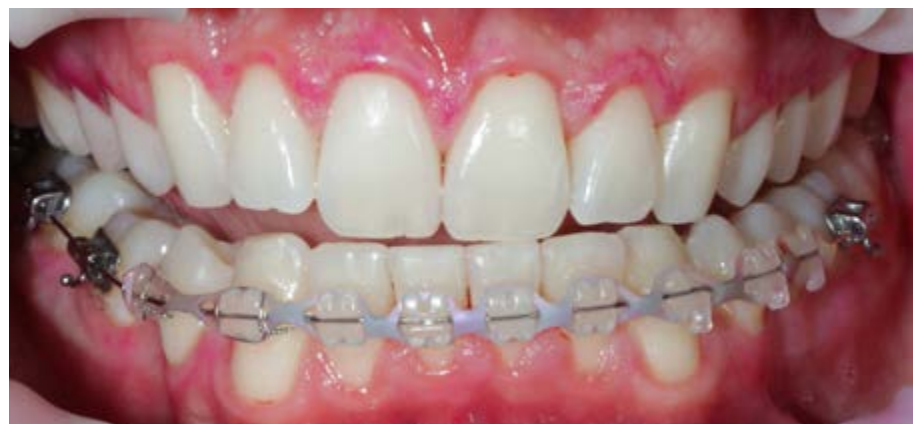AFTER DISCLOSING



AFTER GBT



6-MONTH RECALL



ORTHODONTICS

CASE 80



CLINICIAN

Mariana Fonseca
Periodontist
Brazil

PATIENT INFORMATION

- ▶ Age 60, male.

BACKGROUND INFORMATION

- ▶ With a history of periodontal disease returning for maintenance after 1 year. Smoker with poor oral hygiene and under orthodontic treatment.

CLINICAL FINDINGS

- ▶ Poor plaque control, bleeding on probing with gingivitis and some periodontal pockets.

TREATMENT

- ▶ Performed GBT protocol, starting with oral hygiene guidance to improve dental plaque control, followed by AIRFLOW® and AIRFLOW® PLUS Powder and PIEZON® PS Instrument (subgingival)..

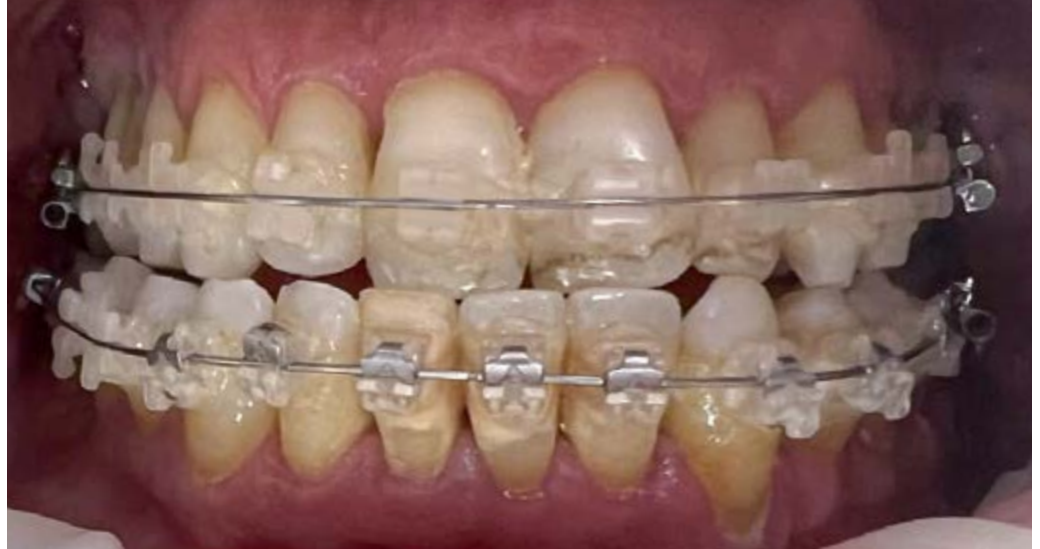PATIENT FEEDBACK

“I FOUND THE NEW PROTOCOL INTERESTING. THE BIG DIFFERENCE FOR ME WAS THE WARM WATER. I DIDN’T FEEL ANY DISCOMFORT. THANKS FOR THE EXCELLENT SERVICE AND TREATMENT!”

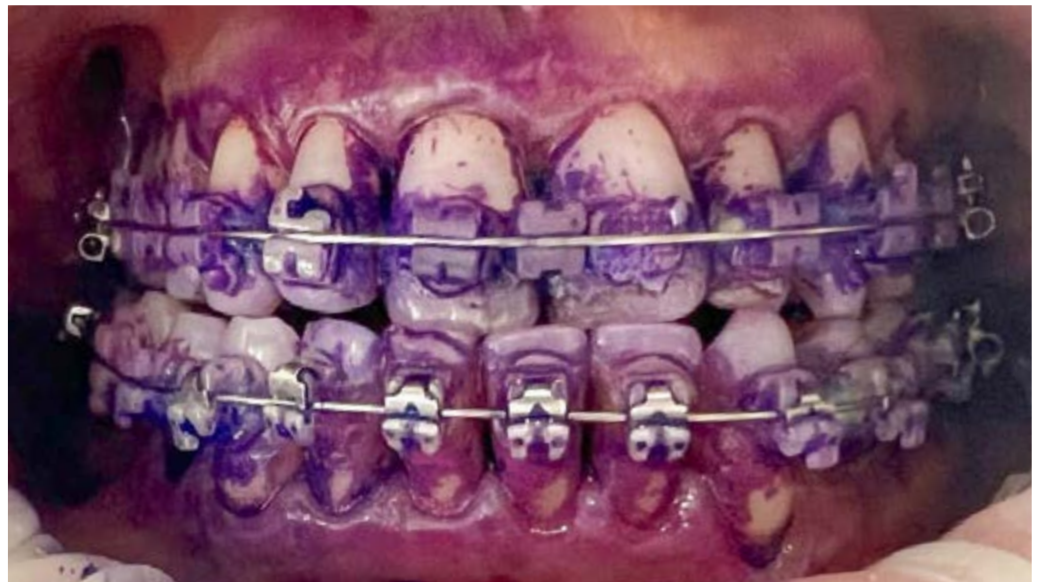& GBT



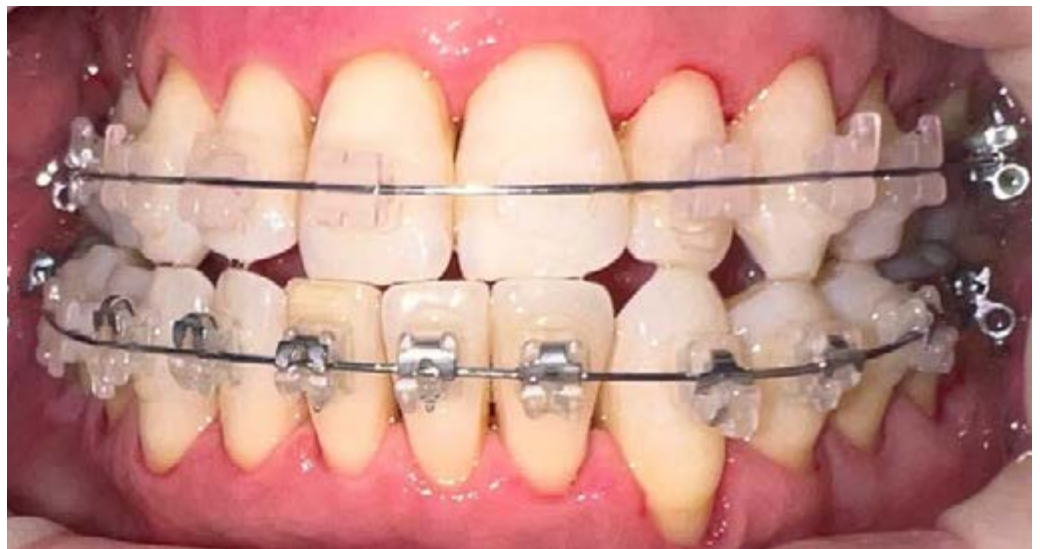BEFORE GBT



AFTER DISCLOSING



AFTER GBT



ORTHODONTICS

CASE 81



CLINICIAN

Marina Rusu
Dental hygienist
Italy

PATIENT INFORMATION

- ▶ Age 21, male.

BACKGROUND INFORMATION

- ▶ He is in his second year of university specializing in law. He uses a hard manual toothbrush and he doesn't use any device for interproximal hygiene or for fixed braces. He practices football three times a week. Smoker, no drinking or other relevant habits.

CLINICAL FINDINGS

- ▶ Gingivitis and gum recession.

TREATMENT

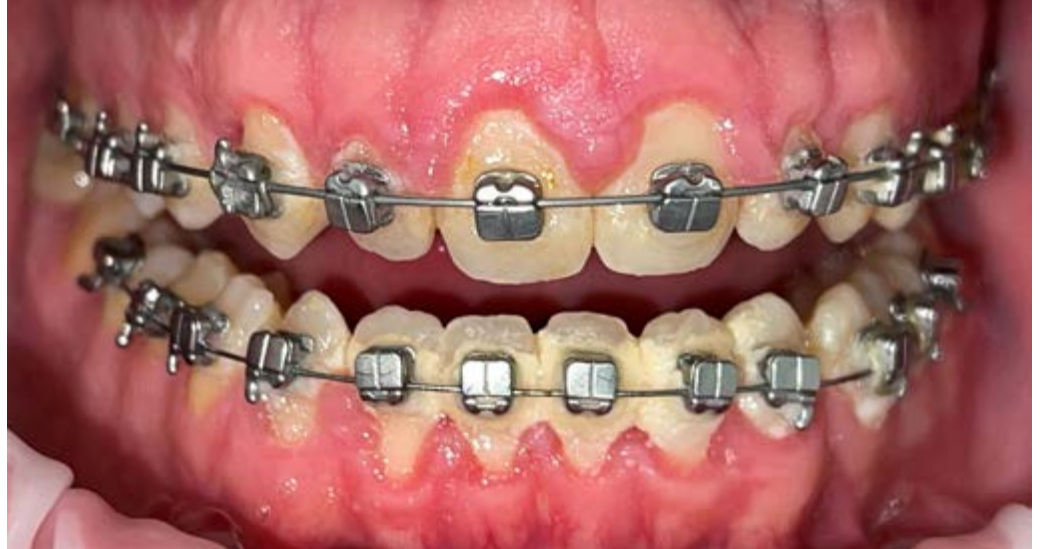- ▶ The biofilm was highlighted with EMS Biofilm Discloser and the patient was motivated. The biofilm and smoke stains were removed with AIRFLOW® PLUS Powder. I then used PIEZON® PS Instrument to remove remaining calculus. After the final check we fixed the recall after 4 months.

PATIENT FEEDBACK

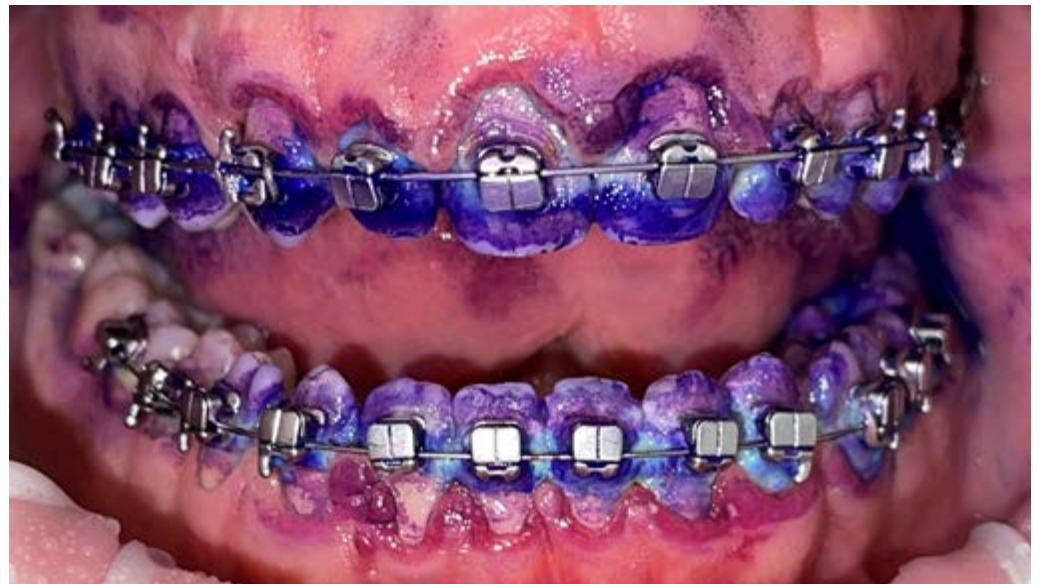“THIS NEW PROTOCOL HAS BEEN REALLY HELPFUL IN UNDERSTANDING WHERE I DON'T BRUSH WELL. I WOULD ALSO LIKE TO USE THIS METHOD IN THE FUTURE.”

& GBT

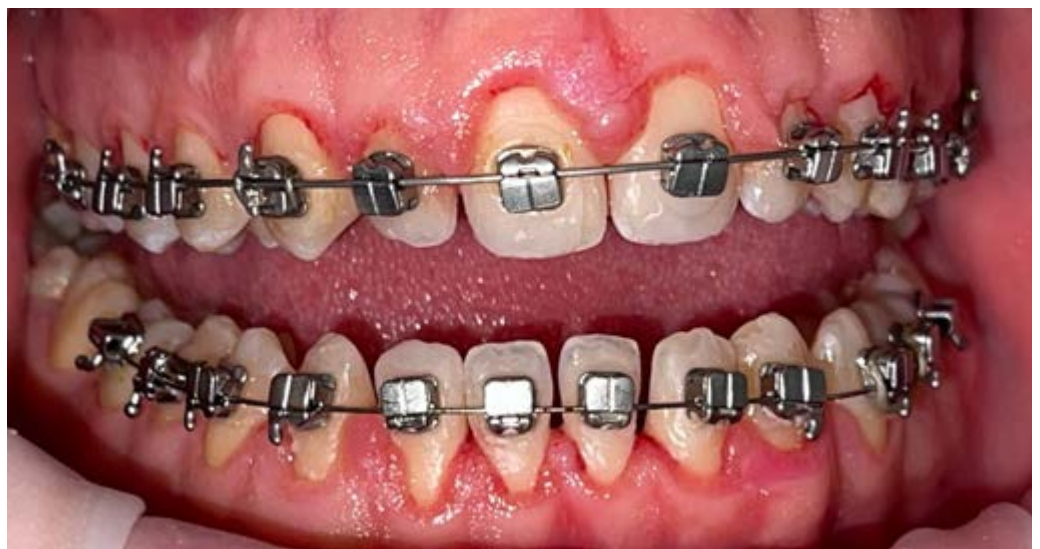BEFORE GBT



AFTER DISCLOSING



AFTER GBT



ORTHODONTICS

CASE 82



CLINICIAN

Zhang Li
Dental hygienist
China

PATIENT INFORMATION

► Age 28, male.

BACKGROUND INFORMATION

► Orthodontic patient, Poor brushing habits. Gingival recession existed before orthodontic treatment.

CLINICAL FINDINGS

► Poor oral hygiene, Lots of calculus visible. Patient was never instructed on oral hygiene and health. Never used interdental aids.

TREATMENT

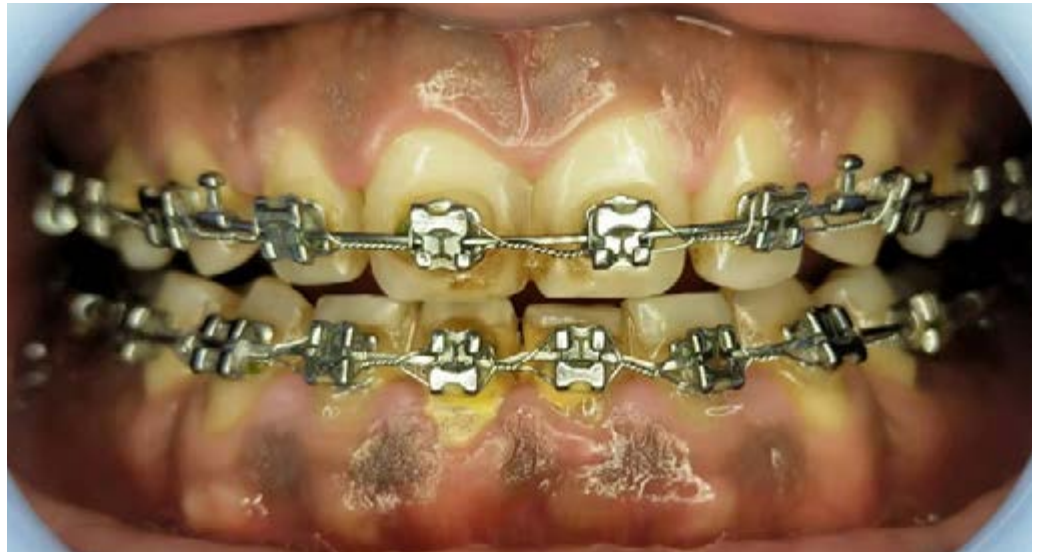► GBT done using both AIRFLOW® and PIEZON® to remove biofilm, stain and calculus very quickly. Attention paid to patient's cleaning habits and routine.

PATIENT FEEDBACK

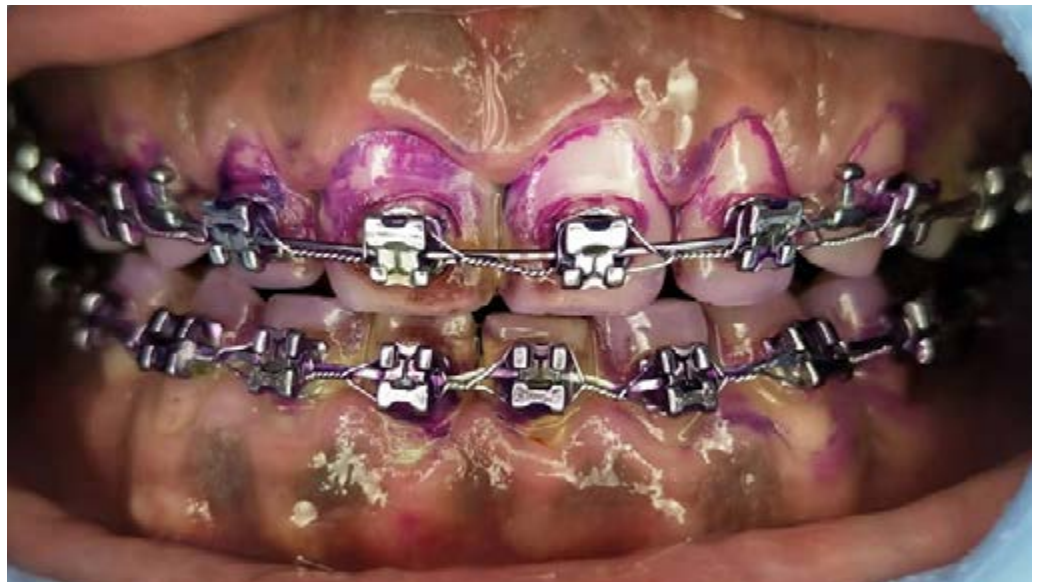“THIS IS WHAT CLEAN REALLY FEELS LIKE!”

& GBT

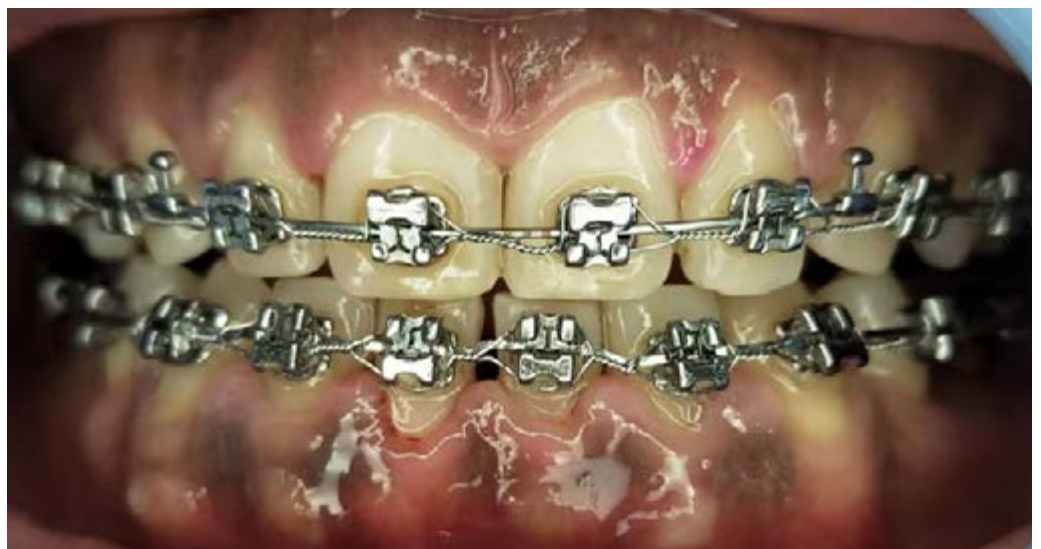BEFORE GBT



**AFTER
DISCLOSING**



AFTER GBT



PERIODONTAL DEBRIDEMENT

CASE 83



CLINICIAN

Karen NG
Dental hygienist
Canada

PATIENT INFORMATION

- ▶ Age 28, Male.

BACKGROUND INFORMATION

- ▶ Chronic moderate cigarette/marijuana smoker. Client not ready for smoking cessation program. Microbiological biofilm DNA testing was completed and key pathogens were identified in the oral cavity.

CLINICAL FINDINGS

- ▶ Generalized gingival inflammation with moderate subgingival calculus; cariogenic biofilm present around the anterior teeth; interdental CAL 3-4mm ; probing depths 5mm or less; generalized horizontal bone loss; generalized bleeding on probing; Unstable, localized stage II, grade B.

TREATMENT

- ▶ GBT treatment protocol completed with AIRFLOW® PLUS Powder, PERIOFLOW® and PIEZON® PS, PSR & PSL Instruments to access the crowded and difficult areas. Educated the patient and instructions were given for home management. Patient very motivated to attend the 3-month maintenance care visits because of GBT.

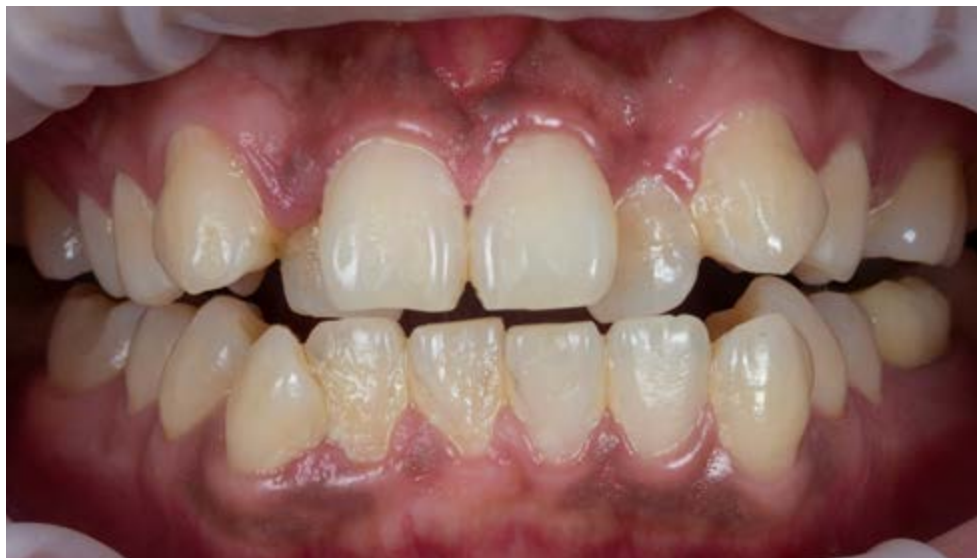PATIENT FEEDBACK

“I HAVE STRUGGLED FOR MANY YEARS TRYING TO MAINTAIN MY DENTAL HEALTH. I REALLY APPRECIATE THE THOROUGH AND COMFORTABLE CARE THAT I RECEIVE WITH THIS TREATMENT. MY TEETH FEEL INCREDIBLY SMOOTH, AND MY GUMS FEEL REJUVENATED AFTER EACH VISIT!”

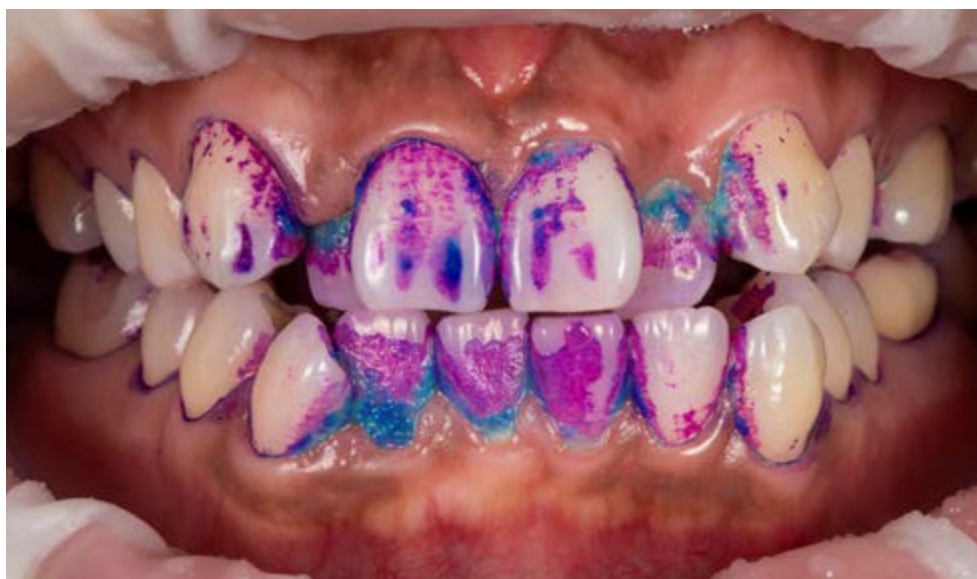& GBT



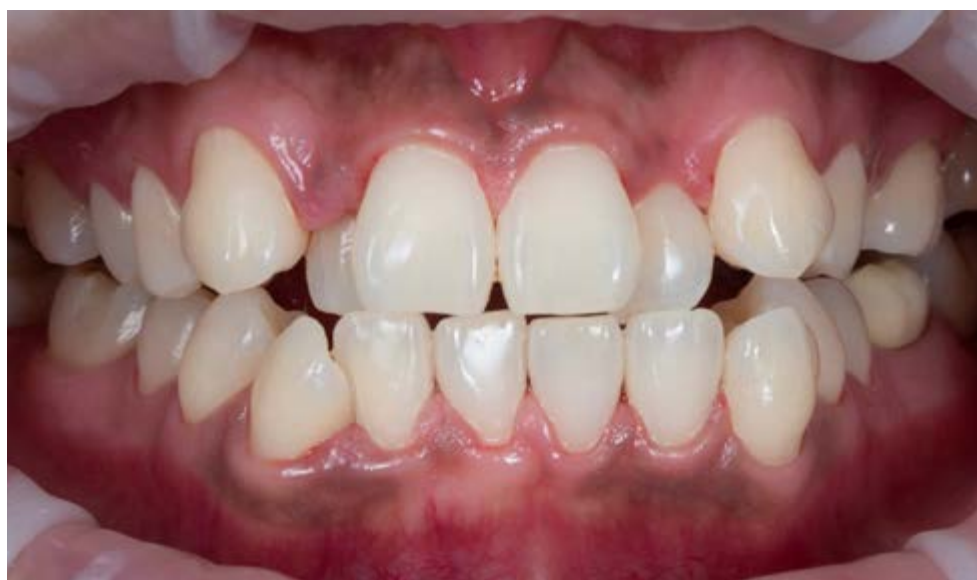BEFORE GBT



**AFTER
DISCLOSING**



AFTER GBT



PERIODONTAL DEBRIDEMENT

CASE 84



CLINICIAN

Marija Scheffler
Dental hygienist
Germany

PATIENT INFORMATION

- ▶ Age 87, female.

BACKGROUND INFORMATION

- ▶ Very motivated patient, determined to save her teeth, She suffered a lot due to periodontal disease and lost teeth. No systemic disease.

CLINICAL FINDINGS

- ▶ Deep pockets in many teeth, BOP +, good oral hygiene.

TREATMENT

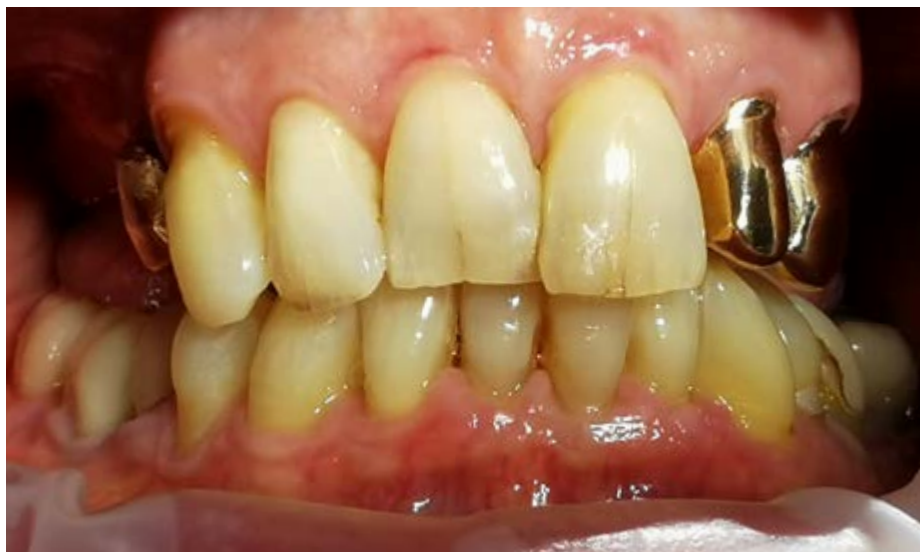- ▶ GBT with AIRFLOW® PLUS Powder and PIEZON® PS Instrument. PERIOFLOW® nozzle used with AIRFLOW® PLUS Powder on a few teeth. Fluoride applied to teeth after GBT. Recalled every 4 months.

PATIENT FEEDBACK

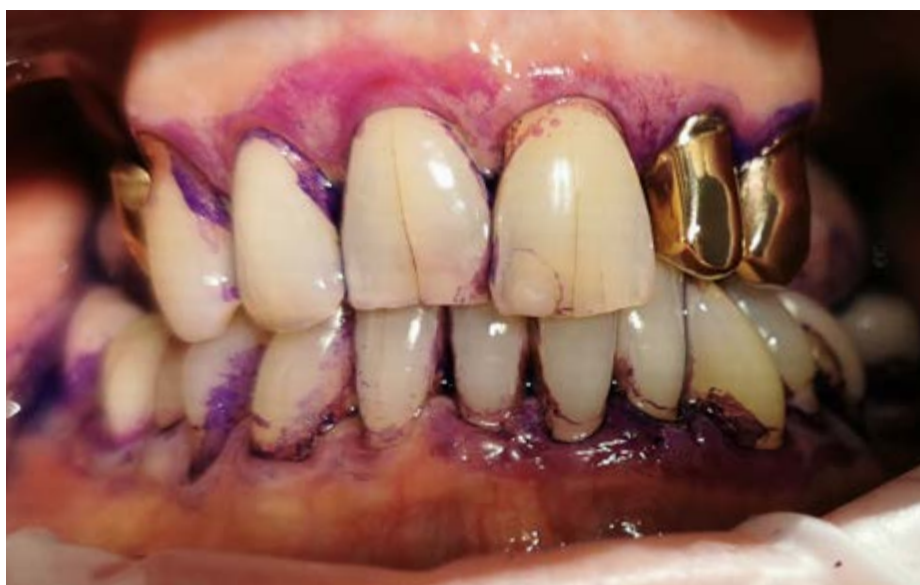“THANK YOU FOR SAVING MY TEETH!”

& GBT

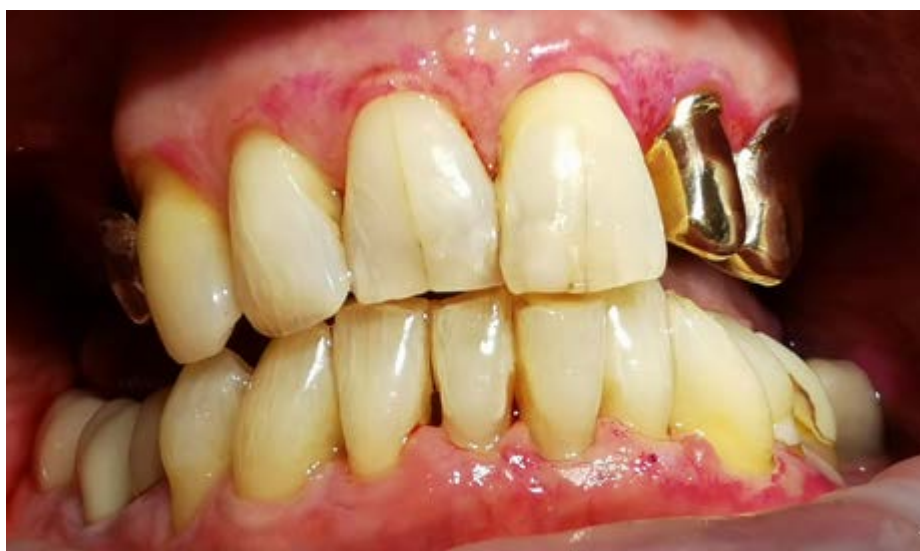BEFORE GBT



**AFTER
DISCLOSING**



AFTER GBT



PERIODONTAL DEBRIDEMENT

CASE 85



CLINICIAN

Meredith Gantos
Dental hygienist
United States

PATIENT INFORMATION

- ▶ Age 65, male.

BACKGROUND INFORMATION

- ▶ Patient is on a 4-month recall due to generalized moderate staining. Habit of clenching and grinding.

CLINICAL FINDINGS

- ▶ Patient was diagnosed with generalized stage III, grade B periodontal disease. Probing depths range from 1-6mm with localized bleeding points in the posterior. 17% of teeth have a 6mm probing depth. 82% of teeth have recessive defects. Generalized moderate plaque and staining with localized mild calculus present on the lower anteriors.

TREATMENT

- ▶ Patient was disclosed with GC Tri Plaque ID Gel which reveals various colors based on the pathogenicity of the plaque. A pink color indicates fresh plaque, a blue or purple color indicates mature plaque, and a light blue color indicates mature plaque that is strongly acid producing. After educating the patient and reviewing oral hygiene instructions, the AIRFLOW® was used to remove the biofilm on teeth, tongue, and soft tissues. Special care and attention to light blue and purple areas to ensure complete debridement. The 11/12 explorer was used to check all surfaces for complete debridement.

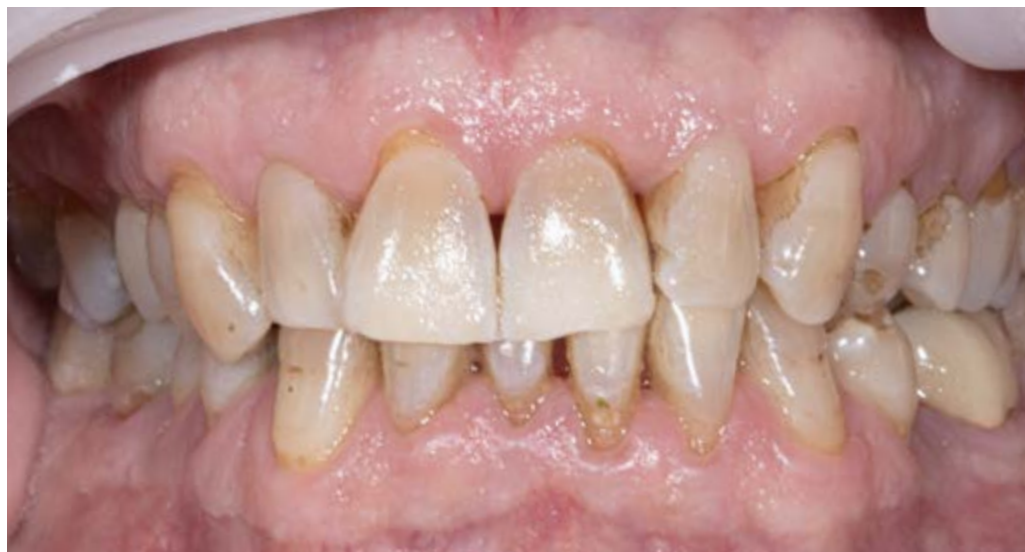PATIENT FEEDBACK

“I’M HAPPY WITH THE RESULT!”

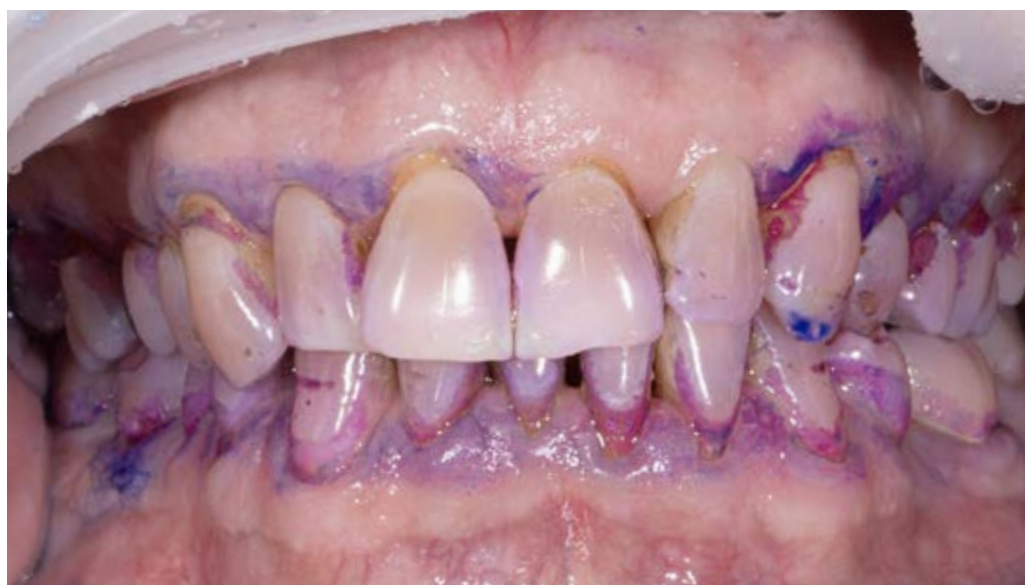& GBT



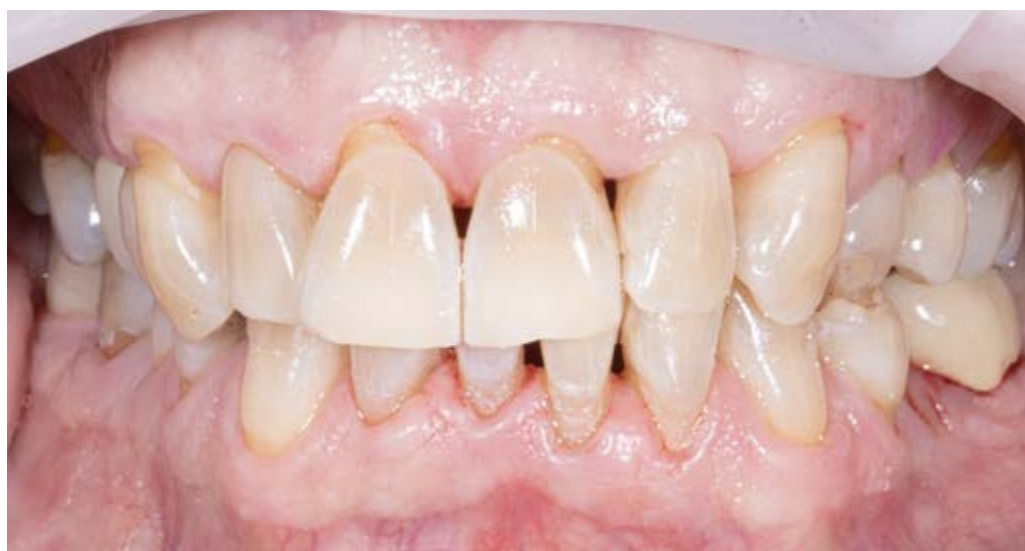BEFORE GBT



AFTER DISCLOSING



AFTER GBT



PERIODONTAL DEBRIDEMENT

CASE 86



CLINICIAN

Adina Mauder
Dental hygienist
Germany

PATIENT INFORMATION

► Age 45, female.

BACKGROUND INFORMATION

► No existing diseases, no medication. Smoker. Last treatment 3 months ago. Uses manual toothbrush and floss sometimes.

CLINICAL FINDINGS

► Defects seen around the cervical areas of the tooth, bleeding gums, oral habits, clenching and grinding, redness, occasional swelling, calculus present on all teeth, severe staining on all teeth, periodontal disease diagnosed.

TREATMENT

► GBT done the usual way with AIRFLOW® MAX and PLUS Powder. Calculus was removed using PIEZON® PS supra- and subgingivally. After 2 months, BOP reduced drastically. Patient had better oral hygiene and was motivated.

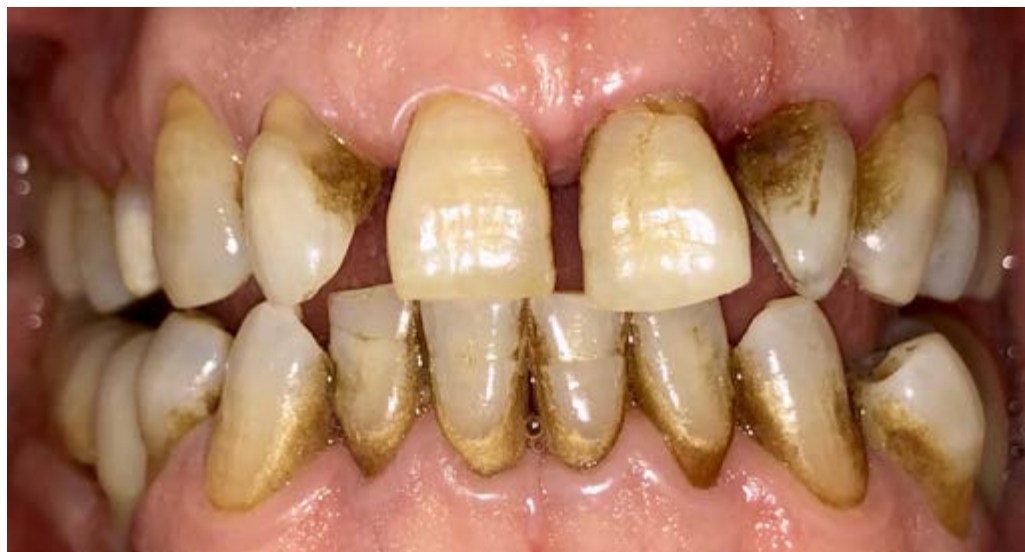PATIENT FEEDBACK

“I FEEL GOOD. MY TEETH ARE SAVED.”

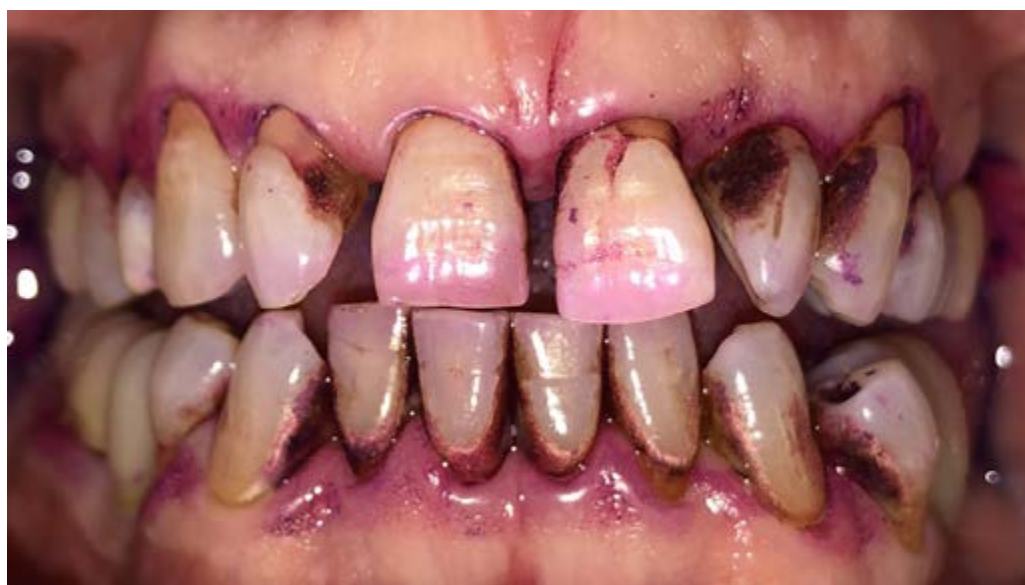& GBT



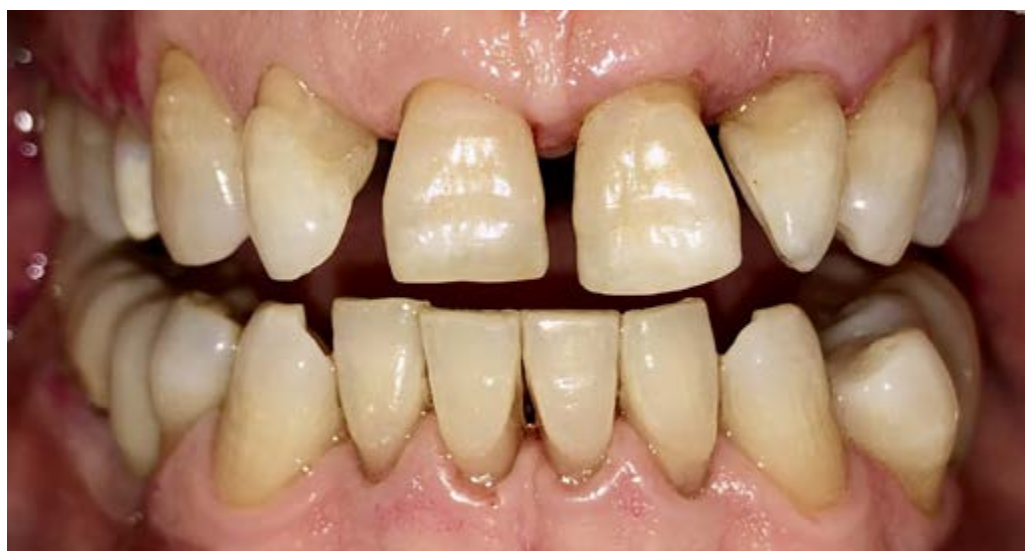BEFORE GBT



AFTER DISCLOSING



AFTER GBT



PERIODONTAL DEBRIDEMENT

CASE 87



CLINICIAN

Beatriz Rosell
Periodontist
Spain

PATIENT INFORMATION

- ▶ Age 42, female.

BACKGROUND INFORMATION

- ▶ She reports that her last prophylaxis was 6 months ago. Throughout her life she has undergone prophylaxis with curettes. Poor oral hygiene. No diseases, no medication currently. Smokes 20 cigarettes a day.

CLINICAL FINDINGS

- ▶ Gingivitis. BOP +, pocket probing depth (PPD) 3mm or less. Several recessions. Widespread presence of calculus supra- and subgingival, mature biofilm and stains. Enamel hypoplasia in upper incisors. Large enamel erosions produced in previous treatments with curettes.

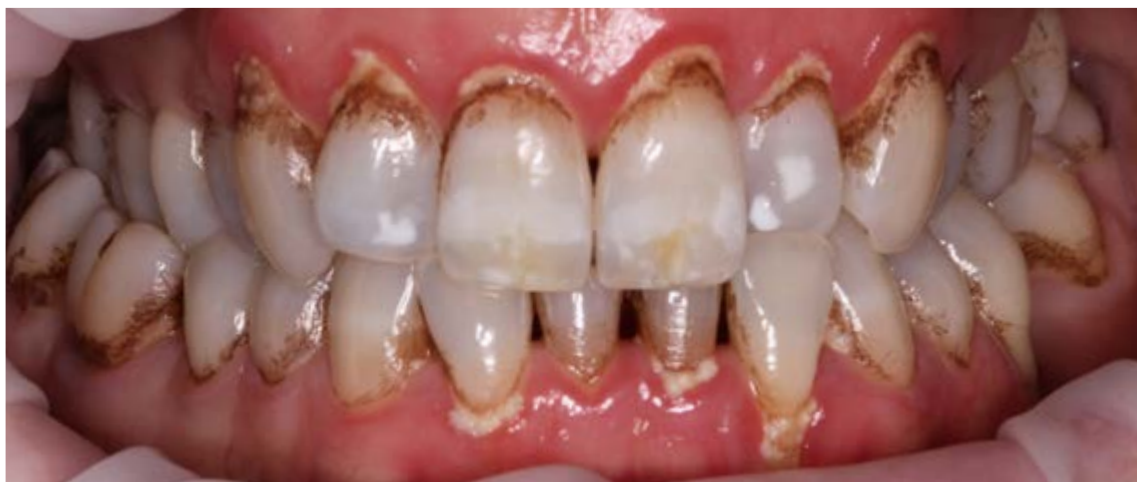TREATMENT

- ▶ The treatment starts with BacterX-Pro prerinse. Once the assessment has been done, one of the most important parts is disclosing and showing the patient her shortcomings, educate in oral hygiene techniques and motivate her to put these techniques into practice. GBT was performed with AIRFLOW® MAX, using only PLUS Powder which is harmless to damaged enamel and has removed completely biofilm and stains. Subsequently PIEZON® PS Instrument. Patient recall every 6 months. Smoking cessation advised.

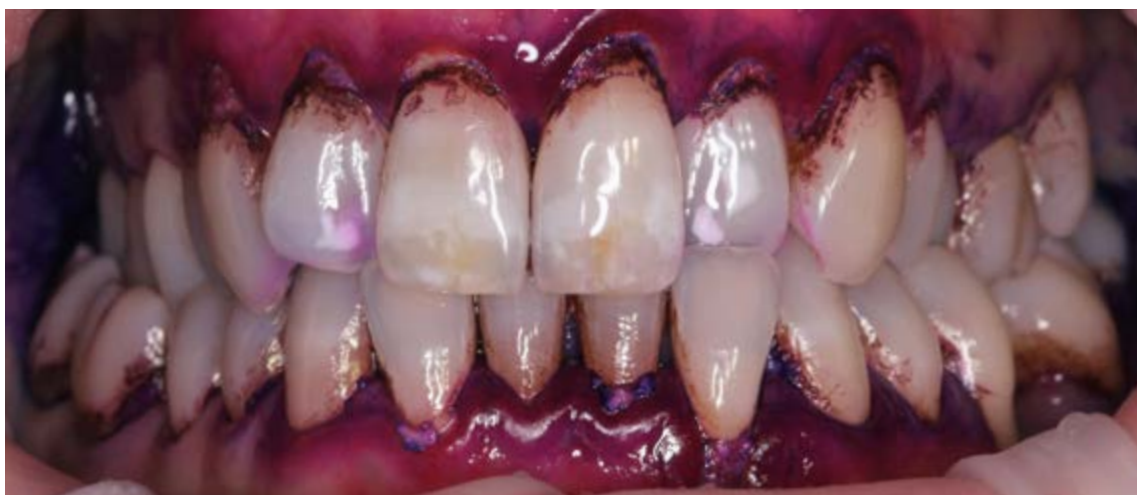PATIENT FEEDBACK

“IT’S THE FIRST TIME I HAVE FELT MY MOUTH SO CLEAN, WITHOUT USING INSTRUMENTS THAT SCRATCH AND SQUEAK AGAINST MY TEETH.”

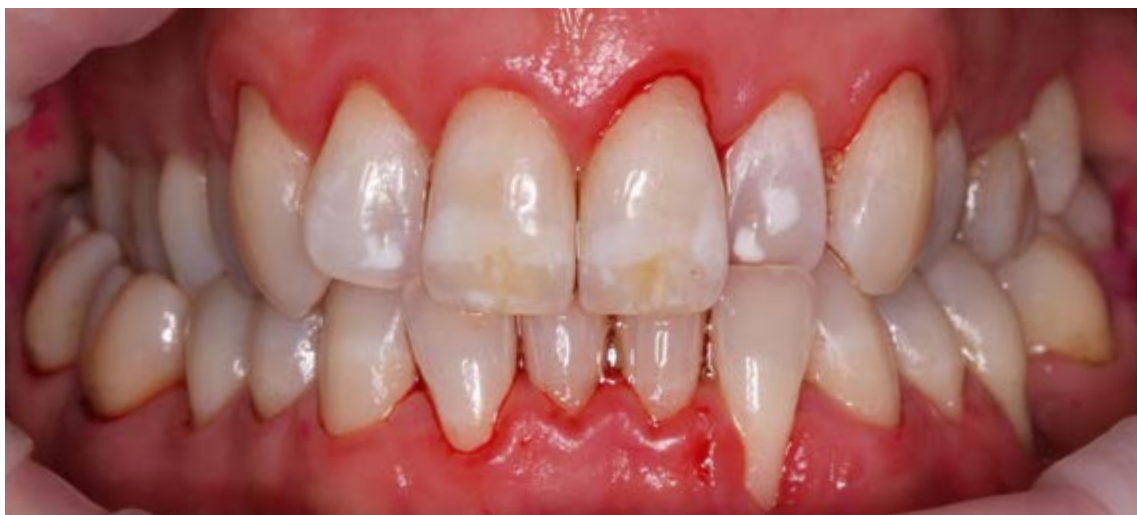BEFORE GBT



AFTER DISCLOSING



AFTER GBT



PERIODONTAL DEBRIDEMENT

CASE 88



CLINICIAN

Bibiána Dugasová
Dental hygienist
Slovakia

PATIENT INFORMATION

- ▶ Age 26, male.

BACKGROUND INFORMATION

- ▶ The patient had visited another dental clinic in the past, but the treatment was sensitive and painful for him. The last treatment was about 3 years ago, due to fear. He is also bothered by the color of his teeth. (B4 on the VITA Classical scale). No relevant habits.

CLINICAL FINDINGS

- ▶ On teeth, after detection, visible mature plaque. Predominantly on the frontal sections of the teeth, the distal sections were covered with plaque minimally, only in the interdental space and the cervical area. The reason for the plaque on the frontal sections indicates a minor injury from a few days ago on a bicycle. He had pain in this area, he skipped this place when brushing his teeth.

TREATMENT

- ▶ Complete GBT protocol with AIRFLOW® PLUS Powder, PIEZON® PS Instrument, with focus on patient motivation and education. We focused on cleaning the cervical area and interdental spaces at home and set up a regular recall after the first visit for 3 months and then every six months.

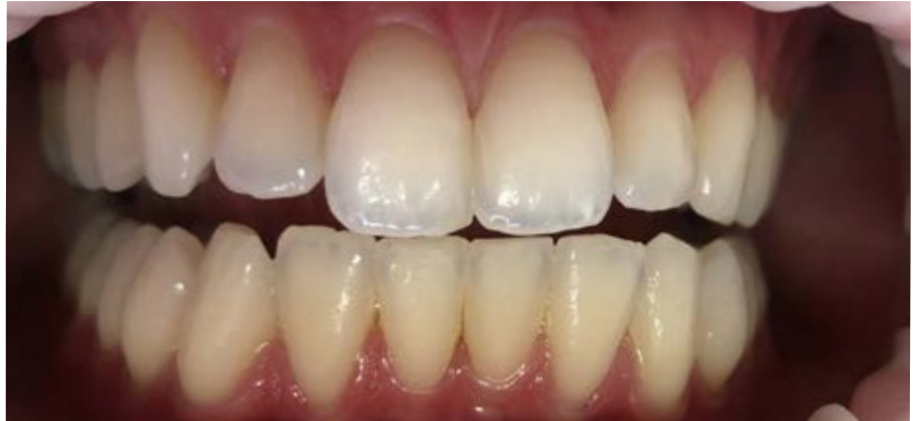PATIENT FEEDBACK

“LOVE IT, GBT IS A REAL GAME CHANGER!”

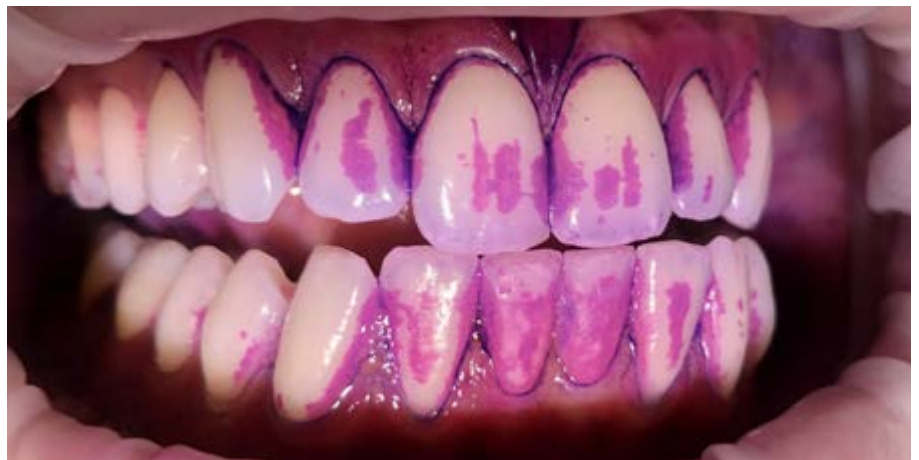& GBT



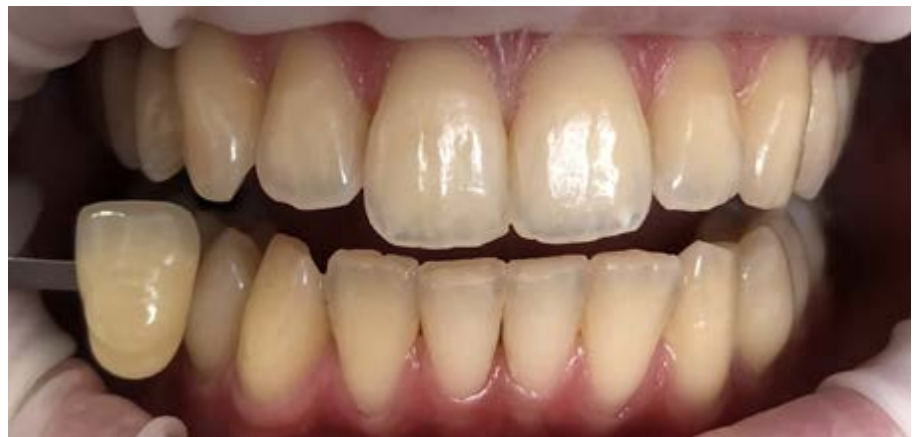BEFORE GBT



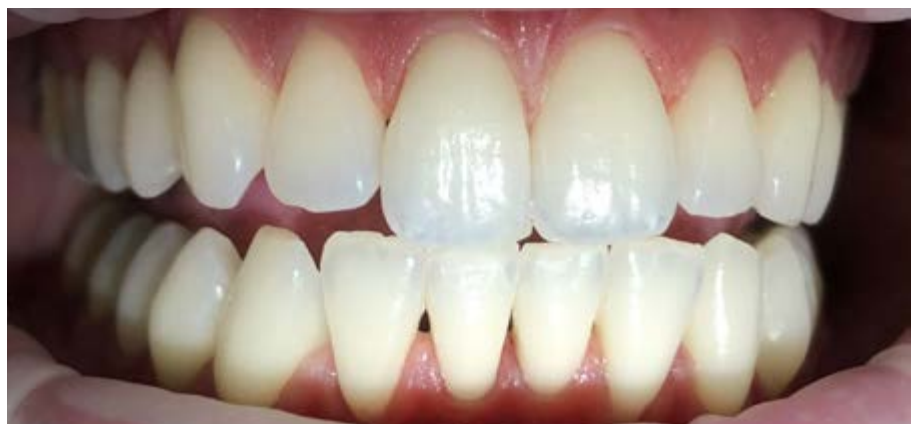AFTER DISCLOSING



AFTER GBT



AFTER BLEACHING



PERIODONTAL DEBRIDEMENT

CASE 89



CLINICIAN

Binta Visser
Dental hygienist
Germany

PATIENT INFORMATION

- ▶ Age 42, male.

BACKGROUND INFORMATION

- ▶ Poor oral hygiene. Last professional cleaning more than 2 years ago. Smokes 5 cigarettes a day.

CLINICAL FINDINGS

- ▶ Heavy tenacious supra- and subgingival calculus with generalized 4 mm pockets, localized 5/6mm pockets . BOP + Gum is ready to heal after Guided Biofilm Therapy treatment. Post GBT (3 weeks) later - no inflammation of the gum = irritation, redness and swelling. Partial BOP + in pockets > 5mm, Patient shows a good compliance in oral hygiene, beginning of periodontal treatment.

TREATMENT

- ▶ Started by disclosing the biofilm with the Biofilm Disclosure to make the biofilm visible, then used the AIRFLOW® PLUS Powder in combination with the AIRFLOW® MAX handpiece to easily and safely remove biofilm and early calculus from coronal surfaces. Subgingival biofilm was removed from deeper periodontal pockets of more than 4mm. PIEZON® PS Instrument was used to remove calculus in a minimally invasive way.

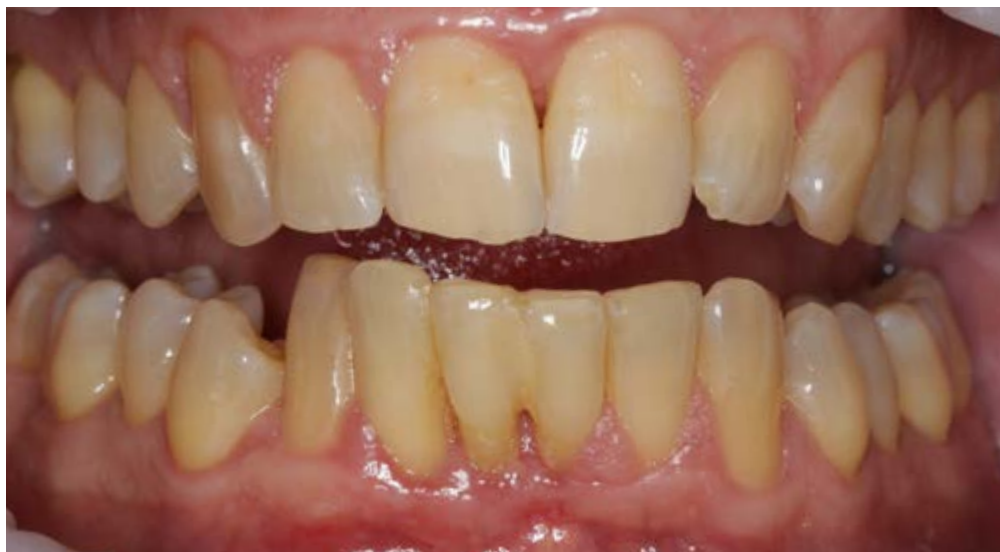PATIENT FEEDBACK

“I FEEL MOTIVATED TO MAINTAIN THE RESULT BY TAKING CARE OF MY TEETH AT HOME AND I WILL TRY MY BEST THAT WE WILL BOTH SEE LESS OF THE BLUE/PURPLE COLOR NEXT TIME.”

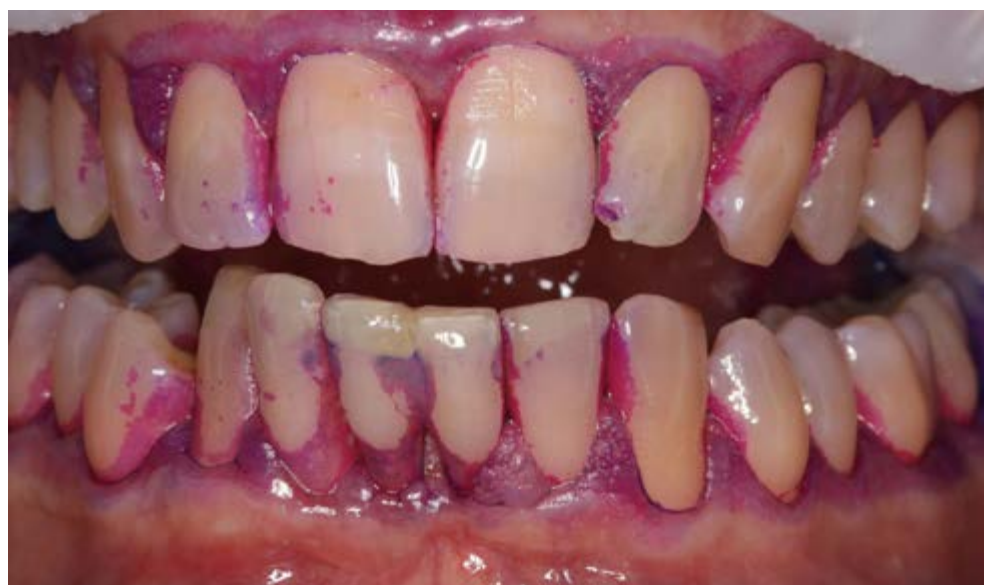& GBT



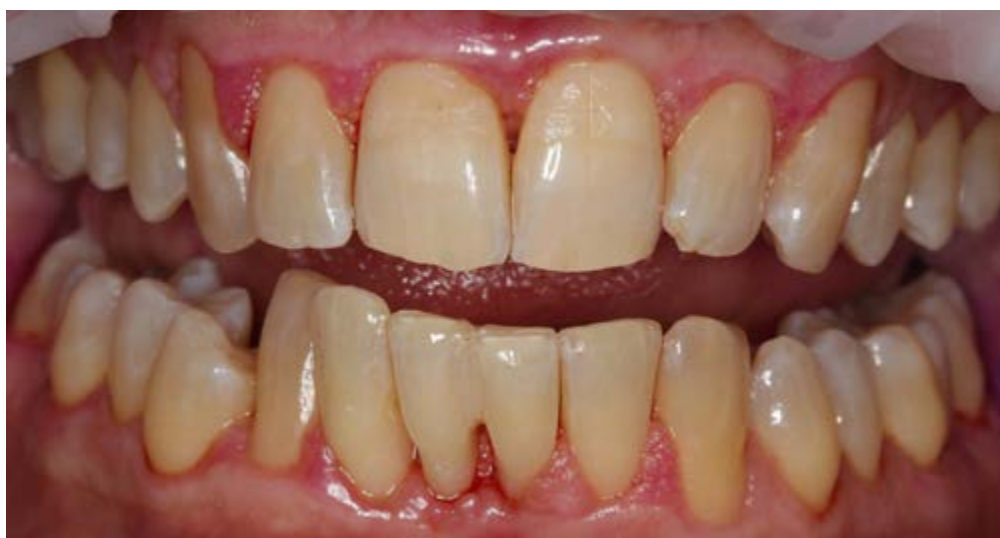BEFORE GBT



AFTER DISCLOSING



AFTER GBT



PERIODONTAL DEBRIDEMENT

CASE 90



CLINICIAN

Bülent Kurtis
Dentist
Turkey

PATIENT INFORMATION

- ▶ Age 36, male.

BACKGROUND INFORMATION

- ▶ Dense biofilm formation, gingival inflammation and ulcerations around interdental papillae. No relevant habits.

CLINICAL FINDINGS

- ▶ Generalized gingival inflammation especially around left upper and lower incisors and canine teeth and apparent poor oral hygiene. Clinically painful, spontaneously bleeding gums, and ulceration of interdental papillae defines and characterizes acute necrotizing ulcerative gingivitis (ANUG). Predisposing factors were poor oral hygiene and psychological stress.

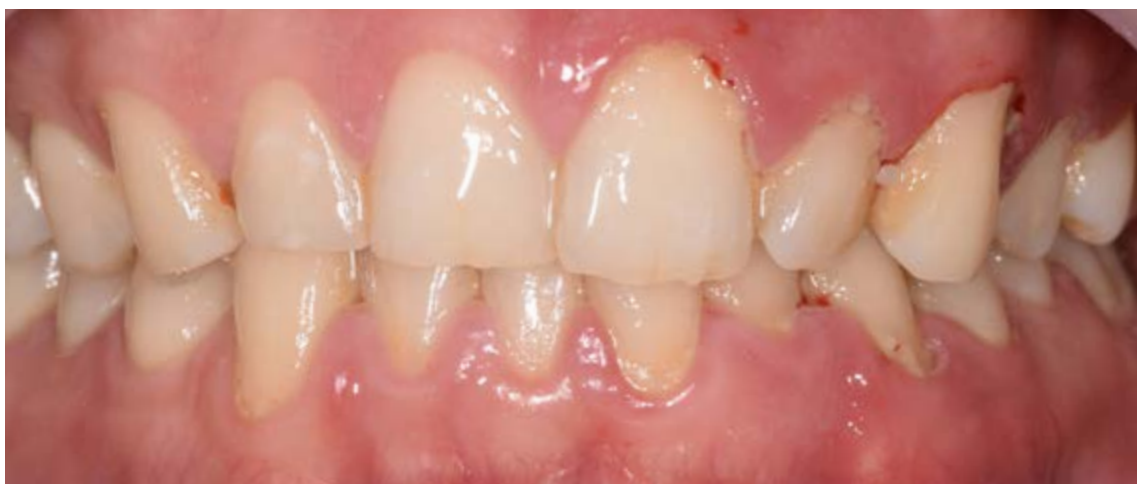TREATMENT

- ▶ Following the clinical and radiographical examinations, biofilm disclosing and oral hygiene motivation were done and AIRFLOW® PLUS Powder with AIRFLOW® Handpiece was used to remove soft disclosed deposits and all biofilm around teeth according to the sequence of Guided Biofilm Therapy (GBT). PIEZON® PS Instrument was used to remove hard deposits (calculus). In addition to GBT, prescription of antibiotic therapy (metronidazole 500mg/daily 3 times) for 7 days was given. Control session was done at first month and biofilm disclosed again.

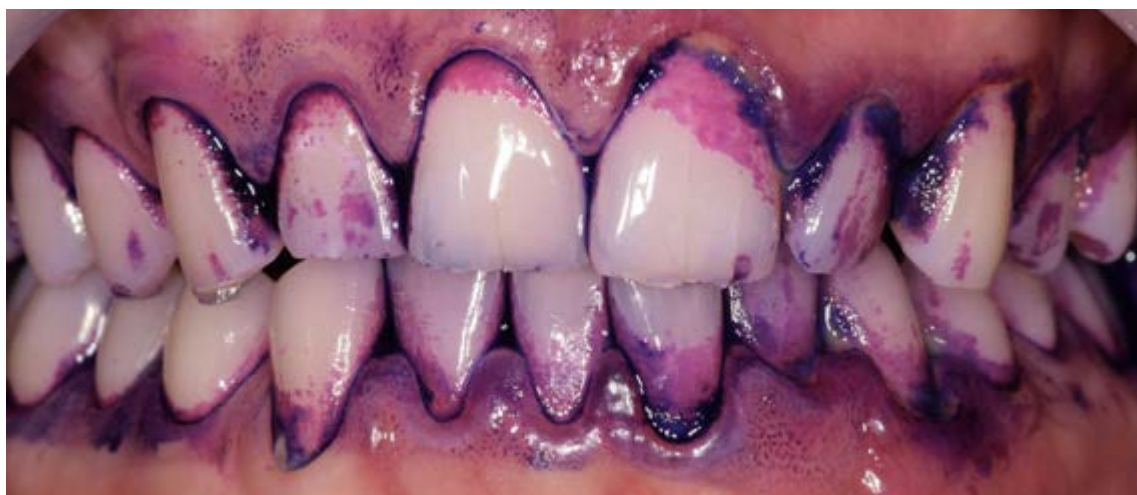PATIENT FEEDBACK

**“GBT TREATMENT WAS VERY GENTLE, COMFORTABLE AND SATISFYING.
I EXTREMELY APPRECIATE THIS NEW TREATMENT METHOD.”**

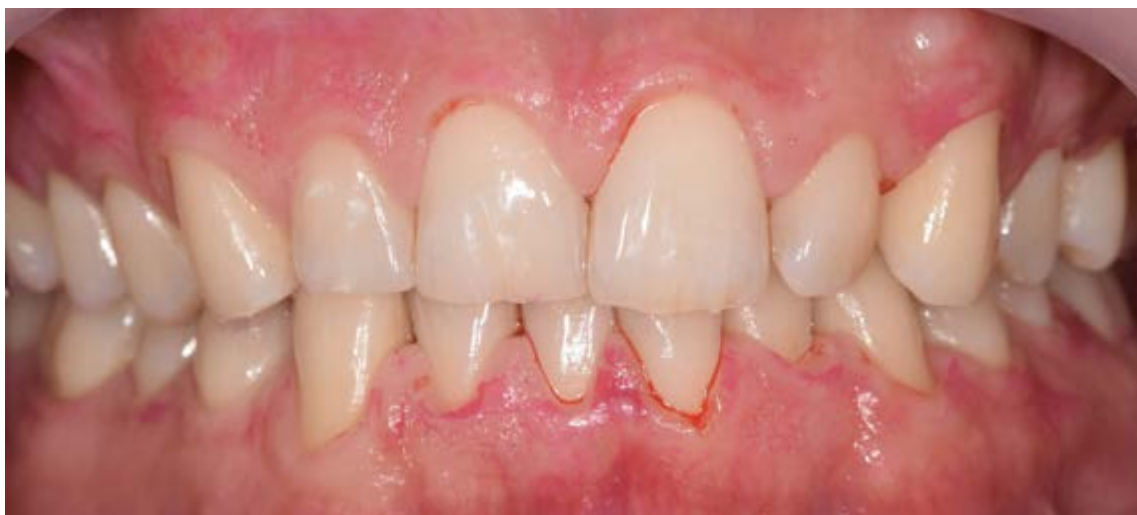BEFORE GBT



AFTER DISCLOSING



AFTER GBT



PERIODONTAL DEBRIDEMENT

CASE 91



CLINICIAN

Esther Rovira
Dental hygienist
Spain

PATIENT INFORMATION

- ▶ Age 48, male.

BACKGROUND INFORMATION

- ▶ The patient follows a Mediterranean diet. He uses only electric toothbrush once a day for less than two minutes. He doesn't use interdental sticks and never has used a tongue scraper. Non-smoker, poor oral hygiene. Improper and inadequate oral home care.

CLINICAL FINDINGS

- ▶ Some pockets present, all less than 5mm, BOP + in almost all gingival areas, supragingival, subgingival and interdental calculus present. Some stains and visible biofilm present. Agenesis of 12 and 22. He has dental implants in position 21, 25 and 26.

TREATMENT

- ▶ GBT protocol completed with emphasis on disclosing agent and oral hygiene instructions (electric toothbrush, interdental sticks - Easy-picks by TePe and tongue scraper by Halita, Dentaïd). AIRFLOW® with PLUS Powder to remove the biofilm and stains. PIEZON® PS Instrument and PSL-PSR Instruments to remove supragingival, subgingival and interdental calculus.

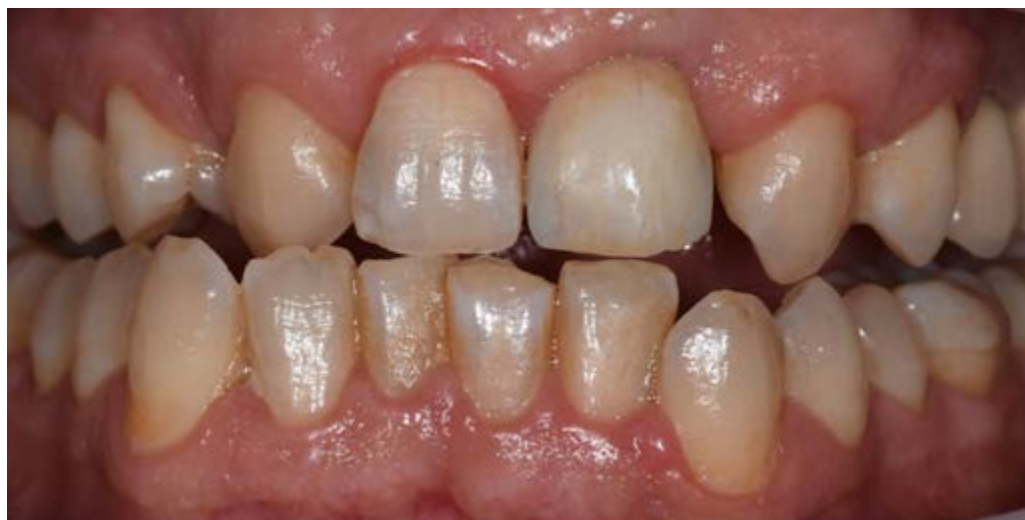PATIENT FEEDBACK

“I FELL ASLEEP DURING THE TREATMENT. IT’S INCREDIBLE! IT WAS UNBELIEVABLY RELAXED AND COMFORTABLE. THANK YOU FOR CONNECTING ME WITH MY DENTAL HEALTH. I FEEL REALLY GOOD!!”

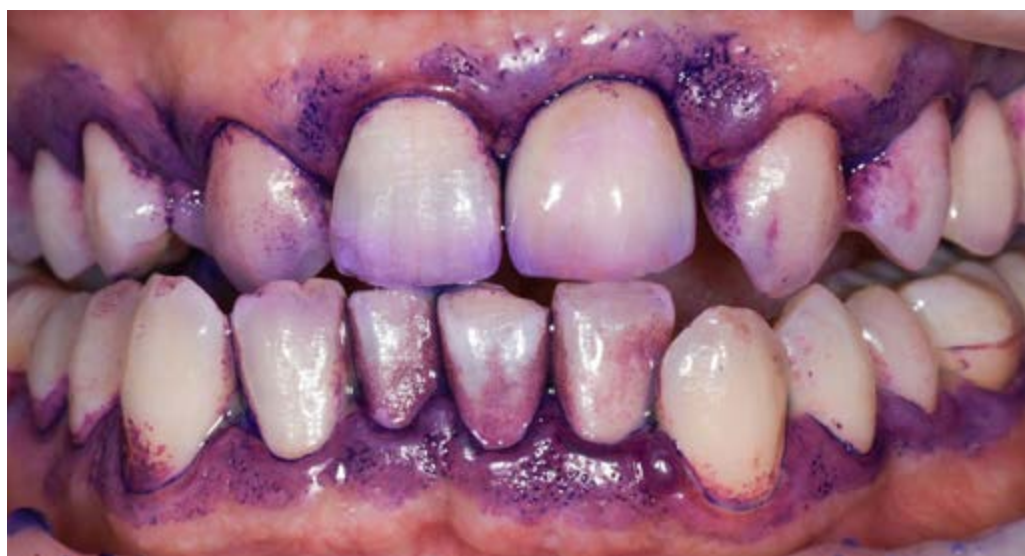& GBT



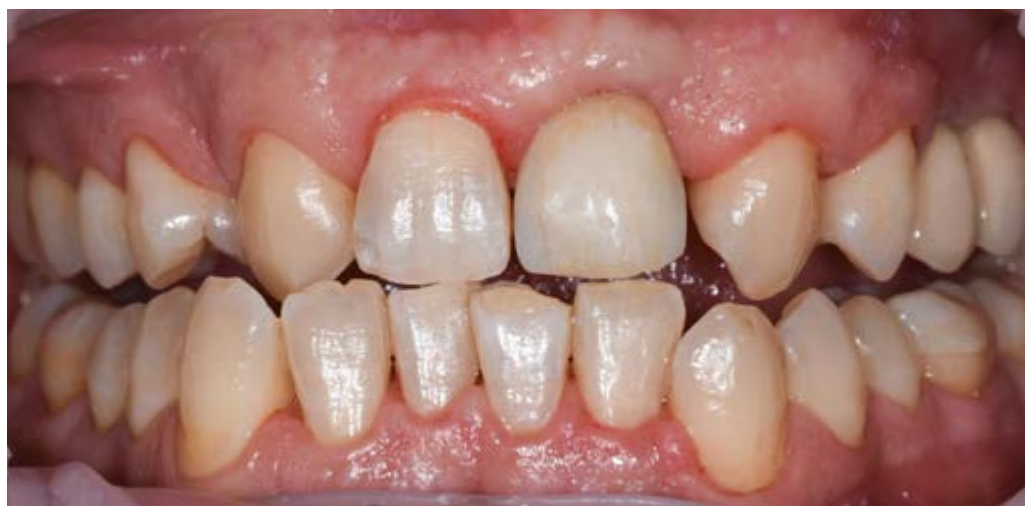BEFORE GBT



AFTER DISCLOSING



AFTER GBT



PERIODONTAL DEBRIDEMENT

CASE 92



CLINICIAN

Kim Eunae
Dental hygienist
South Korea

PATIENT INFORMATION

- ▶ Age 47, male.

BACKGROUND INFORMATION

- ▶ Severe periodontitis around molars in 2018. Especially maxilla molars needed to be extracted for implant placement.

CLINICAL FINDINGS

- ▶ Due to severe bone resorption in the maxillary molars, implant treatment was planned after extraction. Periodontal treatment was required for generalized periodontitis.

TREATMENT

- ▶ After implant treatment and no surgical periodontal therapy in 2018, the patient has participated in continuous maintenance through the GBT program since 2020. Through GBT program every three months for a year, his self-management habits have dramatically improved. Currently, he is maintaining a healthy oral condition by receiving a recall and GBT program every 6 months.

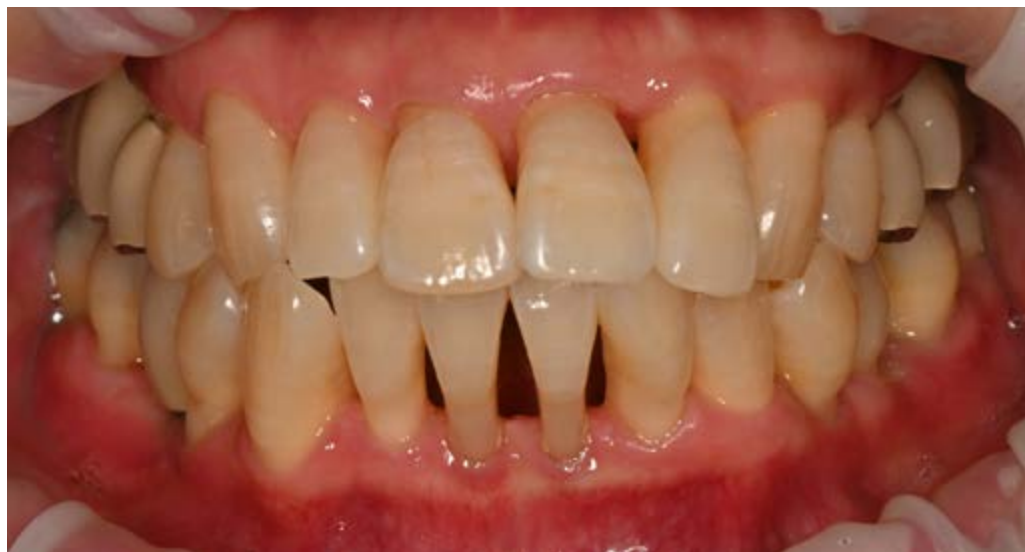PATIENT FEEDBACK

**“I DON’T WANT TO GO BACK TO WHERE I WAS BEFORE.
I WANT TO KEEP COMING BACK FOR GBT.”**

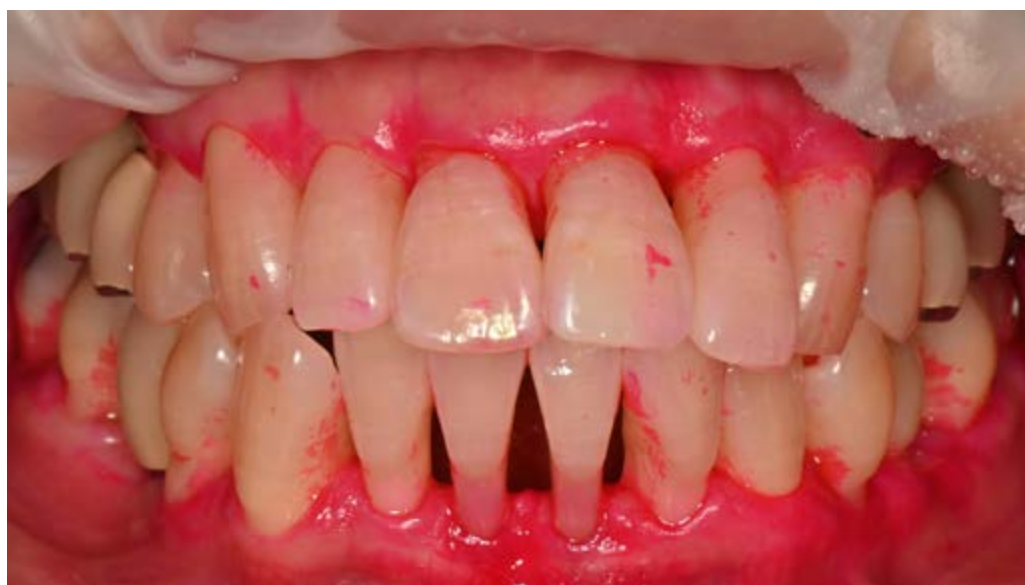& GBT



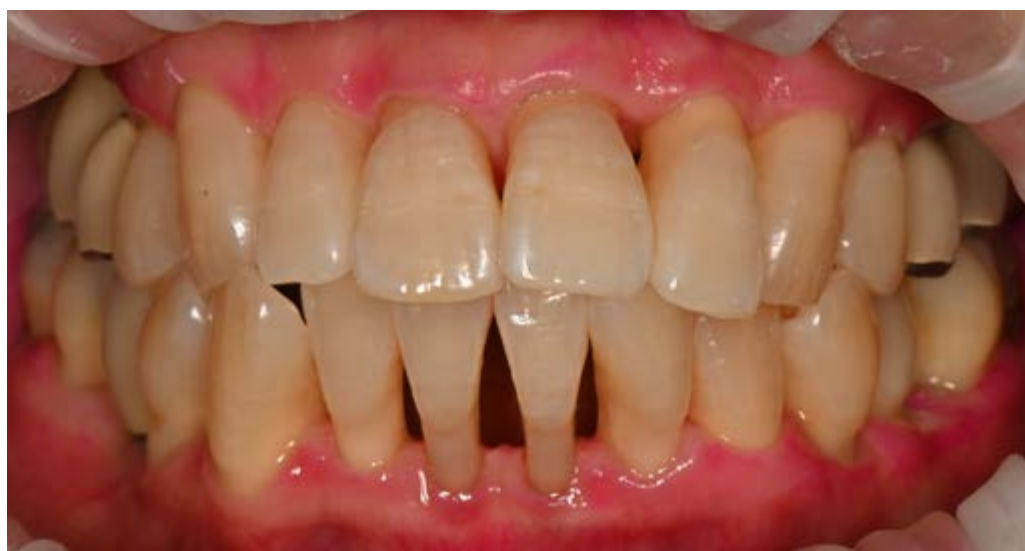BEFORE GBT



AFTER DISCLOSING



AFTER GBT



PERIODONTAL DEBRIDEMENT

CASE 93



CLINICIAN

Abdalla Hanan
Dental hygienist
UAE

PATIENT INFORMATION

- ▶ Age 38, female.

BACKGROUND INFORMATION

- ▶ Diet: Variety of food/high refined sugar and carbohydrate intake, regular away-from-home dining. Poor oral hygiene: brushing once a day with manual toothbrush and no flossing. High level of patient motivation. Healthy and non-smoker.

CLINICAL FINDINGS

- ▶ Gingiva: inflamed, marginal redness, bleeding gum and heavy plaque. Acute gingivitis plaque induced. Generalized chronic periodontitis.

TREATMENT

- ▶ Complete GBT protocol with AIRFLOW® PLUS Powder, PIEZON® PS Instrument.

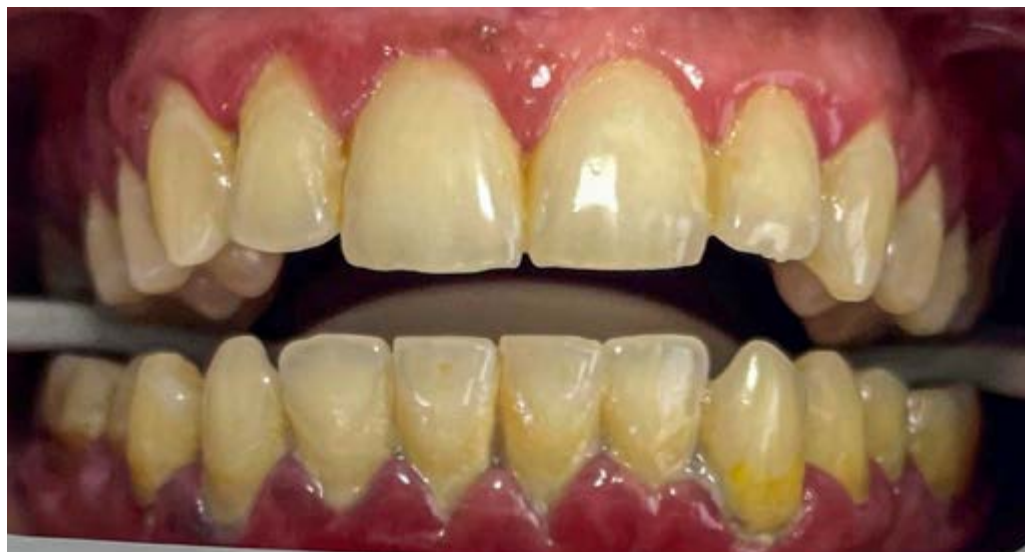PATIENT FEEDBACK

“I HAVE COMPLAINED ABOUT GUM BLEEDING FOR MANY YEARS AND VISITED MANY DENTISTS WITH PAINFUL TREATMENT WITH NO SOLUTION, I REACHED THE POINT WHERE I ACCEPTED MY GUMS WILL ALWAYS BLEED. NOW AFTER THE GBT TREATMENT I AM REALLY HAPPY BECAUSE MY GUMS HAVE HEALED AND THEY LOOK AND FEEL SO HEALTHY.”

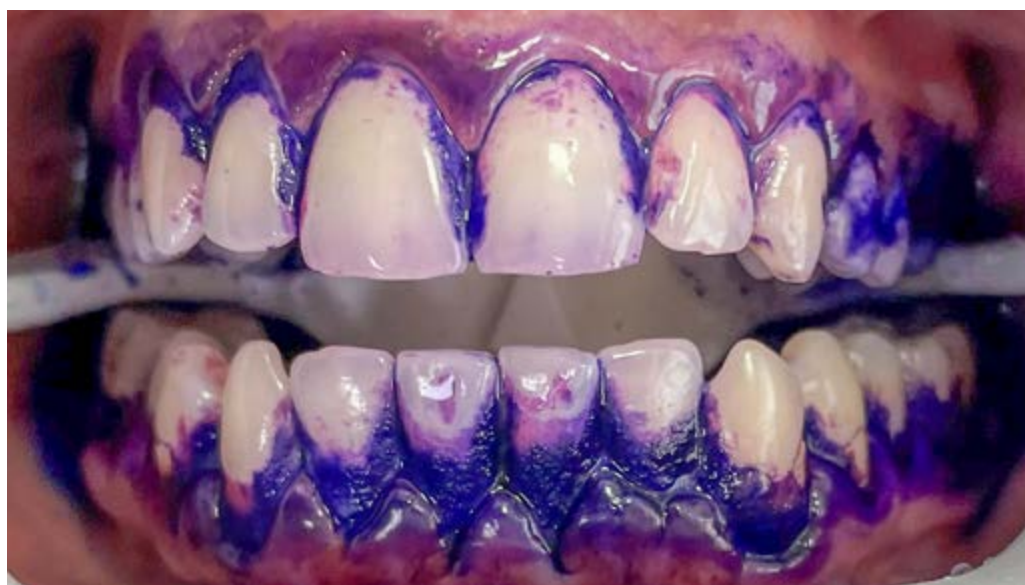& GBT



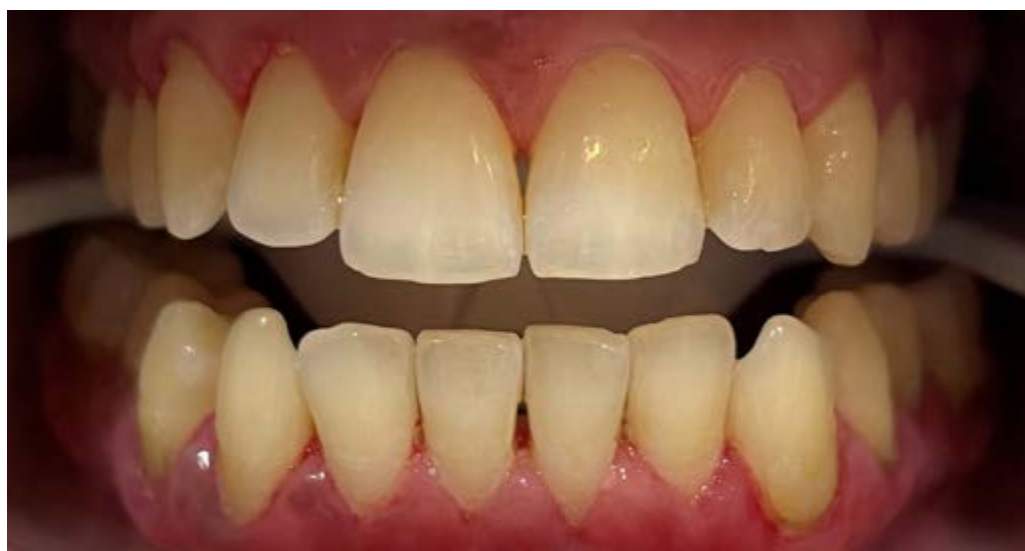BEFORE GBT



**AFTER
DISCLOSING**



**3-MONTH
RECALL**



PERIODONTAL DEBRIDEMENT

CASE 94



CLINICIAN

Ivona Bondorová
Dental hygienist
Slovakia

PATIENT INFORMATION

- ▶ Age 41, female.

BACKGROUND INFORMATION

- ▶ Dental phobia. There was no visit to the dentist or dental hygienist for 10 years. Very poor oral hygiene.

CLINICAL FINDINGS

- ▶ Presence of supra- and subgingival calculus. Periodontal pockets 4-6mm. BOP ++++. Caries. Halitosis present. Gingival pain.

TREATMENT

- ▶ Followed GBT protocol. Biofilm removal with AIRFLOW® PLUS Powder. Supra- and subgingival calculus removal using PIEZON® PS Instrument. Use of chlorhexidine gel 0,2% was prescribed for the next 2 weeks. First recall after 1 month demonstrated patient compliance, as there has been an overall improvement in patient care.

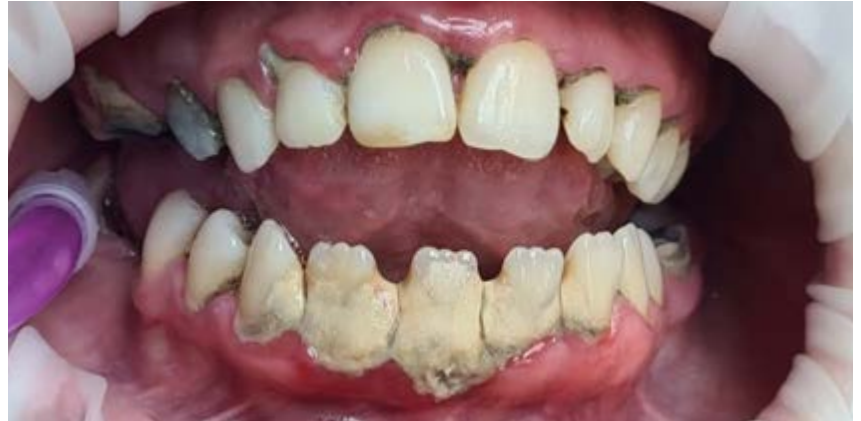PATIENT FEEDBACK

“I FEEL VERY ASHAMED. YOU ARE PERFECT AND YOU HAVE GOLDEN HANDS. WELL, THANK YOU! EVERY TIME I LOOKED IN THE PAST AT PHOTO ADVERTISING FOR DENTAL HYGIENE, I THOUGHT IT WAS A PHOTOMONTAGE. NOW I AM VERY HAPPY!”

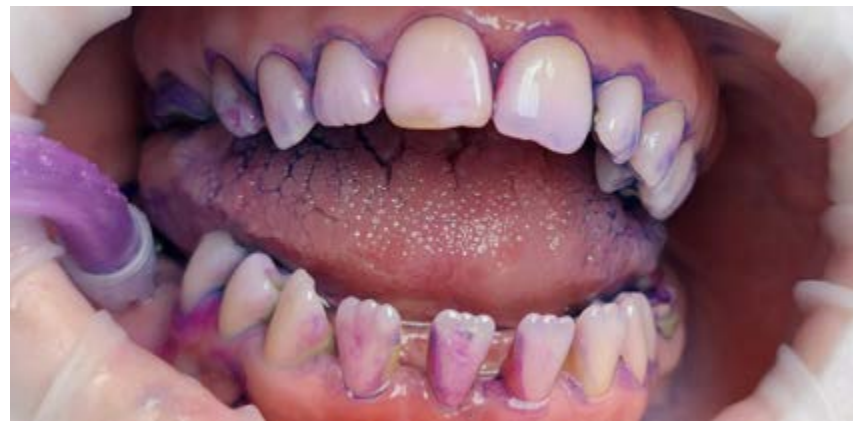& GBT



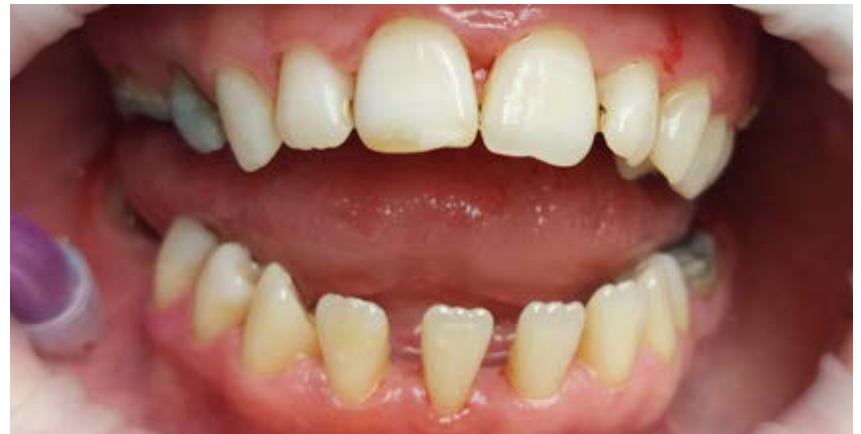BEFORE GBT



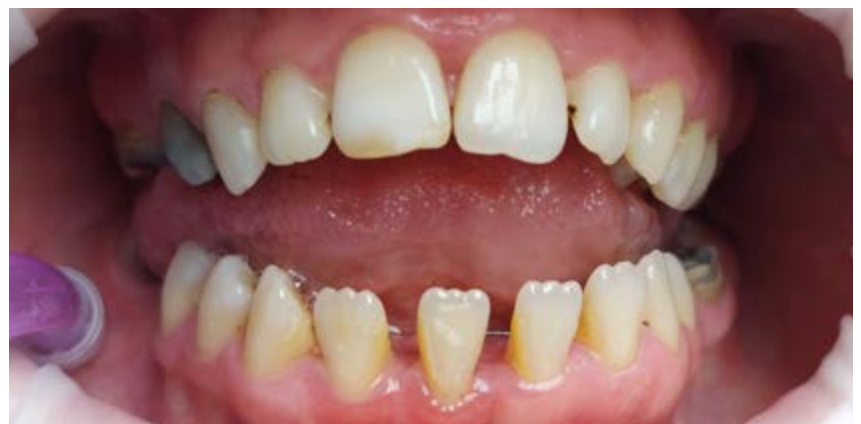AFTER DISCLOSING



AFTER GBT



AFTER 1 MONTH



PERIODONTAL DEBRIDEMENT

CASE 95



CLINICIAN

Khanda Yousef
Dental hygienist
Sweden

PATIENT INFORMATION

► Age 57, male.

BACKGROUND INFORMATION

► Patient thought he brushed his teeth properly until he received the GBT treatment. No relevant habits.

CLINICAL FINDINGS

► Periodontitis, bleeding on probing positive, presence of biofilm, calculus, deep periodontal pockets (between 5-8 mm).

TREATMENT

► GBT. I described to him how to brush his teeth properly. He has a regular recall every 6 months.

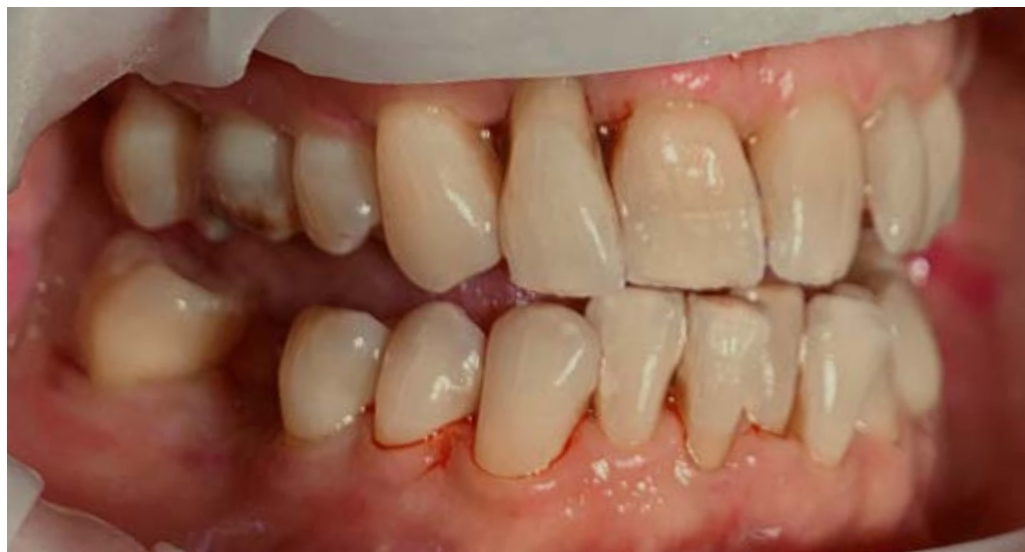PATIENT FEEDBACK

“I’M VERY SATISFIED WITH THE RESULTS. MY TEETH HAVEN’T BEEN THIS CLEAN FOR 20 YEARS. I WILL DEFINITELY FOLLOW YOUR ADVICE AND COME BACK FOR THIS TREATMENT. I WILL TELL MY FAMILY ABOUT YOU AND GBT SO THEY ALSO CAN EXPERIENCE THIS TREATMENT.”

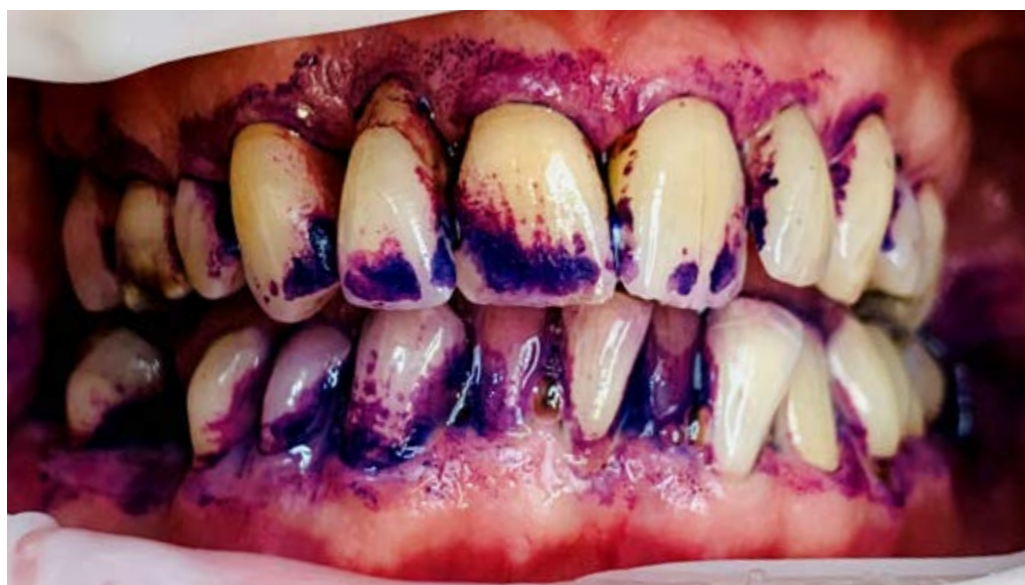& GBT



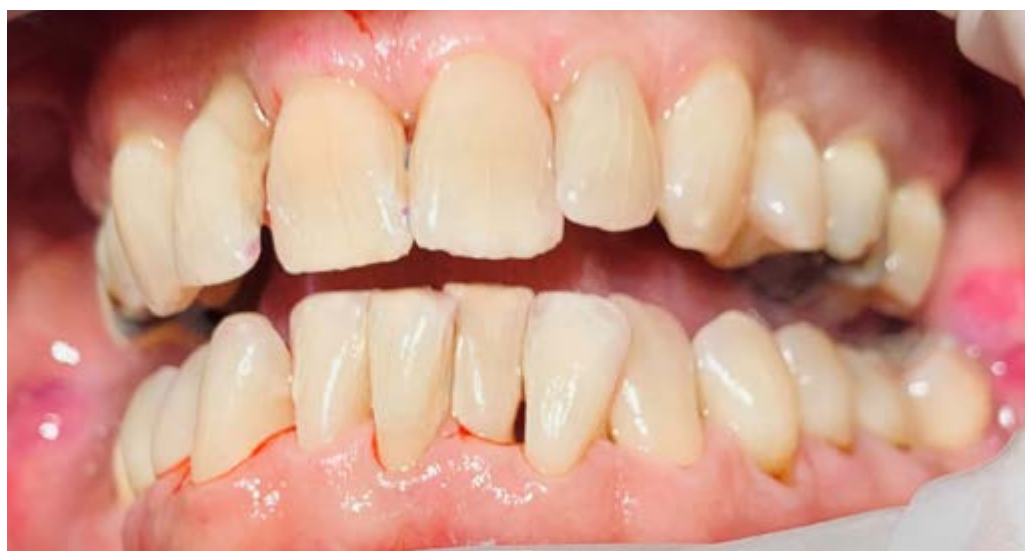BEFORE GBT



AFTER DISCLOSING



AFTER GBT



PERIODONTAL DEBRIDEMENT

CASE 96



CLINICIAN

Minjung Kim
Dental hygienist
South Korea

PATIENT INFORMATION

- ▶ Age 63, female.

BACKGROUND INFORMATION

- ▶ No medical history.

CLINICAL FINDINGS

- ▶ Need for improved anterior and lingual dental care. After taking interest in dental care, the patient began to pay more attention to mandibular anterior and improved self-care on lingual side. BOP- but with swollen gingiva. Presence of discomfort. Some interdental calculus present.

TREATMENT

- ▶ After periodontal treatment, overall management such as dental care is important, so management improves every three months. The patient has a growing interest in oral health, and complies with recalls.

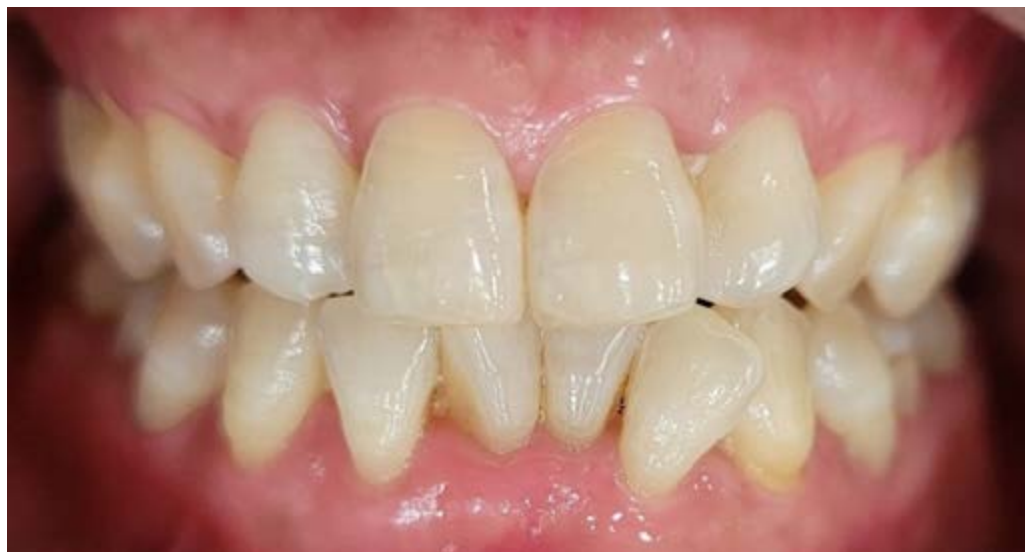PATIENT FEEDBACK

“I CAN SEE MY ORAL HEALTH IS GETTING BETTER. COMPARED TO OTHER TREATMENTS, GBT IS REALLY PAIN-FREE AND COMFORTABLE. THAT’S WHY I HAVE ENJOYED IT FOR YEARS NOW.”

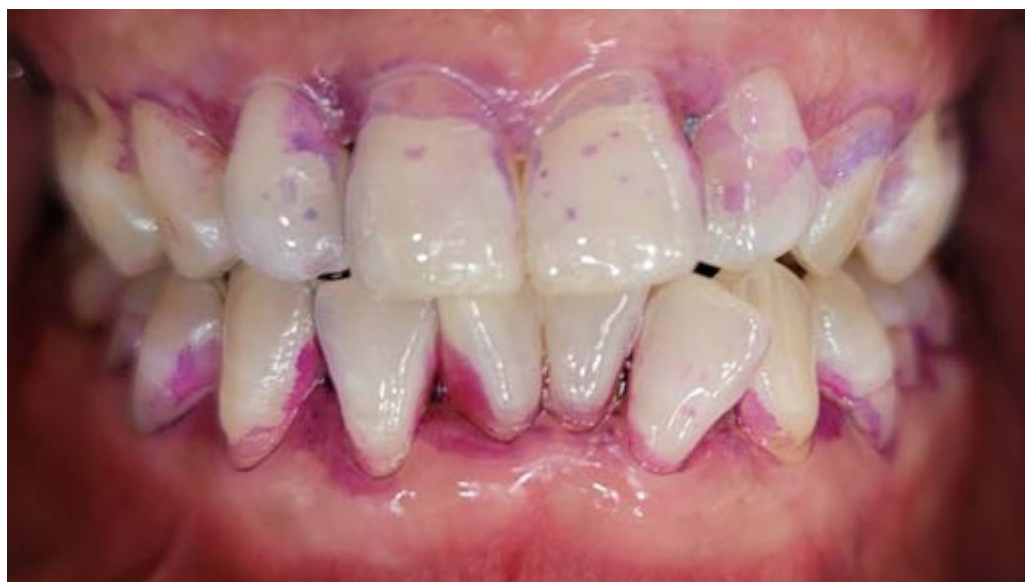& GBT



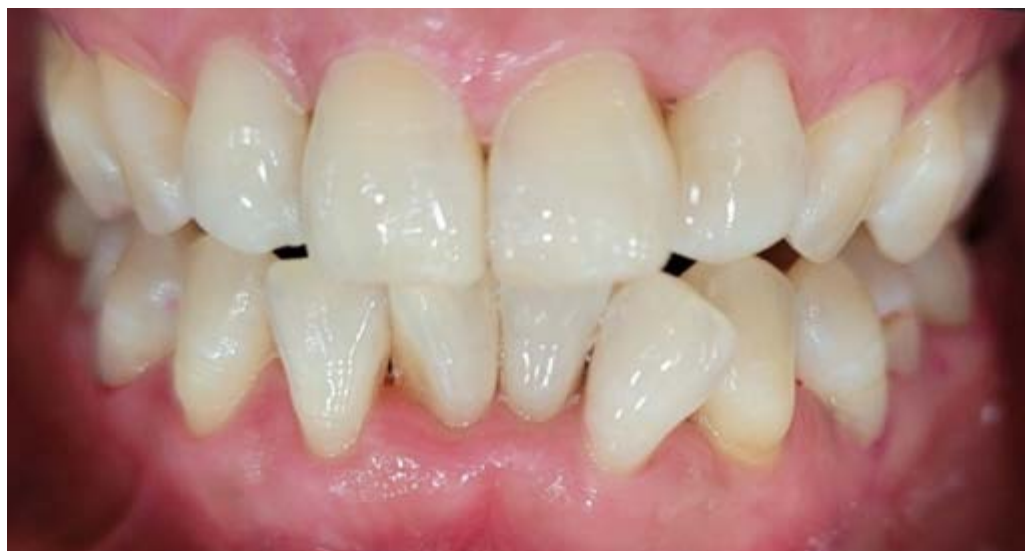BEFORE GBT



AFTER DISCLOSING



AFTER GBT



PERIODONTAL DEBRIDEMENT

CASE 97



CLINICIAN

Magdalena Gocol
Dental hygienist
Poland

PATIENT INFORMATION

- ▶ Age 46, male.

BACKGROUND INFORMATION

- ▶ Patient with periodontal disease. Patient has been smoking for the past 30 years, about 1 pack/day. Occlusal dysfunction. Last hygiene visit 10 years ago when only calculus was removed.

CLINICAL FINDINGS

- ▶ The patient shows numerous recessions and occlusal problems as well as occlusion overload. Visible attritions, non-carious enamel lesions. In the interview, the patient mentioned sensitivity in reaction to cold. The patient also complains of unpleasant smell from his mouth and bleeding while brushing. BOP 60% PI 98%.

TREATMENT

- ▶ Full GBT protocol was performed. The procedure was started by plaque disclosure. After disclosing, biofilm with AIRFLOW® PLUS Powder, then proceeded to remove hard deposits with a scaler, along with the cleaning of interdental spaces. AIR-FLOWING® was performed again in order to remove stain residues and to smooth out the tooth surface. After the procedure, the teeth were protected with a preparation with fluoride and hydroxyapatite and a chx rinse with colostrum was prescribed for 14 days.

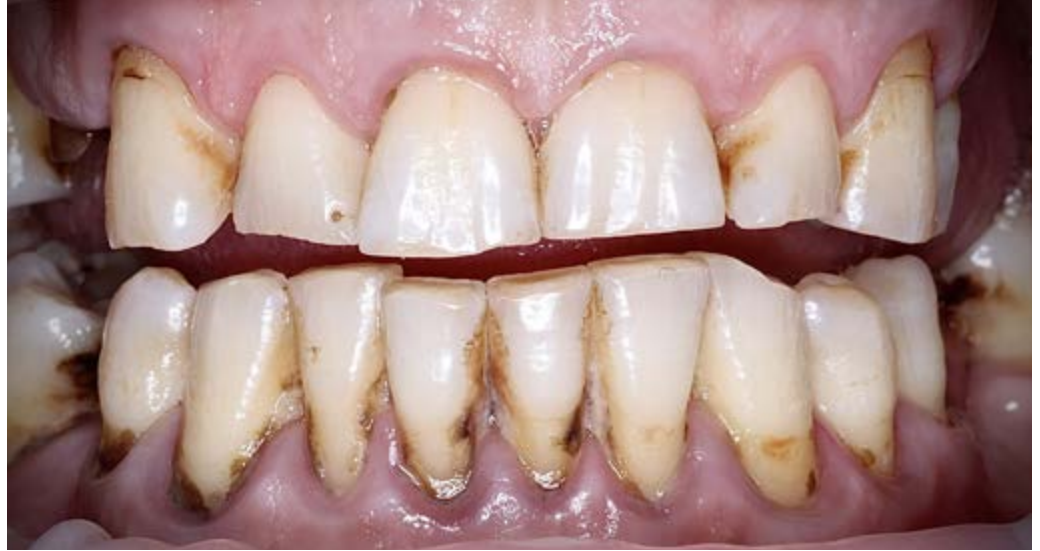PATIENT FEEDBACK

“I AM SURPRISED BY THE CONDITION OF MY ORAL CAVITY. I DID NOT THINK THAT A PROFESSIONAL HYGIENE TREATMENT COULD MAKE SUCH A DIFFERENCE. I FEEL THAT I HAVE GAINED NEW TEETH.”

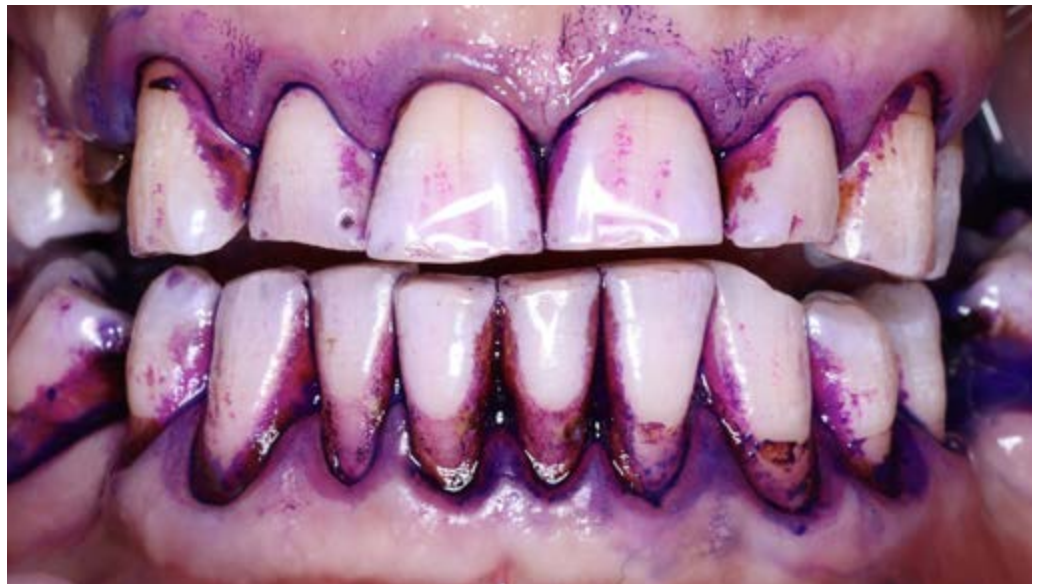& GBT



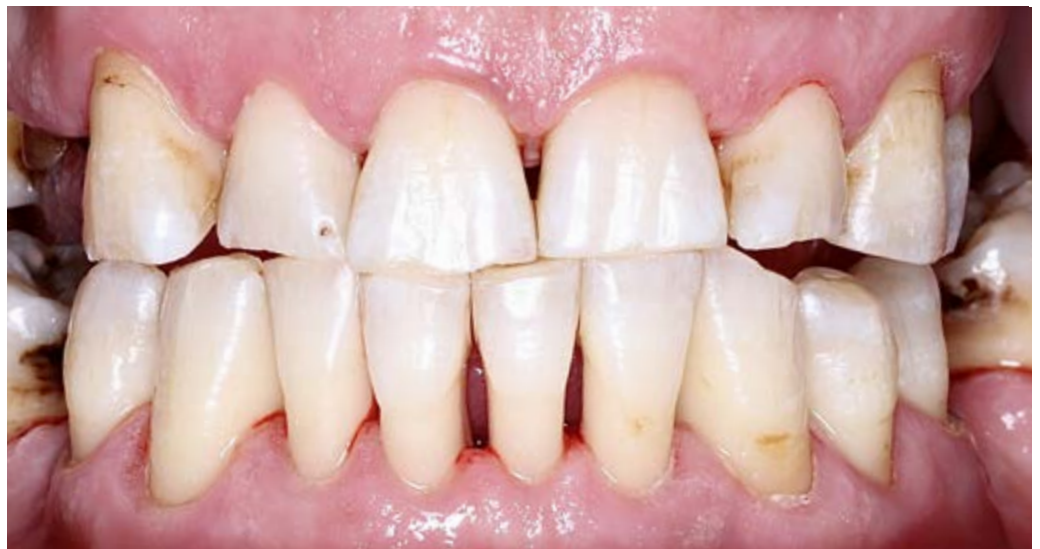BEFORE GBT



AFTER DISCLOSING



AFTER GBT



PERIODONTAL DEBRIDEMENT

CASE 98



CLINICIAN

Aleksandra Michalska
Dental hygienist
Poland

PATIENT INFORMATION

- ▶ Age 67, female.

BACKGROUND INFORMATION

- ▶ The patient underwent oncological treatment 5 years ago. She came to the dentist's office complaining of pain and bleeding around the teeth in the upper jaw. The patient has prosthetic restoration. Irregular professional hygiene treatments, last one - 3 years ago.

CLINICAL FINDINGS

- ▶ General inflammation, periodontal disease, bleeding on probing, presence of supragingival and subgingival calculus, teeth #13 and #21 are mobile.

TREATMENT

- ▶ Dental cleaning was performed based on the GBT protocol. The disclosed biofilm was removed with AIRFLOW® MAX and AIRFLOW® PLUS Powder. Hard supragingival and subgingival calculus was removed with PIEZON® PS Instrument. Oral hygiene instructions were carried out. The patient was advised to change to a manual brush with soft bristles and to use interdental brushes on a regular basis. A follow-up visit and 3-month recall visits were recommended.

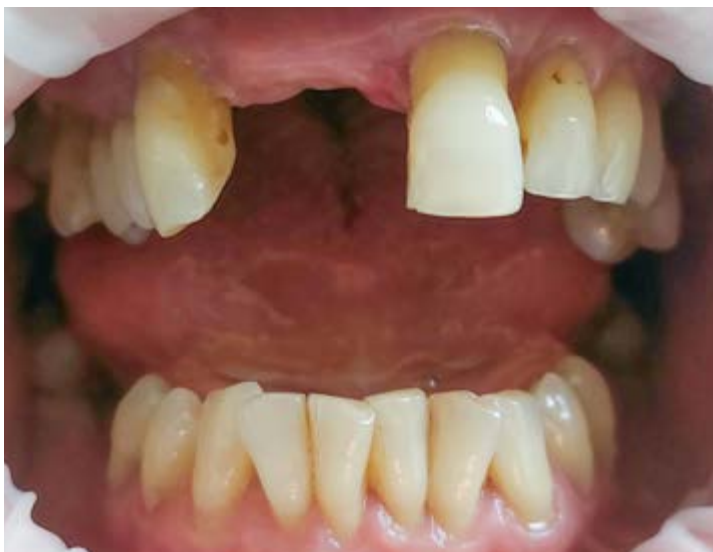PATIENT FEEDBACK

“EXTREMELY GENTLE AND PAINLESS. MUCH MORE COMFORTABLE COMPARED TO THE PREVIOUS TREATMENT. NO POWDER ON THE FACE AND CLOTHES. IT’S A REAL TOOTH SPA.”

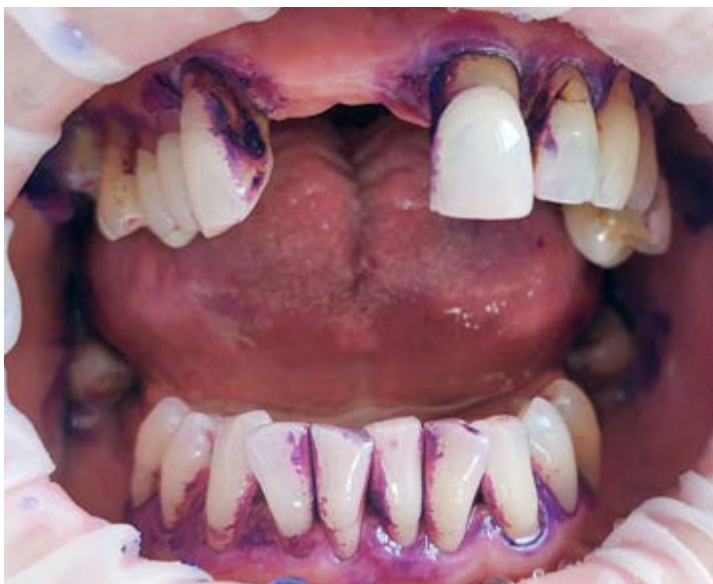& GBT



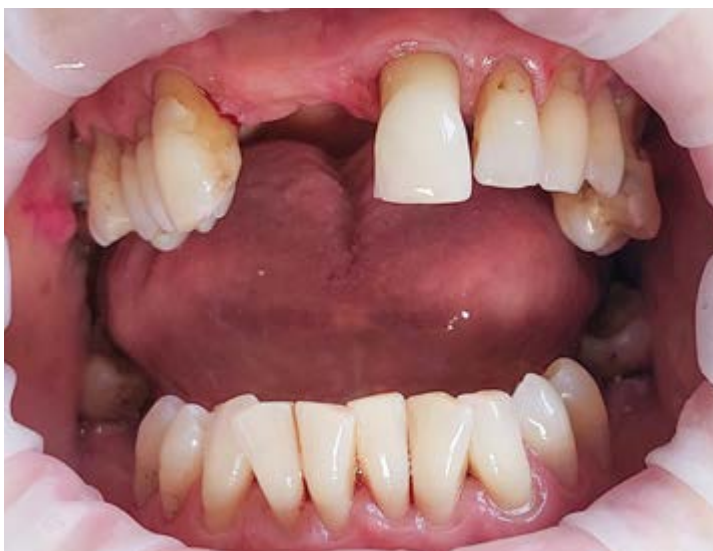BEFORE GBT



**AFTER
DISCLOSING**



AFTER GBT



PERIODONTAL DEBRIDEMENT

CASE 99



CLINICIAN

Nadine Strafela-Bastendorf
Dentist
Germany

PATIENT INFORMATION

- ▶ Age 36, male.

BACKGROUND INFORMATION

- ▶ Diet, oral hygiene status, level of motivation of the patient, relevant dental history. Patient came to the emergency consultation because tooth 25 had broken off. He has a normal diet without high sugar consumption (max. 4 sugar contacts per day), average bleeding index 100%. According to his medical history he cleans his teeth once a day with a manual toothbrush. Anxious, non-smoker, no general diseases.

CLINICAL FINDINGS

- ▶ Halitosis, mobility etc. Periodontitis stage IV, grade B. BOP +.

TREATMENT

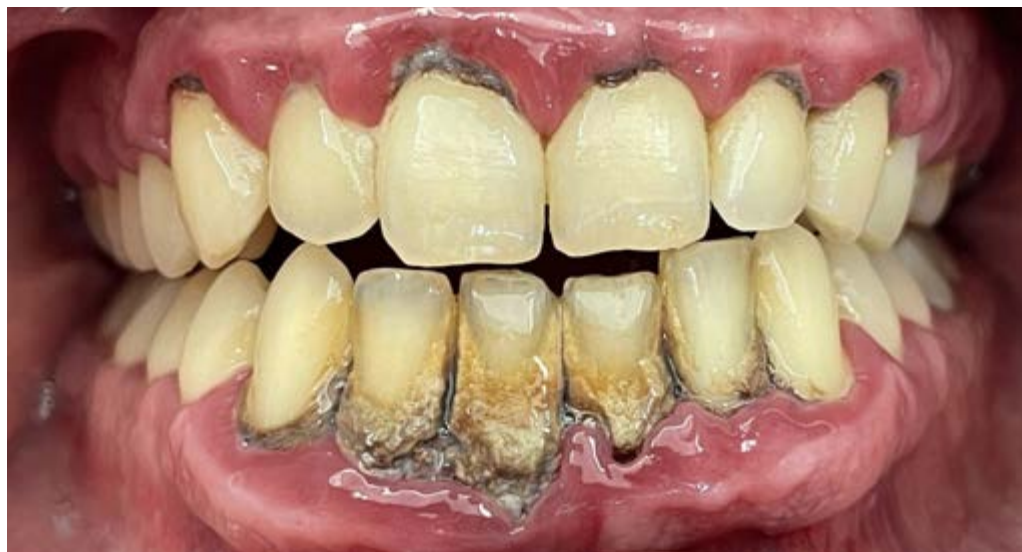- ▶ The entire treatment was done following the GBT protocol with AIRFLOW® PLUS Powder, PERIOFLOW® Nozzle and PIEZON® PS Instrument. Gingiva healed and healthy after 6 months.

PATIENT FEEDBACK

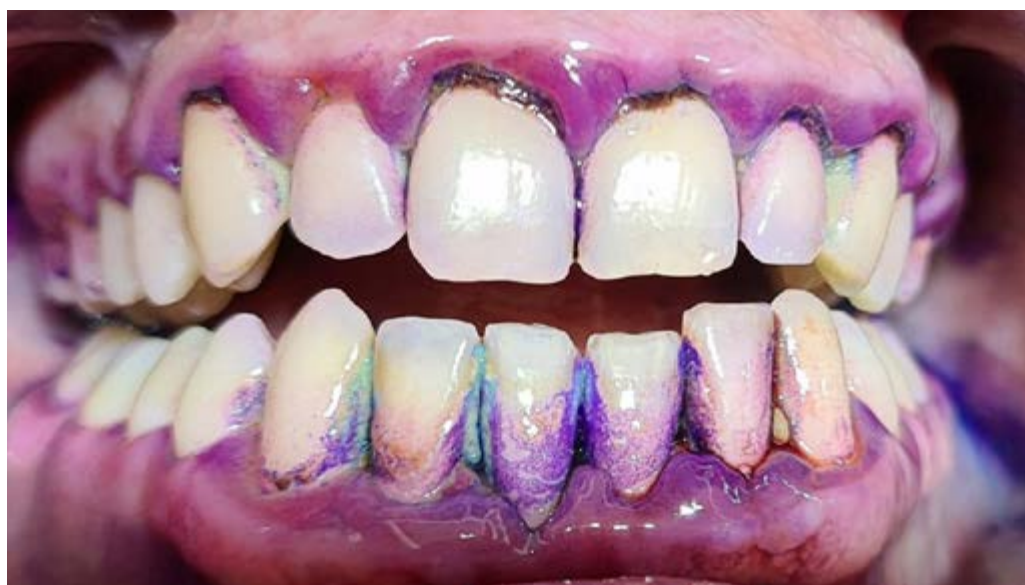“I`M VERY HAPPY. I FEEL LIKE A NEWBORN.”

& GBT

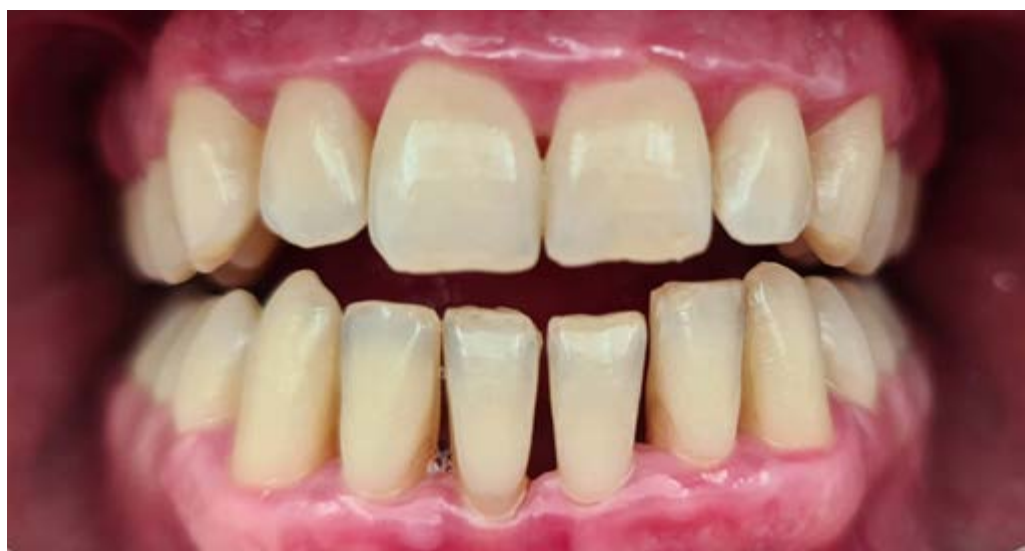BEFORE GBT



**AFTER
DISCLOSING**



**6-MONTH
RECALL**



PERIODONTAL DEBRIDEMENT

CASE 100



CLINICIAN

Matej Hropko,
Dental hygienist
Czech Republic

PATIENT INFORMATION

► Age 37, male.

BACKGROUND INFORMATION

► Patient used only regular toothbrush, (never used interdental brushes), no dietary restrictions, high level of stress from dental appointment. Was sent to dental hygienist by dentist. Sales assistant, never saw a dental hygienist. Believed he had no dental problems, thought that bleeding of gums is normal. Non-smoker.

CLINICAL FINDINGS

► BPI - 86, CPITN 222/232, periodontal pockets up to 4 mm. Calculus mostly in lower frontal teeth.

TREATMENT

► I treated patient with GBT protocol. In first appointment we removed most of calculus. We measured interdental brushes. In 6 weeks, I treated patient with GBT protocol and re-evaluated the size of interdental brushes. We also added single toothbrush for daily care routine. Second appointment results: PBI: 18, CPITN: 121/121, and periodontal pockets fell to 3 mm.

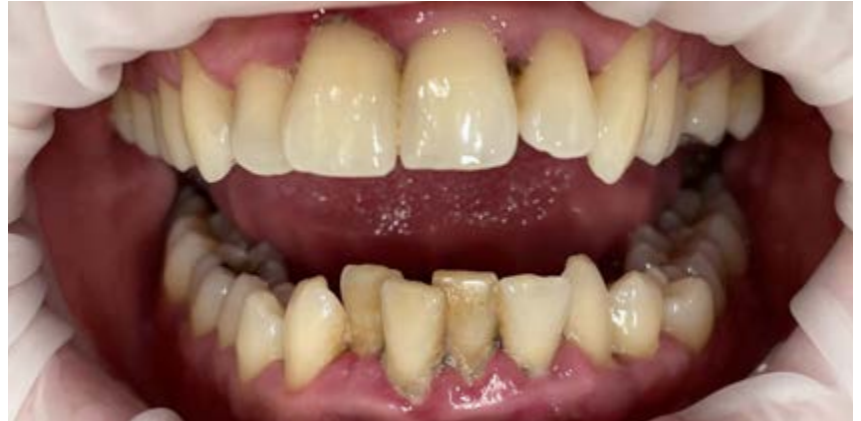PATIENT FEEDBACK

“I NEVER THOUGHT I WOULD FEEL THE SMOOTHNESS OF MY TEETH AGAIN.”

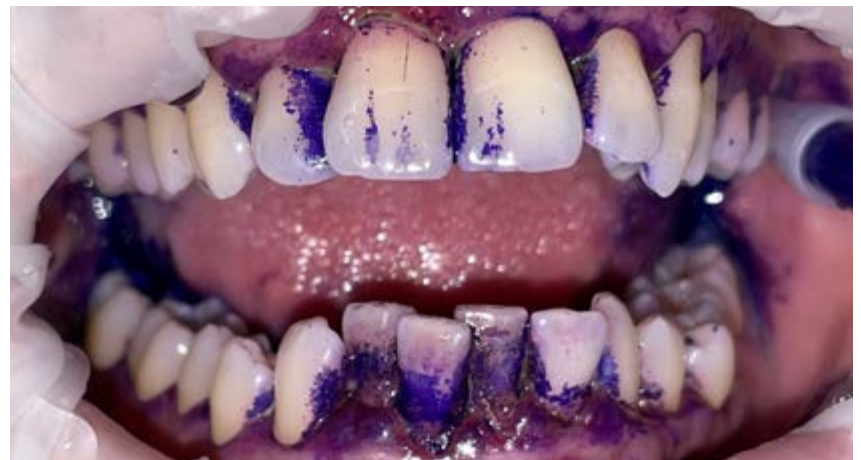& GBT



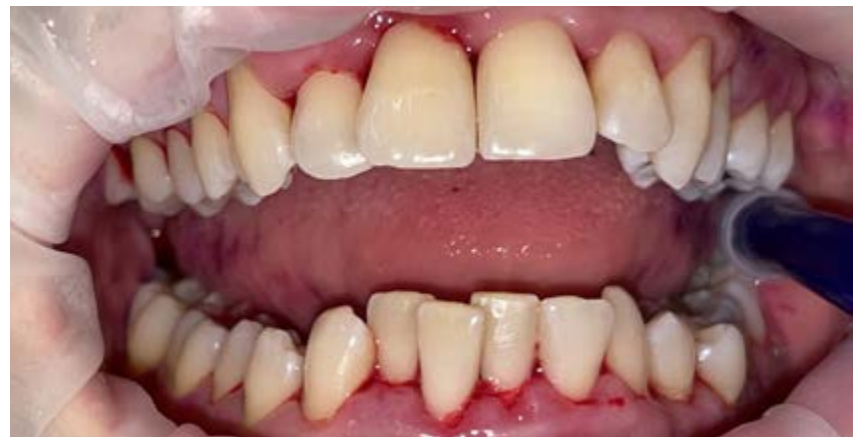BEFORE GBT



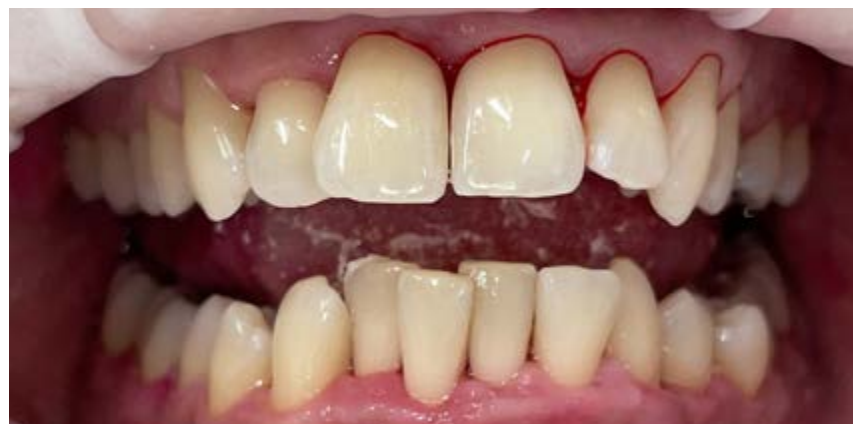AFTER DISCLOSING



AFTER GBT



**6-MONTH
RECALL**





**“I FEEL
GOOD”**

„The GBT Certification to me is a community. It’s a community where providers can share knowledge, where they are being continuously trained and making sure that we always follow the standardized protocol for the benefit of our patients. I am absolutely thrilled to be the first group of GBT-certified practices.“

- PATRICK SAASEN, CEO OF ADENT DENTAL CLINICS, FIRST GBT-CERTIFIED DENTAL CLINIC

Call your GBT Expert from EMS Tel. +41 22 99 44 700

CERTIFY YOUR PRACTICE

As a GBT Certified practice, become a part of an exclusive network of passionate dental professionals offering dental prophylaxis at the highest possible standards. Backed by the evidence-based GBT protocol, GBT Certified practices benefit from a wealth of exclusive services.



CERTIFIED PRACTICE



GAIN MORE VISIBILITY

- ▶ Your practice listed on the GBT Patient Finder, an interactive map allowing patients to find their nearest GBT practice



ACCESS TO THE GBT CERTIFIED MARKETING KIT

- ▶ Welcome kit to give your practice a GBT look
- ▶ Customizable GBT brand assets
- ▶ Social media templates
- ▶ 3D patient video



EXCLUSIVE EDUCATION PROGRAMS AND TRAINING

- ▶ Regular e-learning modules and webinars
- ▶ Continuing education and accreditation
- ▶ Training based on the latest scientific and clinical research
- ▶ On-demand training for new team members



PREMIUM CUSTOMER SERVICE

- ▶ First-line support for GBT Certified practices
- ▶ Preferential GBT service agreement



E.M.S.
Electro Medical Systems S.A.
Ch. de la Vuarpillière 31
1260 Nyon - Switzerland
+41229944700
EMS-DENTAL.COM

SDA 
SWISS DENTAL ACADEMY